



A Rare Case of Double Meckel's Diverticulum Presenting as Intestinal Obstruction

Vijay Shivpuje^{1*}, Abhishek Shahapurkar² and Nitant Vora³

¹Department of Surgery, Yashodhara Hospital, Solapur, Maharashtra, India.

²Sanjeevan Hospital, Osmanabad, Maharashtra, India.

³Department of Pathology, Yashodhara Superspeciality Hospital, Solapur, Maharashtra, India.

Authors' contributions

This work was carried out in collaboration among all authors. All authors read and approved the final manuscript.

Article Information

Editor(s):

(1) Prof. José Francisco de Sales Chagas, São Leopoldo Mandic Medical School, Brazil.

Reviewers:

(1) Md. Ashrarur Rahman, Dhaka Shishu (Children) Hospital, Bangladesh.

(2) Nicola Basso, Sapienza University of Rome, Italy.

Complete Peer review History: <http://www.sdiarticle4.com/review-history/70547>

Case Report

Received 20 April 2021

Accepted 26 June 2021

Published 30 June 2021

ABSTRACT

An eight-year-old girl presented to us with colicky abdominal pain, distention & bilious vomiting for a duration of 2 days. A contrast-enhanced computed tomography scan showed distal small bowel obstruction. Laparotomy revealed distal ileal obstruction due to a band arising from a Meckel's diverticulum. Another diverticulum was discovered 4 cm proximal to the previous one. The segment of ileum containing both diverticula resected & findings confirmed on histopathology. This was an exceptionally rare case of double Meckel's diverticulum presenting with acute intestinal obstruction, as no other case of double Meckel's diverticulum presenting similarly was reported in the literature.

Keywords: Double Meckel's diverticulum; intestinal obstruction.

1. INTRODUCTION

Meckel's diverticulum is a common congenital malformation of the gastrointestinal tract resulting from incomplete atrophy of the omphalo-

mesenteric duct. Most studies have reported an incidence of 0.6% to 4%. The median age of most cases when presented was 3.5 years [1]. Heterotopic tissues such as gastric, duodenal, colonic, and rarely pancreatic mucosa can be

*Corresponding author: E-mail: drshivpuje@gmail.com;

found in the diverticula, apart from the anatomically normal intestinal mucosa [1]. Preoperative diagnosis is difficult in most cases, as the diverticulum is usually observed incidentally during procedures for various reasons. "Rule of two's" is characteristic for Meckel's diverticulum, which includes the prevalence in 2% of the population; it is usually diagnosed under the age of 2; it is of 2-inches in size and 2 cm diameter, 2 feet proximal to the valve, twice frequent in men, and symptomatic in 2% of the patients. This case report aims to present a remarkably rare case of Double Meckel's diverticulum incidentally found in an eight-year-old girl with intestinal obstruction. In literature, only 5 cases of Double Meckel's are published with various presentations.

2. CASE REPRESENTATION

An eight-year-old girl presented to us with colicky abdominal pain, distention & bilious vomiting for a duration of 2 days. Her abdomen was distended with mild diffuse tenderness and hyperperistalsis. Contrast-enhanced computed tomography (CECT) scan showed distal small bowel obstruction (Fig.1a). After initial stabilization, she was taken up for exploratory laparotomy. Distal ileal obstruction was encountered due to a band arising from a

Meckel's diverticulum (Fig.1b). In addition, there was another diverticulum 4 cm proximal to it (Fig.1c). The segment of the ileum containing both diverticula resected (Fig.1d), followed by an end-to-end anastomosis. Her post-operative recovery was smooth & uneventful, and she was discharged on the 5th postoperative day. Histopathological examination of ileal segment showed double Meckel's with mixed heterotopic; pancreatic and gastric mucosa (Fig.2 a-d).

3. DISCUSSION

Meckel's diverticulum in the pediatric age group can present as obstruction, intussusception, gastrointestinal bleeding, diverticulitis, and perforation [2], most common being intestinal obstruction [1]. The incidence of Meckel's diverticulum causing intestinal obstruction was 3.7% of all etiologies [3]. Double Meckel's diverticulum is an extremely rare finding and was mentioned in the literature in 5 different case reports. Double Meckel's presented along with a patent vitellointestinal duct with discharging umbilical intestinal fistula in a 10-day old neonate, which was treated with uneventful surgery [4]. Another case presented in a 20-year-old with abdominal pain, nausea, vomiting, and signs of peritonitis in the right lower quadrant due to perforation of a Meckel's diverticulum with

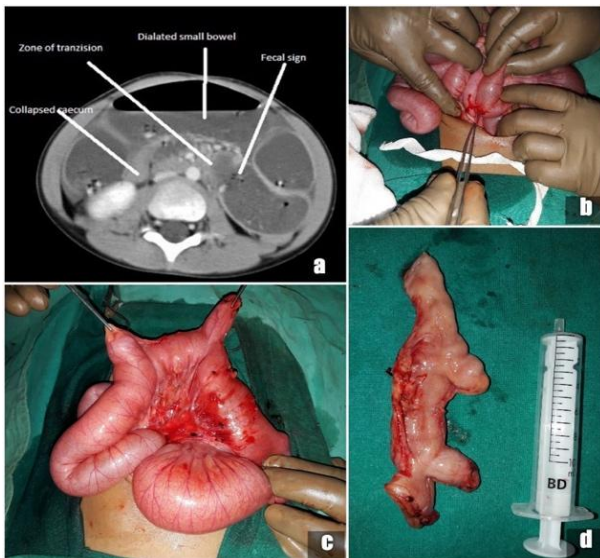


Fig. 1. a) CECT abdomen showing distal small bowel obstruction b) band arising from Meckel's causing obstruction c) demonstration of two diverticula d) resected specimen of ileum with two diverticula

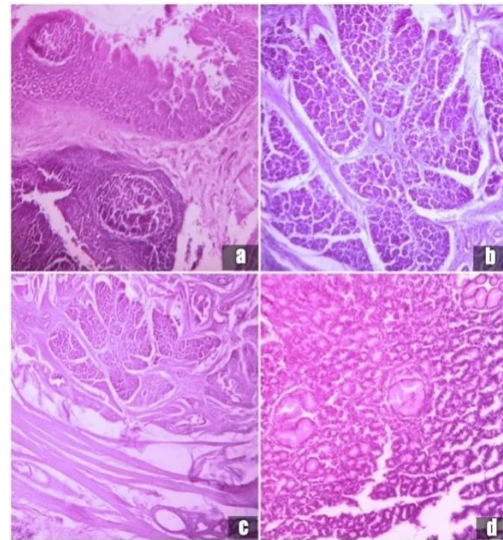


Fig. 2. a) Meckel's diverticulum lined by ileal epithelium along with lymphatic follicles b) & c) pancreatic acini in wall of diverticulum d) gastric mucosa in a background of ileal mucosa

another diverticulum adjacent to the first [5]. One of the cases presented as volvulus of the small bowel [6]. Double Meckel's diverticulum was incidentally found in a 25-year-old man, on a double-contrast enema done for the reason of gastrointestinal bleeding due to heterotopic gastric mucosa in the diverticulum, which was treated laparoscopically [7]. Double Meckel's was also incidentally found during laparotomy in a 20-year-old female with right lower quadrant pain, for a presumed diagnosis of acute appendicitis [8]. After a thorough review of the literature, we found no other reported case of double Meckel's presenting as acute intestinal obstruction due to band arising from Meckel's diverticulum.

Surgical excision is the gold standard treatment option in symptomatic patients. Diverticulectomy or segmental resections with anastomosis are the surgical options. We performed resection of the ileal segment containing both diverticula followed by an end-to-end anastomosis in our patient. In recent years laparoscopic surgery has been successfully used over gold standard open surgery with equivalent results & providing the advantage of minimal access.

4. CONCLUSION

Double Meckel's is a rare cause for acute abdominal catastrophe in the pediatric age group. In literature, very few cases of double Meckel's are reported, which are presented as perforation, hemorrhage, and volvulus. But no other case of double Meckel's diverticulum presented as Intestinal obstruction. Histopathological examination is helpful to confirm the diagnosis & rule out other pathologies.

CONSENT

As per international standard, parental written consent has been collected and preserved by the author(s).

ETHICAL APPROVAL

As per international standard or university standard written ethical approval has been collected and preserved by the author(s).

COMPETING INTERESTS

Authors have declared that no competing interests exist.

REFERENCES

1. Daniel Keese, Udo Rolle, Stefan Geroerer, et al. Symptomatic Meckel's Diverticulum in Pediatric Patients - Case Reports and Systematic Review of the Literature. *Front Pediatr.* 2019;7:267.
2. Huang CC, Lai MW, Hwang FM, Yeh YC, et al. Diverse presentations in pediatric Meckel's diverticulum: a review of 100 cases. *PediatrNeonatal.* 2014;55(5):369-75.
DOI: 10.1016/j.pedneo.2013.12.005. Epub 2014 Mar 28.
3. Gangopadhyay AN, Wardhan H. *Pediatr Surg Int.* 1989;4:84.
Available:https://doi.org/10.1007/BF00181839]
4. Avinash Joshi, Gurav PD. Double Meckel's Diverticulum: A Very Rare Anomaly. *International J. of Healthcare and Biomedical Research.* 2014;03(01):64-66.
5. Ilhan Tas, Serdar Culcu, YigitDuzkoylet al. A Rare Cause of Acute Abdomen: Perforation of Double Meckel's Diverticulum. *Case Reports in Gastrointestinal Medicine.* 2015;4.
Article ID 648417.
6. Albu E, Solomon L, Shah AK, et al. Double Meckel's diverticulum. *South Med J.* 1992; 85(11):1142-4.
7. Mazza L, Garino M, Morgando A, et al. A double Meckel's diverticulum as obscure gastrointestinal bleeding cause - Report of a case. *Minerva Gastroenterol Dietol.* 2006; 52(2):225-31.
8. Emre A, Akbulut S, Yilmaz M, et al. Double Meckel's diverticulum presenting as acute appendicitis: a case report and literature review. *J Emerg Med.* 2013;44(4):e321-4.
DOI: 10.1016/j.jemermed.2012.11.001. Epub 2013 Jan 20.