

Evaluation of the Hepatoprotective Potential of Methanol Extract of *Carica papaya* Linn. (*Caricaceae*) Ripe Fruit Peel against Carbon Tetrachloride (CCl₄) Induced Hepatotoxicity in Rats

Ubani, C. D. ^{a*}, Amah Akuma Kalu ^b, Chris Akunneh Wariso ^b and Ogwo, E. U. ^a

^a Department of Human Physiology, College of Medicine and Health Sciences, Abia State University Uturu Nigeria.

^b Department of Human Physiology, Faculty of Basic Medical Sciences, Imo State University Owerri, Nigeria.

Authors' contributions

This work was carried out in collaboration among all authors. All authors read and approved the final manuscript.

Article Information

Editor(s):

(1) Dr. S. Prabhu, Sri Venkateswara College of Engineering, India.

Reviewers:

(1) Asima Tayyeb, University of the Punjab, Pakistan.

(2) Devendra S. Shirode, Savitribai Phule Pune University, India.

Complete Peer review History, details of the editor(s), Reviewers and additional Reviewers are available here:

<https://www.sdiarticle5.com/review-history/78485>

Original Research Article

Received 08 October 2021

Accepted 11 December 2021

Published 19 December 2021

ABSTRACT

The aim of this study was to evaluate the hepatoprotective potential of methanol extract of ripe *Carica papaya* (pawpaw) fruit peel in adult male wistar rats. Six groups of adult male wistar rats of five rats per group were used for the study. Group 1 was the normal control; Group 2 was induced with liver damage without treatment; Group 3, 4 & 5 were treated with 200, 400 & 600 mg/kg b.w of extract respectively while Group 6 was administered with the standard drug for seven days after which treated groups were administered with CCl₄: liquid paraffin (1:1, 2 mL/kg body weight, s.c.). After 30 minutes of administration of the extract and silymarin, animals were sacrificed and blood samples were collected. Serum hepatomarkers and biomarkers of oxidative stress were evaluated using standard procedures. Administration of CCl₄ significantly (P<0.05), increased levels of serum hepatomarkers and malondialdehyde but decreased catalase activity. However, administration of the extract caused a dose dependent decrease in the levels of the serum hepatomarkers and

malondialdehyde levels. On the contrary, a dose dependent increase in catalase activity was observed. Qualitative phytochemical analysis performed on the sample, revealed the presence of tannins, saponins, flavonoids, steroids, phlobotanins terpenes and phenols. It can be deduced from this study that the peel of ripe *Carica papaya* (pawpaw) fruit could be an embodiment of compounds with hepatoprotective potential.

Keywords: Serum; catalase; antioxidant; oxidative stress.

1. INTRODUCTION

It is a well known fact that the liver is an important as well as the largest solid organ in the human body [1]. It is saddled with numerous metabolic responsibilities including metabolism of macromolecules, biotransformation of xenobiotics as well as regulation of blood volume among numerous other critical life supporting functions [2]. The liver is constantly being threatened by agents capable of inflicting injuries to it most of which cannot be avoided as they are integral components of the ecosystem [3]. This is evident by the fact that an estimated 50 million people suffer from one disease of the liver or the other globally [4].

Oxidative stress plays significant roles in the pathogenesis of hepatic damage being known for its role in the initiation and progression of liver damage. Treatment of human diseases with plant derived therapies has been an age long practice especially in Africa [5].

Pawpaw plant botanically known as *Carica papaya* Linn is a perennial, herbaceous plant with copious milky latex, broad leaves with large succulent fruits [6]. Various parts of the plant have been used as antihelmintic [7], anti-diabetic [8], and anti-cancer etc [9]. In spite of the much information that has been generated on the medicinal significance of this plant, paucity of information abounds on the hepatoprotective potential of the ripe pawpaw fruit peel. Thus, the aim of this work was to evaluate the hepatoprotective potential of methanol ripe fruit peel extract of *Carica papaya* Linn. (*Caricaceae*) in an experimentally induced hepatic damage.

2. METHODOLOGY

2.1 Collection and Processing of Ripe Pawpaw Peel

Ripe pawpaw fruits were harvested from a home garden. The fruits were transported to the Herbarium Unit of the Department of Forestry, Michael Okpara University of Agriculture,

Umudike Abia State, Nigeria for authentication.

2.2 Collection of Experimental Animals

Adult male wistar rats weighing 100-150 g were procured from the animal house of the Department of Science Laboratory Technology, Akanu Ibiam Federal Polytechnic, Unwana Afikpo North LGA, Ebonyi State Nigeria. The rats were housed in plastic cages and had unrestricted access to food and water for two weeks. Animal handling conformed to the International guidelines as prescribed by the Canadian Council on the care and use of Laboratory Animals in Biomedical Research [10].

2.3 Processing of Ripe Pawpaw Peel

Pawpaw fruits were thoroughly washed with tap water and allowed to dry at room temperature. Peels from the fruits were collected with the aid of a sharp clean knife and afterwards dried at room temperature before being ground to powder with the aid of an electric blender. The powdered leaf was sieved to obtain fine powder.

2.4 Extraction of Plant Materials

Exactly 50 g of the powdered plant sample was suspended in 1000 ml of methanol at room temperature for 72 hours and agitated thrice daily.

The extract was separated from the marc by filtration using Whatman No. 1 filter paper. Fresh methanol was added to the marc in the ratio of 1:2 and allowed to stand for 24 hours to ensure maximum extraction yield. The filtrates were then pooled together into an evaporating dish to obtain a dry crude extract [11].

2.5 Qualitative Phytochemical Analysis

2.5.1 Test for Tannins (Ferric chloride test)

Precisely 0.5 g of the extract was stirred in 10 ml of distilled water and afterwards filtered. Ferric

chloride was introduced to the filtrate. A blue black precipitate indicated that tannins are present [12].

2.5.2 Test for Alkaloids (Dragendorff's test)

Exactly 0.5 g of the extract was stirred in 5 ml of 1% HCl in a steam bath. This was followed by the addition of few drops of Mayer's reagent to 1ml of the filtrate. Turbidity of the solution indicated the presence of alkaloids in the extract [13].

2.5.3 Test for Saponins (frothing test)

A mixture of 0.5 g of extract and water was thoroughly shaken in a test tube. Frothing which persisted on warming was taken as evidence of the presence of saponin [14].

2.5.4 Test for Flavonoids (Pew's test)

Exactly 0.5 g of the extract was boiled in 2 ml of 5% methanol to which magnesium ribbon had been added after which 5 drops of concentrated HCl was introduced. Appearance of orange colour was indicative of the presence of flavonoids [15].

2.5.5 Test for Terpenes (Lieberman-Buchard's test)

The extract (0.5g) was boiled in ethanol, filtered and the filtrate dried. It was then dissolved in 2 ml of chloroform after which 1 ml of acetic anhydride was introduced. Gently, concentrated sulphuric acid was added until the solution formed two layers. The appearance of a blue top and red lower layers was showed the presence of terpenes [16].

2.5.6 Test for steroids (Acetic anhydride test)

One (1) ml of acetic anhydride was introduced into a tube containing a mixture of 0.5 g and 1ml of concentrated sulphuric acid. A colour change from violet to blue or green was an indication that steroids were present [16].

2.5.7 Test for Phlabotannins

Exactly 0.5 g of extract was boiled with distilled water and then filtered. The filtrate was further boiled with 1% aqueous HCl. The appearance of

a red precipitate showed the presence of phlabotannins [16].

2.5.8 Test for Phenols

Exactly 0.5 g of the crude extract was mixed with 2 ml of 2% solution of ferric chloride, a blue green coloration indicated the presence of phenols [16].

2.6 Acute Toxicity Test

Acute toxicity test was performed using OECD 425 according to Acute Oral Toxicity-Acute Toxic Class Method. Animals used in this experimental were non-pregnant female nulliparous wistar rats weighing 150-180 g. A limit test dose of 2000 mg/kg b.w was used as stipulated in OECD guidelines. The extract was dissolved in 10% DMSO (Dimethylsulfoxide) in phosphate buffer saline. Three rats for each step were dosed at intervals of 48 hours. The rats in the control group were administered 10% DMSO in phosphate buffer saline without only (OECD, 2001). The rats were observed individually for signs of acute toxicity and behavioral changes 1 h post-dosing and at least once daily for 14 days [17].

2.7 Experimental Design

Thirty five apparently healthy adult male wistar rats weighing (150-180 g) were divided into six groups of five rats per group. The various groups were treated thus: Group 1 (Normal Control) were administered with water (1 mL/kg, p.o.) daily for 7 days and received liquid paraffin (1 mL/kg, s.c.) on day 4 and 5. Group 2 (Negative Control) was administered with water (1 mL/kg body weight, p.o.) once daily for 7 days and received CCl₄: liquid paraffin (1:1, 2 mL/kg body weight, s.c.) on day 4 and 5 CCl₄ without treatment. Test groups animals (Groups III-V) were administered orally with 200, 400 and 600 mg/kg of the ripe pawpaw peel extract respectively, once daily. Group VI was administered with the standard drug silymarin (100 mg/kg, p.o.) once daily for 7 days. The Groups III-VI animals were administered with CCl₄: liquid paraffin (1:1, 2 mL/kg body weight, s.c.) on day 4 and 5 after 30 min of administration of the extract and silymarin. Animals were sacrificed 48 h after the last treatment. Blood was collected, allowed to clot and serum was separated at 2500xg for 15 min and biochemical investigations were carried out.

2.8 Preparation of Samples

The experiment lasted for three weeks, rats were sacrificed and blood samples collected in plain bottles and allowed to stand at room temperature for 30 minutes to clot after which the samples were centrifuged at 1500 x g for 10 minutes. The serum was transferred into a collecting tube. Liver was harvested immediately and 1 g of it was homogenized in 10 ml of normal saline and then centrifuged at 2,500 x g for 15 minutes to obtain the supernatant which was immediately used for biochemical analysis.

2.9 Oxidative Stress Studies

2.9.1 Determination of lipid peroxidation

To determine lipid peroxidation, the method of Buege and Aust [18] was employed. 1 ml of the sample was introduced into 2 ml of mixture of 0.37 % Thioarbituric acid (TBA), 15 % TCA and 0.24 N Hydrochloric acid (HCl) (1:1:1 ratio). The tube was stoppered loosely and immersed in boiling water for 15 minutes and swirled slightly at intervals. The mixture was cooled and centrifuged for 10 minutes at 5000 xg. The

absorbance was read at 532 nm using the reagent blank. Results were expressed as nmol/mg of protein.

2.10 Determination of Antioxidants Enzymes

2.10.1 Determination of catalase activity

Exactly 2 ml of H₂O₂ was added to 1 ml of sample in the reaction cuvette. Absorbance was read at 360 nm for 70 seconds. The reference cuvette contained 2 ml H₂O₂ and 1 ml of water. The disappearance of hydrogen peroxide was calculated using the Molar extinction coefficient, $\epsilon = 39.4 \text{ M}^{-1}\text{cm}^{-1}$ Kaplan et al. [19]. The results were expressed as UCAT/mg protein [20].

2.10.2 Liver function test

Using the serum sample generated, Alanine Aminotransferase (ALT), Aspartate Aminotransferase (AST), Alkaline Phosphatase (ALP), conjugated bilirubin (CBIL), total bilirubin (TBIL) were determined with the aid of the Randox diagnostic kits.

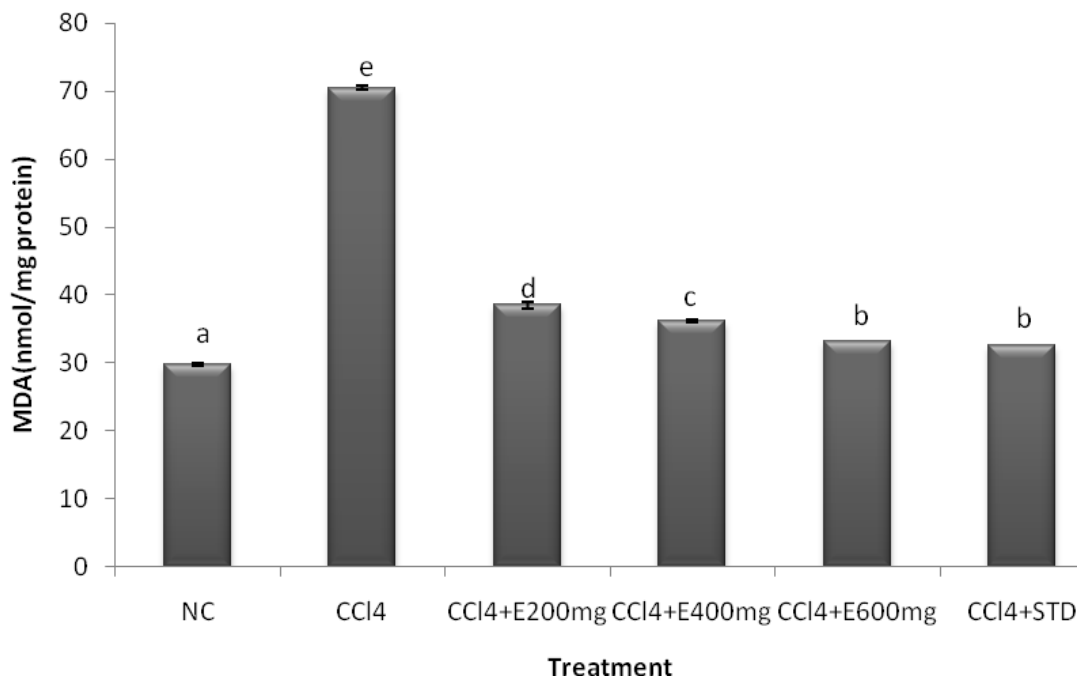


Fig. 1. Effect of treatment with methanol extract of ripe *Carica papaya* ripe fruit peel on the malondialdehyde levels in rats with CCl₄ induced liver damage

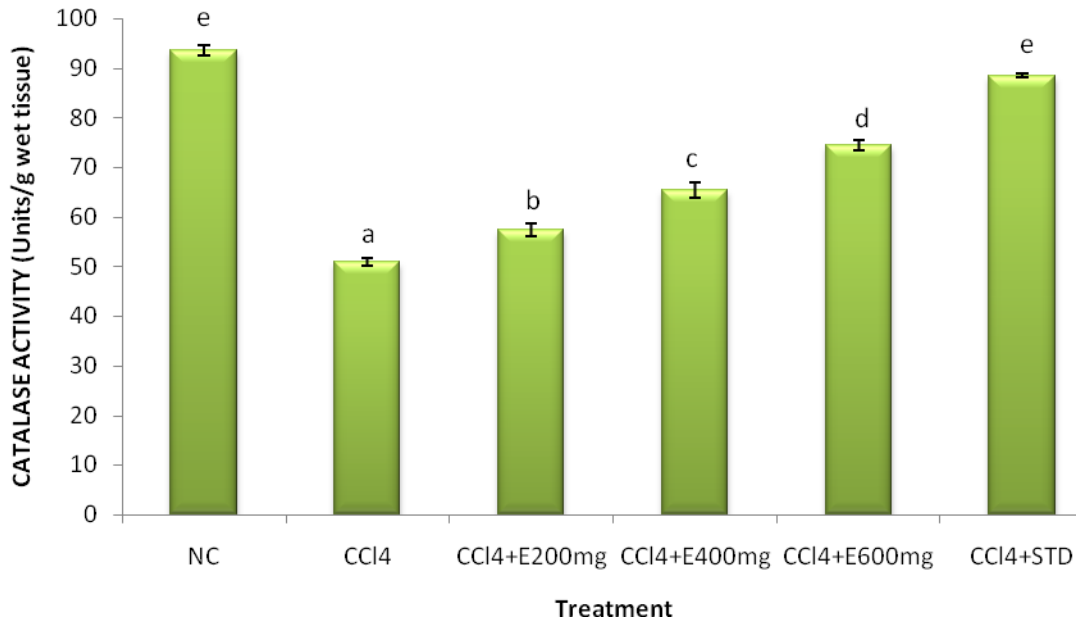


Fig. 2. Effect of treatment with methanol extract of *Carica papaya* ripe fruit peel on the catalase activity in rats with CCl₄ induced liver damage

Table 1. Qualitative phytochemical analysis on ripe pawpaw *Carica papaya* fruit peel

Phytochemicals	Remarks
Tannins	+
Saponins	+
Flavonoids	+
Terpenes	+
Steroids	+
Phenols	+
phlabotannins	+

Table 2. Liver enzyme activity of wistar rats examined for the hepatoprotective effect of methanol extract of *Carica papaya* ripe fruit peel

Animal Grouping	ALT (Iu/L)	AST (Iu/L)	ALP (Iu/L)	CB (mmol/l)
Group 1: Normal rat	18.31±0.12 ^a	17.86±0.87 ^a	14.21±0.50 ^a	5.60±1.20 ^a
Group 2: CCl ₄ only	44.21±0.21 ^d	38.12±2.03 ^d	35.10±0.14 ^d	12.30±0.11 ^c
Group RCPP _{200mg/kg}	32.35±0.37 ^c	28.08±0.65 ^c	29.12±0.01 ^c	9.10±0.12 ^b
Group 4: RCPP _{400mg/kg}	23.76±0.71 ^b	27.60±0.37 ^c	29.20±0.84 ^c	8.56±0.11 ^b
Group 5: RCPP _{600mg/kg}	19.56±0.32 ^{ab}	19.03±0.55 ^b	16.23±0.01 ^b	6.92±0.42 ^{ab}
Group 6: STD _{100mg/kg(iv)}	17.28±2.32 ^a	18.31±0.32 ^{ab}	15.71±0.11 ^{ab}	6.72±0.10 ^{ab}

Values are means ± SD of five determinations. Values with different superscript in a row are significantly different (P<0.05)

2.11 Statistical Analysis

Data analysis was performed using SPSS (Version 23). Results were expressed as Means ± SD. The data were analyzed using the analysis of variance (ANOVA). The differences in mean were compared using Duncan Multiple Range

Test. P < 0.05 was considered statistically significant.

3. RESULTS AND DISCUSSION

Various parts of *Carica papaya* have been used in the Nigerian trado-medical practices for the

treatment of diverse human diseases. The liver is critical to metabolic activities, it is basically concerned with the biotransformation of substances alien to the body into non-toxic or more toxic components than the original substance [21]. Liver damage was established in groups 2-6. However, groups 3-5 were treated with 200, 400 and 600 mg/kg b.w of methanol extract of ripe *Carica papaya* fruit peel respectively. Administration of CCl₄ significantly (P<0.05) increased the activity of aspartate amino transferase (AST), alkaline phosphatase (ALP), Conjugated bilirubin (CB). However, administration of methanol extract of ripe *Carica papaya* fruit peel significantly reduced their activities in a dose dependent manner. The reduced levels of serum liver enzymes in CCl₄-induced liver damage by the extract may be attributed to the modulatory effects of phenol and flavonoids against lipid peroxidation which consequently, translates to a preserved integrity of the cell membrane. This is consistent with the fact that serum levels of transaminases return to normal with the healing of hepatic parenchyma and the regeneration of hepatocytes [21]. Fig. 1 shows the effect of treatment with methanol extract of ripe *Carica papaya* fruit peel. CCl₄ administration caused lipid administration in rats. However, administration of methanol extract *Carica papaya* fruit peel caused a significant (P<0.05) dose dependent reduction in malondialdehyde levels. Similar trend but in a reverse order was observed for catalase activity (Fig. 2). Owing to the fact that studies have shown that decreasing the metabolic activation of carbon tetrachloride, prevention of generation of reactive oxygen species and scavenging of generated free radicals or by combination of these are important mechanisms in the protection against CCl₄ induced hepatic lesion Yutin et al. [22]. Thus, based on the outcome of this research, the extract may have exert its hepato-protective activity either by decreasing the metabolic activation of carbon tetrachloride, or by acting as a chain-breaking antioxidant for scavenging free radicals or by a synergistic combination of these effects. This consistent with the finding of Mohammed et al [23] which established that aqueous leaf extract of *Carica papaya* significantly (P<0.05) reduced MDA levels in a dose dependent manner in rats induced with hepatic damage.

4. CONCLUSION

Through this work, it can be deduced that the peel of ripe *Carica papaya* (pawpaw) fruit could

be an embodiment of compounds with hepatoprotective potential and thus should be probed for the presence of such compound(s).

DISCLAIMER

The products used for this research are commonly and predominantly products used in our area of research and country. There is absolutely no conflict of interest between the authors and producers of the products because we do not intend to use these products as an avenue for any litigation but for the advancement of knowledge. Also, the research was not funded by the producing company rather it was funded by personal efforts of the authors.

ETHICAL APPROVAL

It is not applicable.

COMPETING INTERESTS

Authors have declared that no competing interests exist.

REFERENCES

- Schuppan D, Nezam A. Liver cirrhosis. *Lancet*. 2008;307:838-851.
- Bruha R, Dvorak K, Petrty J. Alcoholic liver disease. *World Journal of Hepatology*. 4:81-90.
- Slater TF. Free-radical mechanisms in tissue injury. *Biochemistry Journal* 1984; 222:1-15.
- Karunamoorthi K, Jegajeevanram K, Vijayalakshmi J. Traditional medicinal plants: a source of phytotherapeutic modality in resource-constrained health care settings. *Journal of Evidence Based Complementary Alternative Medicine*. 2013;18:67-74.
- Chay-Prove P, Ross P, Hare PO, Macleod N, Kernot I, Evans D, Agrilink Series: Your Growing Guide to Better Farming. Nambour, Queensland: Queensland Horticulture Institute. 2000;20-7.
- Oduola T, Adeniyi AA, Ogunyemi EO, Bello IS, Idowu TO. Anti-sickling agent in an extract of unripe pawpaw (*Carica papaya* L.): Is it real? *African Journal Biotechnology*. 2006;5:1947-9.
- Gill LS, *Carica papaya* L. In: *Ethnomedical Uses of Plants in Nigeria*, Uniben Press, Benin-City Nigeria. 1992;155.
- Olagunju JA, Adeneye AA, Fagbonyinka BS, Bisoga NA, Okekitu AO, Benebo AS,

- Nephroprotective activities of aqueous seed extracts of *Carica papaya* L. in carbon tetrachloride injury in Wistar rats: A dose dependent study. *Biology Medicine*. 2009; 1:11-9.
9. Otsuki N, Dang NH, Kumagai E, Kondo A, Iwata S, Morimoto C. Aqueous extract of *Carica papaya* Leaves exhibits anti-tumor activity and immunomodulatory effects. *Journal of Ethnopharmacology*. 2009;127: 760-7.
 10. Canadian Council of Animal Care. Guide to the Handling and Use of Experimental Animals. Ottawa, Canada. 1984;2.
 11. Phrompittayarat W, Putalun W, Tanaka H, Jetiyanon K, Wittaya-areekul S, Ingkaninan K. "Comparison of various extraction methods of *Bacopa monnieri*" Naresuan University Journal, 2007;15:29-34.
 12. Lorke D. A New Approach to Practical Acute Toxicity Testing. *Archives of Toxicology*. 1983;54: 275-87.
 13. Trease GE, Evans WC. *Pharmacognosy*(11th ed.) Bailliere: Tindall and Macmillan Publishers. 1989;320–322.
 14. Harborne JB. *Phytochemical Methods*. A guide to modern techniques of plants analysis. London: Chapman and Hall. 1973; 279.
 15. Wall ME, Eddy CR, McClenna ML, Klump ME. Detection and estimation of steroid saponin in plant tissues. *Analytical Chemistry*. 1952;24:1337.
 16. Sofowara A. Medical plants and traditional medicine in Africa (2nd ed.) Sun Shine House Ibadan, Nigeria: Spectrum Books Ltd. Screening plants for Bioactive agents. 1993;134-156
 17. Evans WC. Trease and Evans Pharmacognosy, (15th Edition W.B Saunders, London. 2000;3-4:488-491.
 18. Kaplan A, Dembiec A, Cohen A, Marcus A. Measurement of catalase activity in tissue extracts. *Analytical Biochemistry* 1972;34: 30-38.
 19. Aebi H. Catalase *In vitro* Method. *Enzymology*. 1984;105:121-126.
 20. Loch JM, Potter J, Bachman KA. The influence of anesthetic agents on rat hepatic cytochromes P450 in vivo. *International Journal of Experimental Clinical Pharmacology*. 1984;50:146-153.
 21. Yutin C, Rongliang Z, Zhongjian J, Yong J. Flavonoids as superoxide scavengers and antioxidants. *Journal of Free Radicals Biology and Medicine*. 1990;9:19-23.
 22. Thabrew M, Joice P. A comparative study of the efficacy of *Pavetta indica* and *Osbeckia octanda* in the treatment of liver dysfunction. *Planta Medica*. 1987;53:239-241.
 23. Mohammed A, Abubakar S, Sule MS. Hepatoprotective effect of aqueous leaf Extract of *Carica papaya* Linn. against CCl₄-Induced Hepatic damage in rats. *International Journal of Pharmaceutical Sciences Review and Research*. 2011;11: 13-15.

© 2021 Ubani et al.; This is an Open Access article distributed under the terms of the Creative Commons Attribution License (<http://creativecommons.org/licenses/by/4.0>), which permits unrestricted use, distribution, and reproduction in any medium, provided the original work is properly cited.

Peer-review history:

The peer review history for this paper can be accessed here:
<https://www.sdiarticle5.com/review-history/78485>