

## **Hydatid Cyst of the Interventricular Septum Case Report and Literature Review**

**S. Zenouaki <sup>a\*</sup>, M. Njie <sup>b</sup>, H. Choukrani <sup>b</sup>, A. Med Reda Altimmi <sup>b</sup>  
and R. Habbal <sup>a,b</sup>**

<sup>a</sup> Faculty of Medicine and Pharmacy, Hassan II University of Casablanca, Casablanca, Morocco.

<sup>b</sup> Department of cardiology P37, Ibn Rochd University Hospital, Casablanca, Morocco.

### **Authors' contributions**

*This work was carried out in collaboration among all authors. All authors read and approved the final manuscript.*

### **Article Information**

#### **Open Peer Review History:**

This journal follows the Advanced Open Peer Review policy. Identity of the Reviewers, Editor(s) and additional Reviewers, peer review comments, different versions of the manuscript, comments of the editors, etc are available here: <https://www.sdiarticle5.com/review-history/84820>

**Case Study**

**Received 20 January 2022**

**Accepted 29 March 2022**

**Published 30 March 2022**

### **ABSTRACT**

Hydatidosis is a frequent pathology which is still endemic in the kingdom of Morocco. Cardiac localization of hydatid cysts is rare representing 0.5 to 2% of all clinical forms of this condition. Hydatid cysts are usually observed in the left ventricle whilst interventricular septum localization is exceptional. The principal diagnostic and preoperative investigations are serology, imaging by transthoracic echocardiography and computed tomography. The authors report a case of hydatid cyst of the interventricular septum in which transthoracic echocardiography (the key investigation in all cases of hydatid cyst) computed tomography and nuclear magnetic resonance imaging (MRI) was contributive to the diagnosis. Computerized tomography scan (CT-scan) investigation also aided in the diagnosis of secondary localization of the hydatid cyst especially in the lungs and brain tissues. Diagnostic or therapeutic delay can lead to severe and even fatal complications.

**Keywords:** *Hydatid cyst; interventricular septum; echocardiography; hydatidosis.*

### **ABBREVIATION**

**AV-BLOC** : *Atrio-ventricular bloc*

**CT-SCAN** : *Computerized Tomography Scan*

\*Corresponding author

ECG : Electrocardiogram  
ELISA : Enzyme Linked Immuno Sorbent Assay  
LV : Left Ventricle  
LVH : Left Ventricular Hypertrophy  
LV/RV : Left ventricular/ Right ventricle  
MRI : Magnetic Resonance Imaging  
TAP CT scan : Thoraco-abdomino-pelvic CT scan

## 1. INTRODUCTION

Hydatidosis is a frequent pathology which is still endemic in the kingdom of Morocco [1]. Cardiac localization of hydatid cysts is rare (0.5% to 2%). The revealing symptomatology is unspecific. The most frequent cardiac localizations are the free wall of the left ventricle (LV) and the septum. The auricles can also be affected. Diagnostic or therapeutic delay can lead to severe and even fatal complications [2,3,4].

Only few series of cardiac hydatid disease and primary hydatid disease of the pericardium have been published in the literature. We report a case of hydatid cyst of the interventricular septum revealed by an intracardiac mass.

## 2. CASE REPORT

We report the case of a 32-year-old young man of rural origin admitted for exploration of NYHA stage II dyspnea accompanied by palpitation and atypical chest pain, occurring especially on low intensity effort.

The patient has a history of epilepsy since the young age of 10 years under medical treatment with prescribed drugs like tegretol 40mg per day

and gardenal 50mg per day. He is also diagnosed hypertension with a likely nephropathy origin under dual therapy based on amlodipine 10mg and indapamide 2, 5mg per day.

The somatic examination is without abnormalities. The electrocardiogram (ECG) showed electrical left ventricular hypertrophy (LVH) with apico-lateral biphasic T wave repolarization disorder (Fig. 1). The chest X-ray reveals a round left para-cardiac opacity at the level of the lower lobe of the lung on the same side.

Transthoracic echocardiography showed a cystic-like oval formation located in the interventricular septum wall (IVS) measuring 30mm x 15mm with border edges protruding into the right ventricular cavity with no other signs of cardiac involvement (Fig. 3).

Biological assessment showed hypereosinophilia without any other anomaly.

Based on the rural origin of the patient, radiology and echocardiographic findings, hydatid cyst of the heart is suspected whereby a hydatid serology by ELISA carried out proved positive.

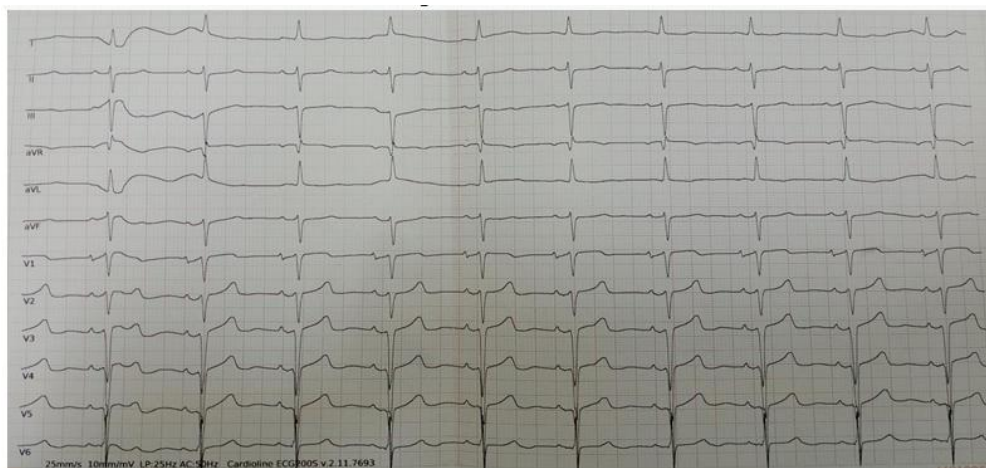
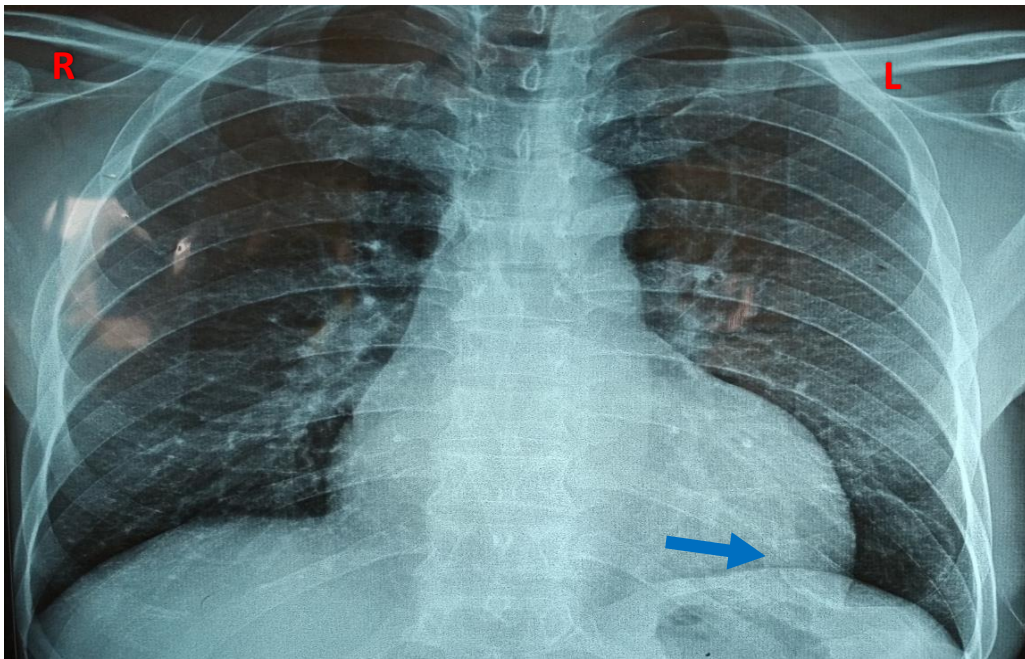
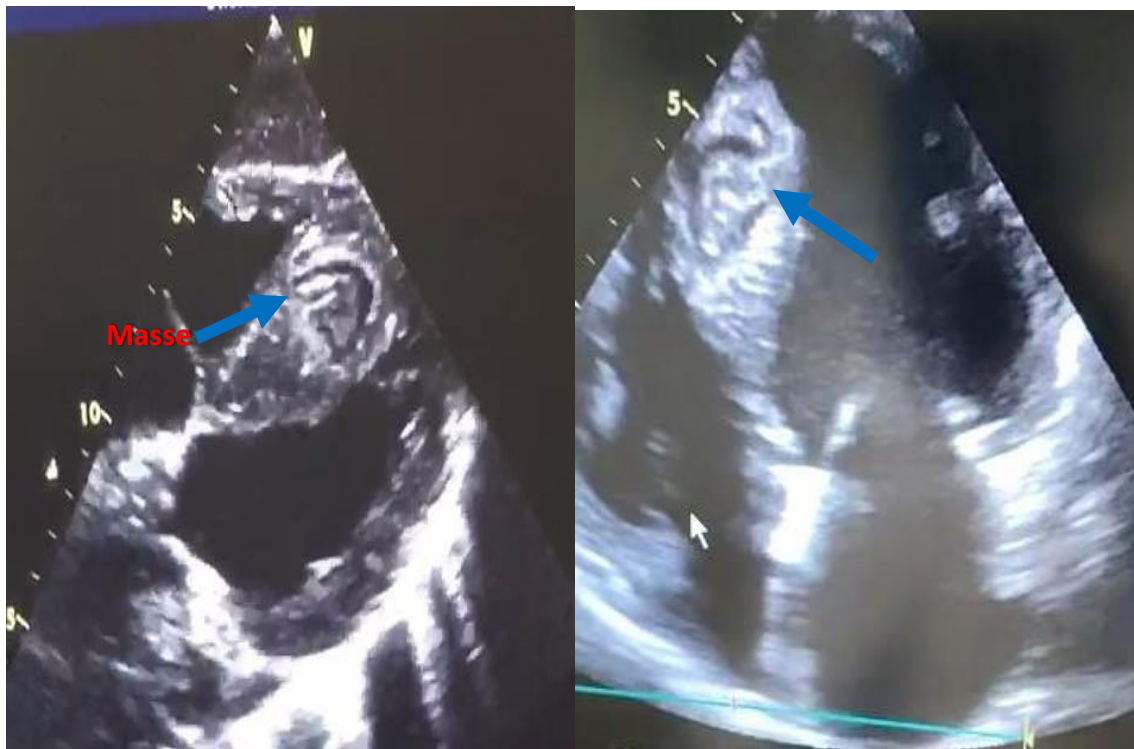


Fig. 1. Electrocardiogram: Sinus rhythm: electrical LVH and biphasic T waves in the apico-lateral region



**Fig. 2. Chest X-ray ; Frontal view: limited round opacity localized at the lower lobe of the left lung without filling of the left costo-diaphragmatic cul-de-sac or parenchymal abnormality (arrow)**



**Fig. 3. Transthoracic echocardiography: A- long-axis parasternal view: Presence of a cystic formation in the IVS wall measuring 30mm x 15mm (arrow) with borderline edges. B- 4 chambers view: shows the same mass protruding into the ventricular chamber**

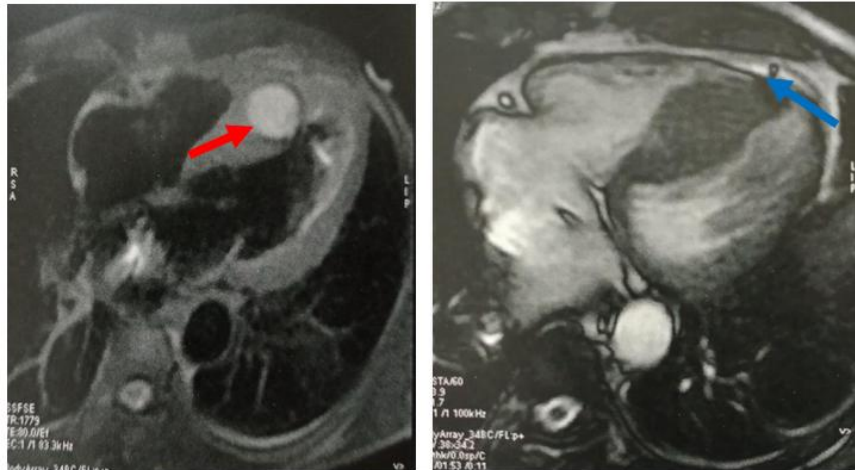


Fig. 4. Cardiac MRI, transversal cross-section: Cystic mass with fibrous capsule of the IVS measuring 50mm x 30mm (red arrow) with an effusion blade next to the inferior wall of the LV/RV (blue arrow)

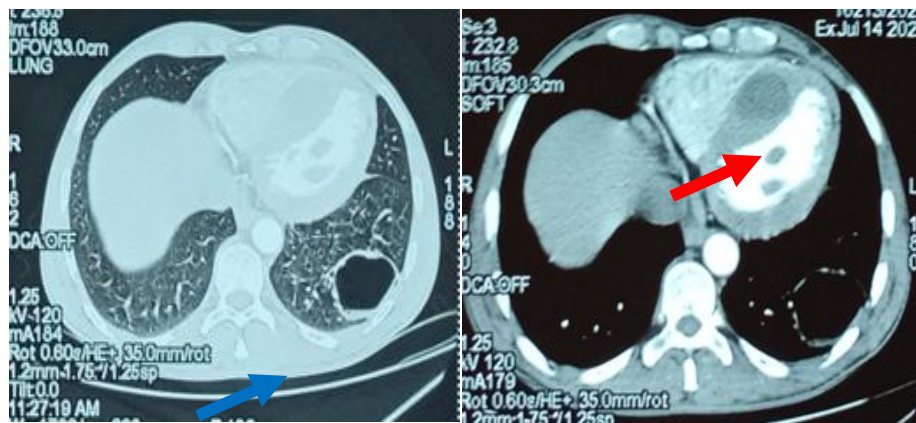


Fig. 5. TAP CT scan at the thoracic level: Cross section passing through C5: A-Parenchymal window: Stage I simple right cyst of the lower lobe of the left lung (Blue arrow). B- Bone window: Cystic lesion of the interventricular septum (red arrow)

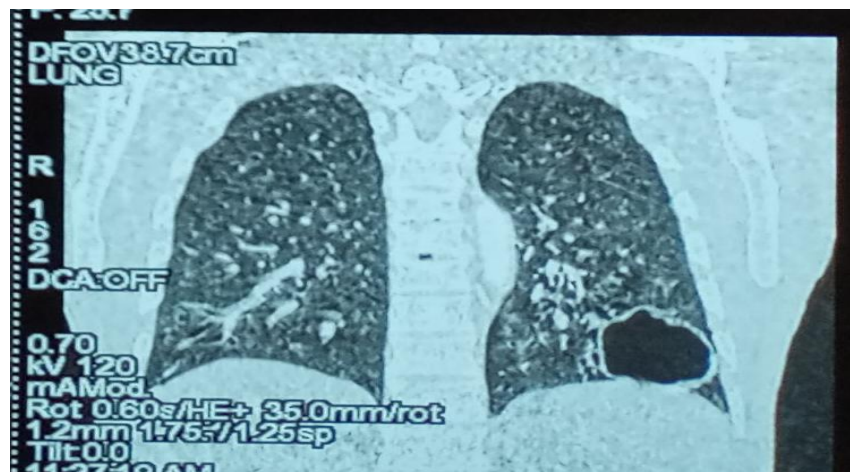


Fig. 6. TAP CT scan at the thoracic level: Longitudinal section: Simple hydatid cyst Stage I of the lower lobe of the left lung (arrow)

The radiology findings of multiple localizations of hydatid cyst were then completed by a cardiac MRI which concluded a cystic mass with a fibrous capsule of the interventricular septum measuring 50mm x 30mm, of hydatid origin without intra-LV obstruction. This mass does not enhance in the late phase and is not vascularized in the arterial phase. Absence of extracardiac anomaly apart from a 3 mm pericardial effusion blade opposite the lower wall of the LV/RV (Fig. 4).

An assessment of extension of the cystic disease including extracardiac assessment by cerebral and thoraco-abdomino-pelvic CT scan (TAP CT scan) revealed 4 cerebral parenchymal formations largely calcified and hypodense with annular enhancement related to hydatid cysts. CT scan showed left lung lesions of hydatid origin (Figs. 5 and 6), left renal hypodense patch on chronic pyelonephritic kidney and small aspect of the left renal artery.

The patient was refused surgery due to a poor prognosis of his general condition, who died after hemodynamic complications by anaphylactic shock one month after the diagnosis was confirmed despite the isolated oral medical treatment by albendazole at a dose of 15mg/kg/day.

### 3. DISCUSSION

The hydatid cyst of the heart is secondary to the intracardiac development of *Echinococcus granulosus*. The intermediate host of this parasite is sheep. Humans, the incidental host, become infected by ingesting embryonated eggs which soil a dog's coat or food. The embryo, released in the stomach, crosses the wall of the intestine, the hepatic and pulmonary filter to reach the left heart. From there, it can be distributed in the coronary circulation and end its course in the myocardium where it encysts [4].

The left ventricle (LV) being twice as irrigated as the right, hydatid damage is preponderant on the left (left ventricle 60%, right ventricle 10%, interventricular septum 4%, right atrium 4%) [5,6,7]. The development of intracardiac hydatid cyst is usually subepicardial for localizations in the left heart and subendocardial for those in the right heart, given the low-pressure regime of the right cavities. This explains the possibility of intra-pericardial rupture [5,6] in left localizations hydatid of the heart into the right cavities of the heart.

The clinical presentation of hydatid cyst of the heart (HCH) is very unspecific. The notion of exposure to dogs and sheep, the endemic context or the personal history of other hydatid localizations should suggest the diagnosis [4] as in our case.

The ECG may be normal or show ST segment elevation or depression in the event of myocardial compression or cyst rupture [7]. Biologically, hypereosinophilia can be noted. Hydatid serology is of great diagnostic value but it suffers from false negatives and cross-reactions with other parasitosis [4,9].

Attila has shown that transthoracic echocardiography can reveal unilocular or multivesicular cysts with well-defined contours, with uniform anechoic content, which may calcify, and hypoechoic with multiple septa. Infected hydatid cysts can sometimes appear as echogenic lesions resembling secondary cardiac tumors [7,10]. More detailed images can be obtained by transesophageal echocardiography. MRI and CT scan have better sensitivity and specificity than echocardiography in evaluating pericardial masses and analyzing their relationship to surrounding structures. Pulmonary and mediastinal hydatid cystic lesions can also be found [9,11,12]

The evolution of hydatid cyst of the heart can lead to severe complications such as [4]:

- intracardiac rupture with systemic or pulmonary embolic accidents, anaphylactic shock,
- intrapericardial rupture,
- conductive disorders (especially septal location),
- myocardial ischemia

For this, the treatment of hydatid cyst of the heart must be rapid. It is based on surgical excision. In our case, the patient was rejected for surgery because of the multiple cerebral and pulmonary localizations of the hydatid cyst, which was complicated by hemoptysis after rupture of hydatid cyst in the lungs and cerebral engagement, followed by death.

Certain studies showed that only high-risk patients or those with a small calcified cyst (indicating a dead cyst) and without

hemodynamic complications should be considered for conservative therapy [8,13]. The option of isolated medical treatment has also been proposed as an alternative to surgery in certain cases such as in the elderly or in the event of refusal of surgery [4] as in our case. A combination of corticosteroids, H1 and H2 receptor blockers, and benzodiazepines may be advocated for anaphylactic coverage [14,15].

Therapy is often in oral form with albendazole, a dose of 15mg/kg/day.

#### 4. CONCLUSION

Cardiac hydatid is a very rare manifestation of hydatid disease. It can have fatal complications of intracardiac rupture, myocardial infarction, ventricular tachycardia, conduction disorder such as AV- bloc in septal localization, sudden cardiac arrest or systemic pulmonary embolism.

The diagnosis is suggested by the identification of cysts in a multi septate lesion, presence of hydatid sand and calcification of the walls. Transthoracic echocardiography is the tool of choice for the diagnosis of cardiac hydatid cysts due to its availability, high sensitivity, and ability to concurrently analyze hemodynamic consequences. CT scans and MRI can help pinpoint the location of the lesion and detect other extracardiac localizations.

This case describes an unusual localization of E. granulosis in the heart with brain and lung involvement associated with a poor prognosis.

#### DISCLAIMER

The products used for this research are commonly and predominantly use products in our area of research and country. There is absolutely no conflict of interest between the authors and producers of the products because we do not intend to use these products as an avenue for any litigation but for the advancement of knowledge. Also, the research was not funded by the producing company rather it was funded by personal efforts of the authors.

#### CONSENT

As per international standard or university standard, patients' written consent has been collected and preserved by the author(s).

#### ETHICAL APPROVAL

As per international standard or university standard written ethical approval has been collected and preserved by the author(s).

#### ACKNOWLEDGEMENT

I thank the whole Department of Cardiology, university teaching hospital Ibn Rochd for supporting the work.

#### COMPETING INTERESTS

Authors have declared that no competing interests exist.

#### REFERENCES

1. Omar Ouzzad, Hicham Kechna, Mohamed Karim Moudden, Khalid Chkoura, Sidi Mohamed Hanafi. Arrêt cardiaque au cours d'une chirurgie de kyste hydatique du foie Pamj. 2015; 6909; p. 22-32
2. Edlira Rruci, Ketjon Menkshi, Saimir Kuçi, Afërdita Veseli, Gentian Vyshka Cardiac Hydatid Cyst: A Case Report Global Journal of Medical Case Reports. 2022;2:1-4.
3. Alaa S Bahjat, Ahamd Mohammad Sharif Tahir, Ayad Ahmad Mohammed. Hydatid cyst of the heart with mitral valve stenosis Case report Ann Med Surg (Lond). 2020;49:49–52.
4. Bhagwati Pant, Ananthkrishnan Ramesh, Raja Selvaraj. Hydatid cyst of the interventricular septum – A rare cause of heart block Indian Pacing Electrophysiol J. 2019;19:79–80.
5. Kosecik M, Karaoglanoglu M, Yamak B. Pericardial hydatid cyst presenting with cardiac tamponade. Can J Cardiol. 2006;22:145-7.
6. Sascha Kahlfuß, Robert Rainer Flieger, Torsten Kai Roepke, Kadir Yilmaz Diagnosis and treatment of cardiac echinococcosis Heartjnl. 2016;102;1348-1353
7. Muthu SK, Thiagarajan A, Govindarajan S, Coutinho CMA, Gunawardena WJ, Swaminathan TS. Hydatid cyst of the cardiac interventricular septum: report of two cases The British Journal of Radiology. 2007;80:278–282
8. Yuksel Besir, Arif Gucu, Suleyman Surer, Orhan Rodoplu, Mehmet Melek, Omer

- Tetik. Giant cardiac hydatid cyst in the interventricular septum protruding to right ventricular epicardium. Indian heart journal. 2013;65;81-83.
9. Bouassida I, Pricopi C, Mangiameli G, Arame A, Auliac JB, Gorbatai B, Riquet M, Le Pimpec Barthes F. Compression cardiaque d'origine hydatique. Rev de Pneumol clin. 2018;676:03-009.
  10. Ceviz M, Becit N, Kocak H. Infected cardiac hydatid cyst. Heart. 2001;86:13.
  11. Naqibullah Foladi, Farhad Farzam, Mer Mahmood Shah Hoshang, Mohammad Saboor Rastin, Mohammad Tahir Aien. incidental left ventricular myocardial hydatid cyst – A case report. Radiol Case Rep. 2022;17:496–501.
  12. Yan F, Huo Q, Abudureheman M, Qiao J, Ma S, Wen H. Surgical treatment and outcome of cardiac cystic echinococcosis. Eur JCard Thor Surg. 2015;47:1053—8.
  13. R, Eryilmaz S, Yazicioglu L, Eren NT, Durdu S, Uysalel A, et al. Surgery for cardiac hydatid disease: an Anatolian experience. Anadolu Kardiyol Derg. 2003;3:8–44.
  14. Koppen S, Wejda B, Dormann A, Seesko H, Huchzermeyer H, Junghanss T. Anaphylactic shock caused by rupture of an echinococcal cyst in a 25-year-old asylum seeker from Georgia. Dtsch Med Wochenschr. 2003;128:663–6.
  15. Ouechtati W, Bajjar K, Sidhom S, Bezdeh L, Belheni A. Kyste hydatique du coeur - À propos d'une observation. Cardiologie pratique.com, axis santé. 2011;1-6.

© 2022 Zenouaki et al.; This is an Open Access article distributed under the terms of the Creative Commons Attribution License (<http://creativecommons.org/licenses/by/4.0>), which permits unrestricted use, distribution, and reproduction in any medium, provided the original work is properly cited.

*Peer-review history:*  
*The peer review history for this paper can be accessed here:*  
<https://www.sdiarticle5.com/review-history/84820>