



A Retrospective Study on Management of the Distal End of the Radius Fractures

**R. Sanjay^{1*}, V. Aakash¹, Menakuru Sreya Reddy²
and G. Ram Kumar¹**

¹Department of Orthopedics, Saveetha Medical College and Hospital, India.

²Saveetha Medical College and Hospital, India.

Authors' contributions

This work was carried out in collaboration among all authors. All authors read and approved the final manuscript.

Article Information

DOI: 10.9734/JPRI/2021/v33i48B33261

Editor(s):

(1) Dr. Rafik Karaman, Al-Quds University, Palestine.

Reviewers:

(1) Naresh Bhaskar Raj, Universiti Sultan Zainal Abidin, Malaysia.

(2) Tejas Patil, MUHS, India.

Complete Peer review History: <https://www.sdiarticle4.com/review-history/75127>

Original Research Article

Received 10 August 2021
Accepted 13 October 2021
Published 08 November 2021

ABSTRACT

Introduction: The distal end radius fracture is a common fracture type and represents about one sixth of all skeletal fractures. They commonly occur in young males and older females. In young adults it is more common to see a fracture of the Intra-articular component in distal radius, probably due to high-energy trauma such as road traffic accidents. The patient may come with symptoms of pain and swelling around the wrist, sometimes with deformity around the wrist or tenderness at an area with no obvious deformity.

Objectives: To analyse the various treatment methods and their outcomes.

Materials and Methods: It is a retrospective study conducted on the distal end of radius fractures by the orthopedic department of Saveetha Medical College and Hospital in the years 2018, 2019 and 2020. All the patients were examined both clinically and radiologically. Anteroposterior (AP) and lateral views of the wrist joint on both sides were obtained at the time of injury presentation. Fractures were classified according to the AO classification and anatomical features like the presence of dorsal tilt, radial shortening and loss of radial inclination are also assessed using the Sarmiento's modification of Lindstrom Criteria.

Results: Anatomical results evaluated according to Sarmiento's modification of Lindstrom criteria showed excellent results were more frequent with open reduction and internal fixation techniques but the most frequently used treatment modality is closed reduction and cast immobilisation.

Conclusion: There is no customised treatment for all distal end of radius fractures hence the treatment depends on various factors like the fracture type, characters, patient's demands and the surgeon's preference.

Keywords: *Distal end of radius fractures; Sarmiento's modification of Lindstrom criteria; POP casting; volar plate.*

1. INTRODUCTION

The distal end radius fracture is a common fracture type and represents about one sixth of all skeletal fractures hence it is important to understand the injuries, their treatment and complications. Initial assessment including the mechanism of injury, presence of any associated injuries and appropriate radiological investigation and evaluation is essential for the appropriate treatment of these fractures. They are most commonly seen in young males and older females [1,2].

The distal end of radius fractures were first described by Abraham Colles after whom the Colles fracture was named. In the young adult population, it is more common to see a fracture of the Intra-articular component in distal radius, probably due to high-energy trauma such as road traffic accidents. High-energy injuries often lead to shorn and impacted fractures of the articular surface of the distal end of the radius with displaced fracture fragments. In the older age group the most common fracture pattern seen is the extra-articular type probably occurring due to fall on outstretched hand weakened probably by osteoporosis.

The patient may complain of pain and swelling around the wrist, sometimes with deformity around the wrist or tenderness at an area with no obvious deformity. There may even be numbness due to nerve compression or may also come with severe pain and sensory deficits which points towards compartment syndrome.

The purpose of this study was to evaluate the different recoveries by radiological evaluation in patients treated with different methods of treatment like:

- a) Closed reduction and Plaster of Paris (POP) cast
- b) Ligamentotaxis (External Fixator)
- c) Open reduction and internal fixation (ORIF) with a volar plate.

2. METHODS AND MATERIALS REQUIRED

It is a retrospective study on the distal end of radius fractures conducted by the orthopedic department of Saveetha Medical College and Hospital with the approval of the Institutional Review Board (IRB) in the years 2018, 2019 and 2020 with a sample size of 41 patients. The inclusion criteria of this study were the patients gave their consent to undergo the treatment, patients presented within 3 weeks of injury, patients who did not have other associated fractures on the ipsilateral upper limb. The exclusion criteria involved those patients who were suffering from comorbid conditions preventing surgical intervention or those with local tissue conditions making surgery inadvisable. The presence of open fractures and polytrauma were also excluded from this study. The sample size was taken depending on the number of patients who came with distal end of radius fractures and fell within the inclusion criteria.

All the patients were examined both clinically and radiologically. Anteroposterior (AP) and lateral views of the wrist joint on both sides were obtained at the time of injury presentation. Fractures were classified according to the AO classification into type A (extra-articular), type B (partial articular) and type C (complete articular). Also in the radiographs the anatomical features like the presence of dorsal tilt, radial shortening and loss of radial inclination are also assessed before the treatment modality is decided upon.

When deciding upon a treatment modality, it is important to focus on recognition, management, and prevention of known associated complications in order to achieve the best possible outcome [3], this involves taking the patient factors that must be considered These factors include patient lifestyle, age, mental attitude, social support, comorbid conditions, and compliance with treatment can influence the likelihood for complications [4].

Pre-anaesthetic evaluation of the patients should be done for surgical treatment. The patients were followed up by clinical and radiological methods for one year at the intervals of 3rd week, 6th week, 12th week, 6th month, and the end of one year. Radiologically the anatomical evaluation of the fracture was done to assess the presence of residual dorsal angulation, radial shortening and loss of radial inclination were graded by using the Sarmiento's modification of Lindstrom Criteria [5].

3. RESULTS

Totally 40 patients were included in the study out of which 32 were male and 8 were female. In terms of age there were two patients between 10 to 20 years and 11 between the ages of 21 to 30 years and 8 between the ages of 31 to 40 years and 5 were above the age of 50 years. The youngest patient in the study was 15 years and the oldest was 82 years.

About 29 of the 40 fractures occurred due to a fall and the rest occurred due to road traffic accidents. The number of patients presenting with the distal end of the radius fractures were more during the second half of the year, between the months of July and December and were also found to be less in the year of 2020 due to the covid 19 pandemic [6].

According to the AO classification 19 of the subjects had a Type A (Extra Articular type of fracture), 7 had Type B (Partial articular fracture) and 12 had Type C (Complete Articular type of fracture). About 90 percent of the patients were treated within a week of injury. 21 of them were treated with closed reduction and Plaster of Paris (POP) cast, 8 with distractor application and 11 by open reduction and internal fixation (ORIF) with a volar plate.

All the subjects were followed up at intervals of 6th week, 12th week, 6th month, and the end of one year. The functional and anatomical evaluation of the distal end of the radius was done during these visits and at the end of the year the results were noted. The anatomical evaluation was done by measuring the residual dorsal tilt, radial shortening and loss of radial inclination and were graded based on Sarmiento's modification of Lindstrom Criteria.

Residual Dorsal Tilt: In the plaster group out of the 21 subjects 10 (47.61%) of them showed excellent results, 10 (47.61%) showed good

results and 1 (4.76%) showed fair results. In the ligamentotaxis group 4 (50%) showed excellent results and 4 (50%) showed good results, while 9 (81.81%) and 2 (18.18%) out of 11 showed excellent and good results respectively in the open reduction and internal fixation group. None of the groups showed poor results.

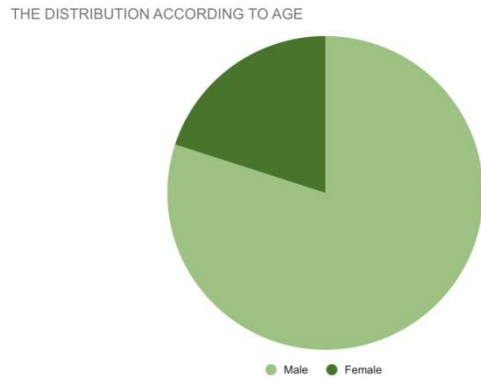
Radial Shortening: In the plaster group out of the 21 subjects 15 (71.42%) of them showed excellent results, 5 (23.80%) showed good results and 1 (4.76%) showed fair results. In the ligamentotaxis group 5 (62.5%) showed excellent results and 3 (37.5%) showed good results, while 10 (90.90%) and 1 (9.09%) out of 11 showed excellent and good results respectively in the open reduction and internal fixation group. None of the groups showed poor results.

Loss of Radial Inclination: In the plaster group out of the 21 subjects 17 (80.95%) of them showed excellent results, 4 (19.04%) showed good results. In the ligamentotaxis group 7 (87.5%) showed excellent results and 1 (12.5%) showed good results, while 11 (100%) out of 11 showed excellent results in the open reduction and internal fixation group. None of the groups showed poor results.

Physiotherapy: Physiotherapy was started from the 3rd week to help with pain, allow the patient to regain motion, strength and function. A rehabilitation program involving a physiotherapist directed advice and exercise provides some additional benefits over cases where no physiotherapy was done for adults with cast immobilisation and/or pinning of the distal end of radius fracture. This was confirmed by a randomised trial on the benefits of natural recovery after distal radius fracture [7,8]. There is also evidence of improved pain compared at 3rd and 6th week, reduced stiffness at 3rd week and there is a greater satisfactory result [9].

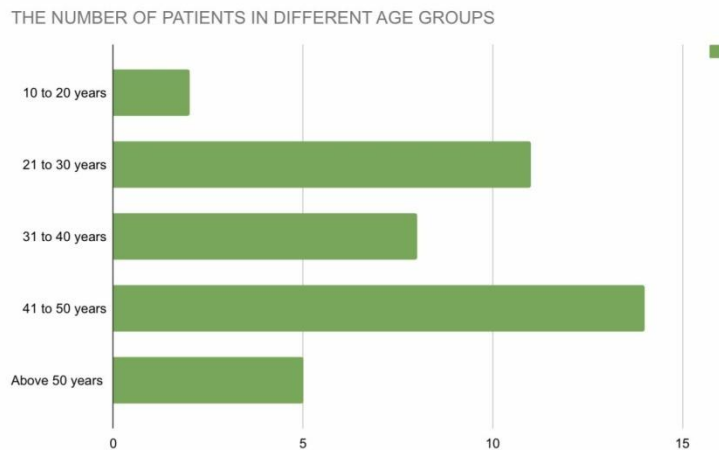
Complications: Two complications were seen among the subjects during the course of the study i.e, finger stiffness and arthritic change. In the plaster group, 8 (38.09%) developed finger stiffness and 1 (4.76%) developed arthritic change. In the distractor group 2 (25%) developed finger stiffness and 1 (12.5%) developed arthritic change. In the open reduction and internal fixation group 2 (18.18%) developed arthritic change and 1 (9.09%) developed finger stiffness. Other complications like nerve injury, infections were not seen.

Table 1. The Distribution According To Gender



Gender	Number
Male	32
Female	8

Table 2. the number of patients in different age groups



Age	Number
10 TO 20 Years	2
21 TO 30 Years	11
31 to 40 Years	8
41 to 50 Years	14
above 50 Years	5

4. DISCUSSION

Fractures of distal radius account for up to 20% of all fractures treated in the emergency department [10]. It is more commonly seen in young males and elderly females [11], their prevalence in women older than 35 years is four times more than in their male counterparts [12]. The severity of these fractures and the clinical

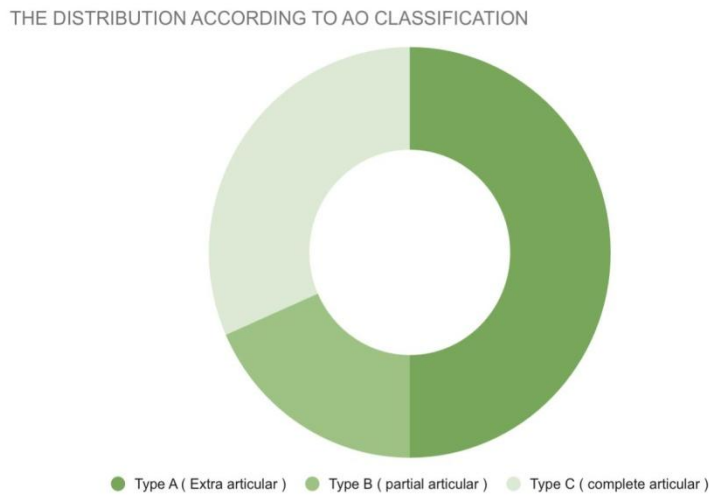
results after treatment are also dependent on the bone mineral density of the patient. When there is a dorsal tilt >9°, loss of radial inclination >3°, radial length >2 mm, and displacement of the articular surface >2 mm correction has to be done otherwise this will lead to decreased function and formation of a deformity. These corrections can be done using various methods like closed reduction and casting, closed

reduction and percutaneous pinning, external fixation, and open reduction with internal fixation (ORIF). The decision on the treatment modality to be used depends on patient lifestyle, age, mental attitude, social support, comorbid conditions, fracture pattern, compliance with treatment and surgeon experience [13].

The most commonly used method is the closed reduction and cast immobilisation method but this cannot be used in cases where there is radial shortening or if it's a comminuted fracture. It is easy to obtain reduction but difficult to

maintain it with a simple plaster cast. This may lead to malunion causing poor functional and cosmetic results. Another disadvantage of this method is that even with perfect initial alignment there can be a loss of the fracture reduction and if the cast is tight there can be complications like compartment syndrome and nerve injury. In our study 21 patients were treated with the closed reduction and casting method, one patient had a fair result in radial shortening and another had a fair amount of residual dorsal tilt. The major complications seen in this group was finger stiffness.

Table 3. The distribution according to AO classification



AO Classification	Number
TYPE A (Extra Articular)	19
TYPE B (Partial Articular)	7
TYPE C (Complete Articular)	12

Table 4. Anatomical evaluation of residual dorsal tilt

Group	Excellent (0°)	Good (1°-10°)	Fair (11°-14°)	Poor (>15°)
Plaster	10	10	1	0
Distractor	4	4	0	0
Orif	9	2	0	0

Table 5. Anatomical evaluation of radial shortening

Group	Excellent (<3 mm)	Good (3-6 mm)	Fair (7-11 mm)	Poor (>12 mm)
Plaster	15	6	1	0
Distractor	5	3	0	0
Orif	10	1	0	0

Table 6. Anatomical evaluation of loss of radial inclination

GROUP	Excellent (<5°)	Good (5°- 9°)	Fair (10°- 14°)	Poor (>14°)
Plaster	17	4	0	0
Distractor	7	1	0	0
Orif	11	0	0	0

The method of External Fixation (Distractor) is used to significantly reduce the presence of Residual dorsal tilt, Radial shortening and the Loss of radial inclination. 8 patients were treated by this method and all of them showed either excellent or good results and complications of arthritic change was seen in 1 and finger stiffness was seen in 2 out of the 8 subjects. In the case of comminuted fractures along with external fixation pinning can be done. The complications of external fixation with pinning are pin tract infection, pin loosening, loss of reduction in osteoporotic bone, sub optimal reduction in intra-articular fractures, wrist stiffness etc.

About 11 patients in our study were treated with Open Reduction Internal Fixation, out of which the majority showed excellent results in the correction of all the above parameters. The complications that were seen are finger stiffness (18.18%) and arthritic change (9.09%).

Our study found that between external fixation and open reduction and internal fixation (ORIF), ORIF was found to be better in terms of both anatomical evaluation and the complications. This is in contrast to a retrospective comparative study conducted on the surgical management of distal end of radius fractures [14] which found no differences between EF and ORIF outcomes. However a randomized controlled trial on displaced intra-articular fractures of the distal radius conducted on displaced intra-articular fractures of distal radius [15] in 2000 and another conducted in the year 2021 [16] also found that open reduction internal fixation was for anatomical fixation rather than external fixation. Another study showed that closed reduction with percutaneous pinning showed good results with decreasing the length of hospital stay and was more cost effective [17].

5. CONCLUSION

Hence in conclusion there is no tailored solution for all the fractures of the distal end of radius fractures. The treatment depends on various factors like fracture type, the patient's needs, the patient's demands and surgeon's experience and preference. Also prevention of complications

should be the surgeon's most important concern and the patients should be made aware of the symptoms associated with these complications and monitored closely with follow-up appointments and if any complications should arise they should be treated as early as possible to prevent long term complications.

ETHICAL APPROVAL AND CONSENT

It is a retrospective study on the distal end of radius fractures conducted by the orthopedic department of Saveetha Medical College and Hospital with the approval of the Institutional Review Board (IRB) in the years 2018, 2019 and 2020 with a sample size of 41 patients. The inclusion criteria of this study were the patients gave their consent to undergo the treatment, patients presented within 3 weeks of injury, patients who did not have other associated fractures on the ipsilateral upper limb

COMPETING INTERESTS

Authors have declared that no competing interests exist.

REFERENCES

1. Handoll HH, Vaghela MV, Madhok R. Percutaneous pinning for treating distal radial fractures in adults. *Cochrane Database of Systematic Reviews*. 2007;3.
2. Alluri RK, Hill JR, Ghiassi A. Distal radius fractures: approaches, indications, and techniques. *The Journal of Hand Surgery*. 2016 Aug 1;41(8):845-54.
3. Rhee PC, Dennison DG, Kakar S. Avoiding and treating perioperative complications of distal radius fractures. *Hand Clinics*. 2012 May 1;28(2):185-98.
4. Ilyas AM, Jupiter JB. Distal radius fractures—Classification of treatment and indications for surgery. *Orthopedic Clinics of North America*. 2007 Apr 1;38(2):167-73.
5. Sarmiento A, Pratt GW, Berry NC, Sinclair WF. Colles' fractures. Functional bracing in supination. *The Journal of Bone and Joint Surgery*. American Volume. 1975 Apr 1;57(3):311-7.

6. Saladié Ò, Bustamante E, Gutiérrez A. COVID-19 lockdown and reduction of traffic accidents in Tarragona province, Spain. *Transportation Research Interdisciplinary Perspectives*. 2020 Nov 1;8:100218.
7. Kay S, McMahon M, Stiller K. An advice and exercise program has some benefits over natural recovery after distal radius fracture: A randomised trial. *Australian Journal of Physiotherapy*. 2008 Jan 1;54(4):253-9.
8. Valdes K. A retrospective pilot study comparing the number of therapy visits required to regain functional wrist and forearm range of motion following volar plating of a distal radius fracture. *Journal of Hand Therapy*. 2009 Oct 1;22(4):312-9.
9. Michlovitz SL, LaStayo PC, Alzner S, Watson E. Distal radius fractures: therapy practice patterns. *Journal of Hand Therapy*. 2001 Oct 1;14(4):249-57.
10. Meena S, Sharma P, Sambharia AK, Dawar A. Fractures of distal radius: an overview. *Journal of Family Medicine and Primary Care*. 2014 Oct;3(4):325.
11. Ahlborg HG, Johnell O, Turner CH, Rannevik G, Karlsson MK. Bone loss and bone size after menopause. *New England Journal of Medicine*. 2003 Jul 24;349(4):327-34.
12. O'Neill TW, Cooper C, Finn JD, Lunt M, Purdie D, Reid DM, Rowe R, Woolf AD, Wallace WA. Incidence of distal forearm fracture in British men and women. *Osteoporosis International*. 2001 Aug;12(7):555-8.
13. Chung KC, Kotsis SV, Kim HM. Predictors of functional outcomes after surgical treatment of distal radius fractures. *The Journal of Hand Surgery*. 2007 Jan 1;32(1):76-83.
14. Westphal T, Piatek S, Schubert S, Winckler S. Outcome after surgery of distal radius fractures: No differences between external fixation and ORIF. *Archives of Orthopaedic and Trauma Surgery*. 2005 Oct;125(8):507-14.
15. Kapoor H, Agarwal A, Dhaon BK. Displaced intra-articular fractures of distal radius: A comparative evaluation of results following closed reduction, external fixation and open reduction with internal fixation. *Injury*. 2000 Mar 1;31(2):75-9.
16. Rudramuni AK, Patil S. A prospective study of clinical and radiological outcome of fractures of distal end radius treated using volar rim plate. *International Journal of Orthopaedics*. 2021;7(3):813-6.
17. Dave A. Study of the functional and radiological outcome of surgical management of unstable extra-articular fracture of distal end of radius by closed reduction and internal fixation with K wire. *International Journal of Science and Research (IJSR)*. 2021;10(2):1462–1466.

© 2021 Sanjay et al.; This is an Open Access article distributed under the terms of the Creative Commons Attribution License (<http://creativecommons.org/licenses/by/4.0>), which permits unrestricted use, distribution, and reproduction in any medium, provided the original work is properly cited.

Peer-review history:

The peer review history for this paper can be accessed here:
<https://www.sdiarticle4.com/review-history/75127>