



# A Study of Laparoscopic Transabdominal Preperitoneal Repair in Inguinal Hernia

Atish N Bansod <sup>a++\*</sup>, Niteen B Sawase <sup>a#</sup>,  
Mauktik Satpudke <sup>a#</sup> and Yusuf Hakim <sup>a#</sup>

<sup>a</sup> Department of General Surgery, IGGMCH, Nagpur, Maharashtra, India.

## Authors' contributions

This work was carried out in collaboration among all authors. All authors read and approved the final manuscript.

## Article Information

DOI: <https://doi.org/10.9734/jammr/2024/v36i105609>

## Open Peer Review History:

This journal follows the Advanced Open Peer Review policy. Identity of the Reviewers, Editor(s) and additional Reviewers, peer review comments, different versions of the manuscript, comments of the editors, etc are available here: <https://www.sdiarticle5.com/review-history/124163>

Original Research Article

Received: 01/08/2024

Accepted: 02/10/2024

Published: 07/10/2024

## ABSTRACT

**Background:** Laparoscopic Transabdominal Preperitoneal (TAPP) repair is a minimally invasive technique for managing inguinal hernias, offering benefits like reduced postoperative pain, quicker recovery, and lower recurrence rates.

**Aims & Objective:** This study aimed to evaluate the clinical profile, safety, and feasibility of TAPP repair in patients with uncomplicated inguinal hernias, focusing on surgical outcomes and recovery metrics.

**Study Design:** This prospective interventional study was conducted in the Department of General Surgery at a tertiary care center. Institutional ethics committee approval was secured before the

<sup>++</sup> Associate Professor & Head of Unit;

<sup>#</sup> Junior Resident;

<sup>\*</sup>Corresponding author: E-mail: [atish6267@gmail.com](mailto:atish6267@gmail.com);

study commenced. Fifty patients with reducible, non-obstructed, and non-strangulated inguinal hernias participated after providing informed consent. Demographic data, clinical findings, and surgical outcomes were documented using a structured case report form, with preoperative investigations ensuring surgical suitability.

**Operative Procedure:** TAPP repair was performed under general anesthesia, involving pneumoperitoneum creation and trocar insertion. Key steps included meticulous dissection of the preperitoneal space, reduction of the hernia sac, placement of Prolene mesh over the defect, and closure of the peritoneal flap.

**Results:** Among the 50 cases, the most common age group was 41-50 years (30%), with a mean age of  $43 \pm 15$  years, and a male-to-female ratio of 49:1. Right-sided hernias (44%) were primarily indirect (76%). Mean operative times were  $70 \pm 10$  minutes for unilateral and  $110 \pm 10$  minutes for bilateral repairs. Postoperative pain scores decreased significantly, with minor complications noted: scrotal emphysema (2%) and port site infection (2%).

**Conclusion:** The study offers insights into the effectiveness and safety of TAPP repair for inguinal hernias. By analyzing demographics and surgical outcomes, we support TAPP repair as a preferred method in modern surgical practice.

*Keywords: Laparoscopic transabdominal preperitoneal; inguinal hernias; feasibility of TAPP.*

## 1. INTRODUCTION

Laparoscopic Transabdominal Preperitoneal (TAPP) repair has become a widely accepted method for managing inguinal hernias. This minimally invasive technique offers several advantages over traditional open surgery, including reduced postoperative pain, faster recovery, and lower recurrence rates. Given that inguinal hernias are among the most common surgical conditions, advancements in laparoscopic methods like TAPP have significantly impacted modern hernia management.

The TAPP technique involves placing a synthetic mesh in the preperitoneal space, effectively reinforcing the hernia defect while minimizing tissue trauma and enhancing anatomical visualization. However, TAPP repair necessitates advanced laparoscopic skills and carries risks such as injury to intra-abdominal structures and potential mesh-related complications.

This publication aims to examine the technical aspects, clinical outcomes, and challenges of laparoscopic TAPP repair for inguinal hernias, as well as its role in contemporary surgical practice. By reviewing current literature and clinical data, we aim to provide insights for optimizing patient outcomes and addressing the learning curve for surgeons adopting this technique.

## 2. MATERIALS AND METHODS

This prospective study assessed the outcomes of Laparoscopic Transabdominal Preperitoneal (TAPP) repair for inguinal hernias at government

hospital and tertiary care centre, following institutional ethics approval.

Data on demographics, clinical findings, and surgical outcomes were collected anonymously to evaluate the effectiveness and safety of the TAPP technique and postoperative recovery, contributing to the growing evidence supporting this minimally invasive approach. Patients were included after they fulfilled the inclusion criteria set for the study.

### Inclusion Criteria:

- Patients of inguinal hernia of age 12 years and above.
- Patients of both sexes.
- Patients with unilateral and bilateral inguinal hernia.
- Patients with recurrent inguinal hernia following open inguinal hernia repair.
- Patients with reducible inguinal hernia.

### Exclusion Criteria:

- Children less than 12 years
- Patients not willing to participate.
- Patients requiring emergency exploration for complications of hernia like irreducibility, bowel obstruction, strangulation, gangrene etc.
- Patients with uncorrectable coagulopathy.
- Patients who are unfit for general anaesthesia.
- Patients who have undergone lower abdominal surgery previously.

- Patients with previously failed laparoscopic repair of inguinal hernia.
- Patients with ascites, ANC patients, disseminated intraabdominal malignancy.

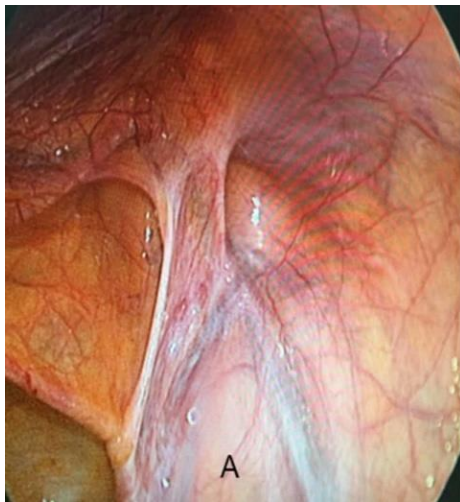**Study Design:** This is a prospective interventional study done in the department of general surgery in a tertiary care centre and teaching hospital.

**Study Duration:** This study was done from March 2022 to August 2024, the data collected was studied for the clinical profile of the patients with the demographic details, duration of the surgery, duration of hospitalization, complications after the surgery and to study the recurrence rate of the hernia.

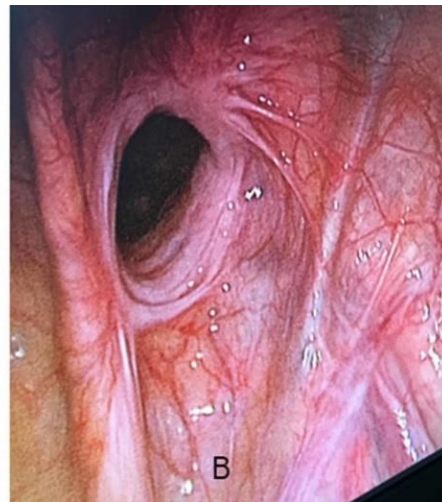
**Technique of Laparoscopic Transabdominal Preperitoneal (TAPP) Repair:** The patient is positioned supine with a slight Trendelenburg tilt. Pneumoperitoneum is established through an incision above the umbilicus, followed by trocar insertion. Two additional trocars are placed laterally for access.

Dissection begins 5 cm above the hernia to expose the defect while carefully avoiding key structures like the inferior epigastric vessels. The dissection is divided into three zones for proper mesh placement. The hernia sac is reduced, and a Prolene mesh is secured over the defect. The peritoneal flap is then repositioned and closed.

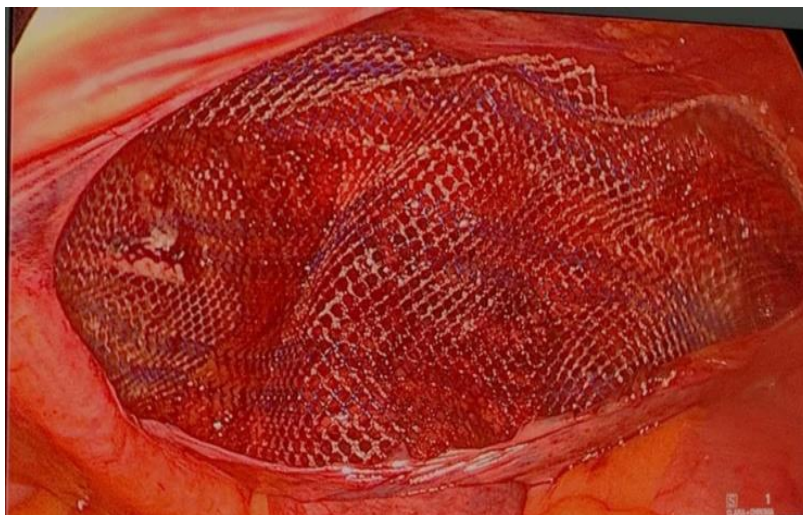
Finally, carbon dioxide is released, trocars are removed, and incisions are closed with sutures.



**Fig. 1 A. Indirect Hernia**



**Fig. 1B. Direct Hernia**



**Fig. 2. Prolene mesh placement**

**Study Factors:** This study aims to analyse the clinical profile of patients undergoing laparoscopic Transabdominal Preperitoneal (TAPP) repair for inguinal hernias, focusing on demographics, types of hernias, and medical histories. We will evaluate management practices from preoperative preparation to postoperative care. Key outcomes include intra-operative and postoperative complications, hospital stay duration, recovery time, and hernia recurrence rates. Ultimately, the study seeks to provide insights into the efficacy, safety, and impact of laparoscopic TAPP repair on patient outcomes.

**Sex Distribution:** In this study of 50 patients undergoing laparoscopic TAPP repair for inguinal hernia, 49 were male and 1 was female, resulting in a male-to-female ratio of 49:1 (98% male, 2% female), highlighting the higher prevalence of inguinal hernias in males.

**Side of Hernia:** In this study of 50 patients undergoing laparoscopic TAPP repair for inguinal hernia, 39 patients (78%) had unilateral hernias and 11 patients (22%) had bilateral hernias. Among unilateral hernias, right-sided cases predominated, with 24 patients (61.53%).

### 3. RESULTS

**Age Distribution:** In a study of 50 patients undergoing laparoscopic TAPP repair for inguinal hernia, the highest incidence was in the 41-50 years age group (30%, 15 cases), followed by 51-60 years (24%, 12 cases). The mean age was 43±15 years. The age distribution was as follows:

**Type of Hernia:** In this study of 50 patients undergoing laparoscopic TAPP repair for inguinal hernia, 76% (38 cases) were indirect inguinal hernias, 22% (11 cases) were direct inguinal hernias, and 2% (1 case) were pantaloon hernias, indicating a predominance of indirect inguinal hernias.

**Table 1. Age distribution of patients**

Age in Years	No. of Patients	Percent
12 – 20	2	4%
21 – 30	8	16%
31 – 40	10	20%
41 – 50	15	30%
51 – 60	12	24%
61 – 70	2	4%
71 – 80	1	2%
<b>TOTAL</b>	<b>50</b>	<b>100%</b>

**Table 2. Gender Distribution**

Gender	No. of Patients	Percent
Male	49	98%
Female	1	2%
<b>Total</b>	<b>50</b>	<b>100%</b>

**Table 3. Sides of hernia**

Side of Hernia	NO. of Patients	Percent
Right	22	44%
Left	17	34%
Unilateral	39	78%
Bilateral	11	22%
<b>TOTAL</b>	<b>50</b>	<b>100%</b>

**Table 4. Types of hernia**

Type of Hernia	No. of Patients	Percent
Indirect	38	76%
Direct	11	22%
Pantaloon	1	2%
<b>Total</b>	<b>50</b>	<b>100%</b>

**Predisposing Factors of Inguinal Hernia:** In this study of 50 patients undergoing laparoscopic TAPP repair, the following predisposing factors were noted: chronic cough (28%, 14 patients), chronic smoking (16%, 8 patients), urinary obstructive symptoms (14%, 7 patients), and prostatomegaly (4%, 2 patients).

**Time Duration of the Procedure:** In this study of laparoscopic TAPP repair for inguinal hernia, the procedure time varied by type: unilateral repairs took 60 to 90 minutes (mean 70 ± 10 minutes), while bilateral repairs took longer, ranging from 100 to 120 minutes (mean 110 ± 10 minutes).

**Postoperative Pain Score:** In this study of laparoscopic TAPP repair, pain was assessed

using the Visual Analog Scale (VAS). Mean pain scores were 3-5 on day one (moderate), <1 by day seven, and 0.008 by day thirty (minimal pain).

**Return to Basic Activity:** The mean time to resume activities was 24 hours. Seventy-six percent of patients (38 patients) returned to work within one week

**Postoperative Complications:** In a study of 50 laparoscopic TAPP repairs for inguinal hernia, complications included scrotal emphysema (2 patients, 4%), port site infection (1 patient, 2%), and urinary retention (1 patient, 2%). No chronic pain, recurrence, or major complications occurred, and no conversions to open surgery were needed.

**Table 5. Predisposing Factors**

Predisposing Factor	NO. of Patients	Percent
Chronic cough	14	28%
Urinary obstructive symptoms	7	14%
Chronic smoker	8	16%
Pulmonary TB	0	0%
Prostatomegaly	2	4%

**Table 6. Time duration of the procedure**

Type of Hernia	Time Duration (Mean Time)
Unilateral	60-90 mins (70 ± 10)
Bilateral	100-120 mins (110 ± 10)

**Table 7. Postoperative Pain**

Pain Score (VAS)	Patients	Percentage
Mild (1-3)	36	72%
Moderate (4-6)	12	24%
Severe (>6)	2	4%

**Table 8. RETURN TO ACTIVITIES**

Patients	Return to Activities (Weeks)	Percentage
38	< 1 week	76%
10	1 to 2 weeks	20%
2	2 to 3 weeks	4%

**Table 9. Post-operative complications**

Symptoms	No. of Patients	Percentage
Urinary retention	1	2%
Port site infection	1	2%
Scrotal emphysema	2	4%
Recurrence	0	0%
Chronic pain	0	0%

#### 4. DISCUSSION

**Age Distribution:** In our study of laparoscopic TAPP repair for inguinal hernia, the most common age groups were 41-50 years (30%) and 51-60 years (24%), with a mean age of 43 years. This aligns with Md. Mamunur Rahman et al. [1] who reported a mean age of  $38.88 \pm 10$  years, and Abdul Hakeem et al. [2] with  $47.8 \pm 10.54$  years. However, our results are higher than those of Deborshi S et al. [3] and Pandya B et al. [4], who reported mean ages of 49 years and a range of 14-95 years, respectively. Variations in age distribution may relate to anatomical changes, physical activity, and smoking-related factors contributing to inguinal hernia development.

**Gender Distribution of Patients:** In our study of laparoscopic TAPP repair for inguinal hernia, 49 out of 50 patients were male, resulting in a male-to-female ratio of 49:1 (98% male, 2% female). This aligns with findings from Manyilirah et al. [5] and Youssef et al. [6], which also reported a male predominance attributed to anatomical factors and lifestyle choices that increase hernia risk.

**Types of Hernia:** In this study, 76% of cases were indirect inguinal hernias, 22% direct hernias, and 2% combined types. This finding is consistent with previous studies: Pankaj S et al. [7] reported 72% indirect and 28% direct, while B.S. Gedam et al. [8] found 65.21% indirect and 35.79% direct. The higher prevalence of indirect hernias is generally attributed to anatomical and developmental factors, while direct hernias are more common in the elderly due to abdominal wall weakness.

**Sides of Hernia:** In our study on laparoscopic Transabdominal Preperitoneal (TAPP) repair for inguinal hernia, 78% of patients had unilateral hernias, with 61.53% of these being right-sided. This is consistent with previous studies: Ahmed et al. [9] reported 60% right-sided hernias, B.S. Gedam et al. [8] found 66.30%, and Md. Mamunur et al. [1] observed 62.5%. The higher prevalence of right-sided hernias is attributed to the delayed descent of the right testicle during fetal development.

**Predisposing Factors of Inguinal Hernia:** Chronic cough and smoking were identified as significant predisposing factors in our study, with chronic cough present in 28% of patients and smoking in 16%. This is in line with other studies:

Z Abbas et al. [10] found 24% for smoking and 8% for chronic cough, while Suraj B Singh et al. [11] reported 44% and 10%, respectively. Chronic cough increases intra-abdominal pressure, and smoking contributes to this risk by weakening abdominal muscles and often leading to chronic cough.

**Time Duration of the Procedure:** Unilateral TAPP hernia repairs averaged  $70 \pm 10$  minutes, and bilateral repairs averaged  $110 \pm 10$  minutes. These times align with findings from Pankaj et al. [7] and Md Mamunur et al. [1], and are slightly longer than those reported by S Ahmad et al. [12]. Surgery duration varies with the surgeon's skill and experience.

**Post-Operative Hospital Stay:** Patients had a mean hospital stay of  $3.2 \pm 1.3$  days, with 76% discharged within 48 to 72 hours. This is consistent with Xuan NT et al. [12] and Ahmad S et al. [13]. Shorter hospital stays are influenced by effective surgical techniques and good post-operative care.

**Post-Operative Pain Score:** Post-operative pain was mild in 72% of cases, moderate in 24%, and severe in 4%. This is comparable to findings by Md Mamunur et al. [1] and Nguyen Thanh Xuan et al. [13], with variations due to differences in surgical technique and patient pain perception [14-20].

**Post-Operative Complications:** Complications included urinary retention (2%), scrotal emphysema (4%), and port site infection (2%). These rates are consistent with Pankaj et al. [7] and Nguyen Thanh Xuan et al. [12], and are relatively low, reflecting skilled surgical techniques and careful post-operative management.

Among the 50 patients who underwent laparoscopic TAPP as part of this prospective interventional study, none of the patients develop seroma/hematoma in the post operative period, be note as a post operative complication in the findings of this prospective study. 1 patient included in this prospective interventional study, developed port site infection at the site of laterally introduced trocar. This was managed by intravenous antibiotics and daily cleaning and dressing with local application of betadine ointment. There was no incidence of mesh infection secondary to port site infection [21-23].

**Return to Basic Activities:** Seventy-six percent of patients returned to work within 1 week, with

20% returning within 2 weeks, and 4% taking 3 weeks. These results are similar to findings by Nguyen Thanh Xuan et al. [12] and Abdul Hakeem et al. [2], indicating a quick recovery and return to daily activities.

## 5. CONCLUSION

The study on laparoscopic transabdominal preperitoneal (TAPP) repair for inguinal hernia confirms it as a safe and effective technique. It offers benefits such as improved aesthetics, reduced post-operative pain, shorter hospital stays, and fewer complications compared to traditional methods. The TAPP approach provides excellent anatomical visualization and is effective for both common and complex hernias, including recurrent cases. It also helps prevent femoral and obturator hernias with Prolene mesh placement. The study finds inguinal hernias are most common in middle-aged and elderly males, with indirect hernias often linked to chronic cough and direct hernias to lower urinary tract obstruction. Patients experience less pain and faster recovery, with no chronic groin pain or complications from foreign bodies.

## CONSENT

As per international standards or university standards, patient(s) written consent has been collected and preserved by the author(s).

## ETHICAL APPROVAL

The study has received and preserved written ethical approval in accordance with international and university standards.

## DISCLAIMER (ARTIFICIAL INTELLIGENCE)

Author(s) hereby declared that NO generative AI technologies such as Large Language Models (ChatGPT, COPILOT, etc) and text-to-image generators have been used during writing or editing of this manuscript.

## COMPETING INTERESTS

Authors have declared that no competing interests exist.

## REFERENCES

1. Md Mamunur Rahman, Jahan N, Hoque MM, Islam MS, Alam MS, Roy SC, Ahmed TN. Transabdominal pre-peritoneal (TAPP) laparoscopic inguinal hernia repair: Our experience with 40 cases. *Journal of Surgical Sciences*. 2020 Nov 1;24(1):11-4.
2. Hakeem A, Saqib SU, Zafar H. Return to Work in Patients With Unilateral Inguinal Hernia Surgery: A Comparative Study Between Laparoscopic Transabdominal Preperitoneal Approach and Lichtenstein Tension-Free Mesh Repair. *Cureus*. 2023 May;15(5).
3. Deborshi Sharma, et al of Prospective randomized trial comparing laparoscopic transabdominal preperitoneal (TAPP) and laparoscopic totally extra peritoneal (TEP) approach for bilateral inguinal hernias August 2015.
4. Pandya B, Huda T, Gupta D, Mehra B, Narang R. Abdominal wall hernias: An epidemiological profile and surgical experience from a rural medical college in central India. *The Surgery Journal*. 2021 Jan;7(01):e41-6.
5. Manyilirah W, Kijjambu S, Upoki A, Kiryabwire J. Comparison of non-mesh. (Desarda) and mesh (Lichtenstein) methods for inguinal hernia repair among black African patients: a short-term double-blind RCT. *Hernia*. 2012 Apr;16:133-44.
6. Youssef T, El-Alfy K, Farid M. Randomized clinical trial of Desarda versus Lichtenstein repair for treatment of primary inguinal hernia. *International journal of surgery*. 2015 Aug 1;20:28-34.
7. Pankaj S, Pankaj D, Ashwani K, Vijay K, Anand M. Laparoscopic Transabdominal Pre-Peritoneal (Tapp) Procedure for Inguinal Hernia: Our Experience in a Developing Country. *Journal of Surgical Academia*. 2014;4(2):21-3.
8. Gedam BS, Bansod PY, Kale VB, Shah Y, Akhtar M. A comparative study of Desarda's technique with Lichtenstein mesh repair in treatment of inguinal hernia: A prospective cohort study. *International Journal of Surgery*. 2017 Mar 1;39:150-5.
9. Salma, U., Ahmed, I. and Ishtiaq, S., 2015. A comparison of post operative pain and hospital stay between Lichtenstein's repair and Laparoscopic Transabdominal Preperitoneal (TAPP) repair of inguinal hernia: A randomized controlled trial. *Pakistan journal of medical sciences*, 31(5), p.1062.
10. Abbas Z, Bhat SK, Koul M, Bhat R. Desarda's no mesh repair versus lichtenstein's open mesh repair of inguinal hernia: A comparative study. *Journal of evolution of Medical and Dental Sciences*. 2015;4(77):13279-86.



11. Singh S, Prakash R, Singh V. A clinical study of inguinal hernia with special reference to laparoscopic trans-abdominal preperitoneal repair. *International Surgery Journal*. 2017;4(1):282-90.
12. Xuan NT, Son NH. Laparoscopic transabdominal preperitoneal technique for inguinal hernia repair in adults. *Cureus*. 2020 Jun;12(6).
13. Ahmad S, Aslam R, Iftikhar M, Alam M. Early Outcomes of Laparoscopic Transabdominal Preperitoneal (TAPP) Repair. *Cureus*. 2023 Feb;15(2). Jiao J, Zhu X, Zhou C, Wang P. Single-incision laparoscopic transabdominal preperitoneal hernioplasty: 1,054 procedures and experience. *Hernia*. 2023 Oct;27(5):1187-94.
14. O'Connell PR, McCaskie AW, Sayers RD. *Bailey & Love's short practice of surgery*. CRC Press; 2023 Mar 30. Chapter 64, Edi 26
15. Miserez M, Peeters E, Aufenacker T, et al. Update with level 1 studies of the European Hernia Society guidelines on the treatment of inguinal hernia in adult patients. *Hernia*. 2014;18(2):151–163. DOI: 10.1007/s10029-014-1236-6.
16. Murphy KP, O'Connor OJ, Maher MM. Adult abdominal hernias. *American journal of roentgenology*. 2014 Jun;202(6): W506-11.
17. Fitzgibbons Jr RJ, Ramanan B, Arya S, Turner SA, Li X, Gibbs JO, Reda DJ. Longterm results of a randomized controlled trial of a nonoperative strategy (watchful waiting) for men with minimally symptomatic inguinal hernias. *Annals of surgery*. 2013 Sep 1;258(3):508-15.
18. Kingsnorth A, LeBlanc K. Hernias: inguinal and incisional. *The Lancet*. 2003 Nov 8;362(9395):1561-71.
19. Inguinal Region Anatomy: Overview, Gross Anatomy, Pathophysiological Variants [Emedicine.medscape.com](https://www.emedicine.com/med/topic1000.htm). Inguinal Region Anatomy: Overview, Gross Anatomy, Pathophysiological Variants [Internet].
20. Hernia Surgery: A Comparative Study Between Laparoscopic Transabdominal Preperitoneal Approach and Lichtenstein Tension-Free Mesh Repair. *Cureus*. 2023 May;15(5).
21. Agarwal PK. Study of demographics, clinical profile and risk factors of inguinal hernia: A public health problem in elderly males. *Cureus*. 2023 Apr;15(4).
22. Mohamed HE, ElSheikh M, Barakat H, Abdelhamid AF. A comparative study of mesh fixation versus nonfixation in laparoscopic totally extraperitoneal inguinal hernia repair. *The Egyptian Journal of Surgery*. 2019 Apr 1;38(2):348-55.

**Disclaimer/Publisher's Note:** The statements, opinions and data contained in all publications are solely those of the individual author(s) and contributor(s) and not of the publisher and/or the editor(s). This publisher and/or the editor(s) disclaim responsibility for any injury to people or property resulting from any ideas, methods, instructions or products referred to in the content.

© Copyright (2024): Author(s). The licensee is the journal publisher. This is an Open Access article distributed under the terms of the Creative Commons Attribution License (<http://creativecommons.org/licenses/by/4.0>), which permits unrestricted use, distribution, and reproduction in any medium, provided the original work is properly cited.

*Peer-review history:*

*The peer review history for this paper can be accessed here:*

<https://www.sdiarticle5.com/review-history/124163>