



Pulpectomy with Bi-Rooted Primary Maxillary Canine: A Case Report

**Sneha Himmatrao Khekade^{1*}, Arun Sajjanar¹, Miranda George¹,
Niharika Gahlod¹, Suryakant Kumar¹ and Milind Wasnik¹**

¹Department of Pediatric and Preventive Dentistry, Swargiya Dadasaheb Kalmegh Smruti Dental College and Hospital, Wanadongri, Hingna, Nagpur, Maharashtra, India.

Authors' contributions

This work was carried out in collaboration among all authors. All authors read and approved the final manuscript.

Article Information

DOI: 10.9734/JPRI/2021/v33i47A33039

Editor(s):

(1) Dr. Paola Angelini, University of Perugia, Italy.

Reviewers:

(1) Dharmashree Satyarup, Siksha 'O' Anusandhan University, India.

(2) Nagat Hassan Bubteina, University of Benghazi, Libya.

(3) J. Martos, Federal University of Pelotas, Pelotas, Brazil.

Complete Peer review History: <https://www.sdiarticle4.com/review-history/75719>

Case Study

Received 09 August 2021

Accepted 19 October 2021

Published 28 October 2021

ABSTRACT

Bi-rooted canines are extremely uncommon in the primary dentition and are only diagnosed after a radiographic examination. Endodontic success in teeth with more canals than are typically discovered necessitates an accurate diagnosis and a thorough clinical radiographic examination. To avoid complications, morphological differences in pulpal anatomy must be identified prior to treatment. Here we report a case of Pulpectomy in a bi-rooted primary maxillary canine.

Keywords: *Bi-rooted primary maxillary canine; pulpectomy; bifurcation of root.*

1. INTRODUCTION

The developmental anomalies affecting the morphology are fewer in number in Primary dentition as compared to permanent dentition [1]. Primary teeth can lead to endodontic and

extraction complications and problems in permanent tooth eruption. As a result, when performing endodontic treatment, keep in mind that the number of root canals may surpass the number of roots [2]. This is a case report of Pulpectomy in primary canine with two roots. The

*Corresponding author: E-mail: sneha.khekade@sdk-dentalcollege.edu.in;

main Objective of this case presentation is to increase awareness among dentists about the morphological variations in primary teeth. Proper assessment before endodontic and extraction procedures to avoid future complications related to morphological differences.

2. CASE REPORT

Carious teeth in the upper and lower jaw were the main complaint of an eight-year-old Indian boy who presented to the Department of Pedodontics and Preventive Dentistry. There were no systemic diseases, allergies, or trauma in the child's medical history. He didn't have any siblings. A mixed dentition with several carious lesions was discovered during an intra-oral examination. Teeth 54, 64, 74 and 84 were grossly decayed. Smooth surface caries were present with 52 and 53. Periapical radiographs demonstrated a unilateral double-rooted maxillary right primary canine. (Fig. no. 1) Closer radiograph revealed the presence of two roots with 53; bifurcation was present at coronal third of root which indicates two root formations began between 9 and month's postnatally [2]. The crown of this tooth was found to be normal in shape and size during a clinical examination. As a result, there is no risk of fusion or gemination, which can result in a single bigger crown or a fused crown. In addition, this tooth has carious lesion involving labial and incisal surfaces [3].

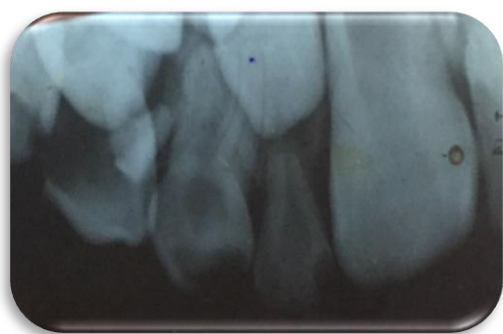

Fig. 1. IOPA with 53

2.1 Treatment

Patients parent were informed about the presence rare root anomaly of two roots and the treatment required. Informed consent was taken from the patient's parent. Pulpectomy followed by coronal composite restoration was indicated with 53 as during excavation it was found that caries were involving pulp. Smooth surface caries was present with 52 so Composite restoration was

done. Extraction with 54 and 64 followed by Nance palatal arch space maintainer was planned. Extraction with 74 and 84 followed by lingual arch space maintainer was fabricated.

Single visit Pulpectomy was performed with 53. The tooth was anaesthetized with 1.8 ml lidocaine 2% with epinephrine 1:100,000 at the first appointment. A no. 330 round carbide steel bur was used to remove the gross carious lesions. The pulp chamber was opened, the pulp was removed using a barbed broach, and the working length was measured with a K file. (Fig. no. 2). The two canals in 53 were negotiated and chemo mechanical preparation was done. The mesial canal was 11 mm long while the distal canal was 10 mm long. The canals were prepared up to size no. 35 K-file because the tooth had wide anatomical canals. The root canals were frequently irrigated with 1 percent NaOCl. Root canals were dried with absorbent paper tips. After that, zinc oxide eugenol type I cement was used to fill the canals. Reamer technique was used for Obturation. A radiograph verified that the Obturation was complete. (Fig. no.3) To avoid contact between zinc oxide eugenol and composite, the chamber was cleaned and glass-ionomer cement (type I) was applied near to the canal orifice (sandwich technique) and composite restoration was done with 53. The parents were given instructions when the procedure was completed to visit every 6 months for follow-up until the tooth exfoliated.

3. DISCUSSION

The first calcification of a primary maxillary canine tooth germ occurs at the embryonic age of 17 weeks, with enamel creation completing by 9 months after birth and root formation by 3 years 3 months[1]. The exact process that allows many roots to develop is unknown. It has been suggested that from the cervical loop of the dental organ, the inner and outer enamel epithelia proliferate as a double layer of cells known as Hertwig's epithelial root sheath. The epithelial diaphragm is formed when the outer and inner enamel epithelia bend at the future cemento-enamel junction. The major apical foramen is encircled by the rim of this sheath. Continued morpho-differentiation in multi-rooted teeth is triggered by an unknown cause. The tongue-like extensions of the horizontal diaphragm form, grow toward each other, and unite as a result of differential growth. From each new secondary apical foramen, a root develops [4,5,6]. Some researchers have

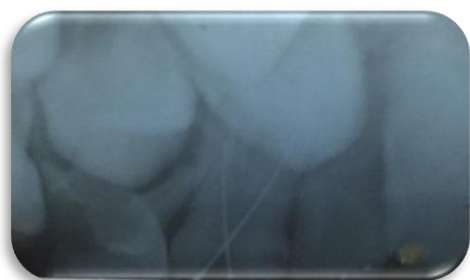

Fig. 2. Working Length determination

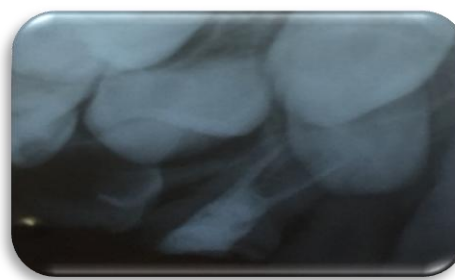


Fig. 3. Obturation with 53

suggested that fusion or germination may be related to the clinical presentation of supernumerary roots. During morpho-differentiation, trauma, infections and other disturbances may affect root form and size in later stages [7]. In this case, the mother of the patient had no history of trauma, substance abuse or any other possible issue that could disturb the growth of the foetus. Primary anteriors are usually single-rooted with a single root canal [8]. When compared to permanent teeth, primary teeth exhibit less anomalies in terms of size and morphology. Only a small percentage of primary teeth have extra roots, and those that do are usually primary molars. Single-rooted primary canines are common. Double-rooted canines are a very uncommon dental abnormality, with only a few occurrences reported since 1941[5,9]. Prevalence of bi-rooted canine in maxilla is higher than in the mandible and it occurs more frequently in male [10,11]. The great majority of issues that arise during pulp therapy are caused by a lack of understanding of the anatomy of the endodontic area. If an extra root or root canal is not found, it is a primary cause of treatment failure. Treatment failure may be increased if all irritants are not completely removed from the pulp space [12]. The main Objective of this case presentation is to increase awareness among dentists about the morphological variations in primary teeth. Proper assessment before endodontic and extraction procedures to avoid future complications related to morphological differences. The Clinician should consider the possibility of bi-rooted primary canines when unusual eruption direction of permanent canines or retained deciduous canines are encountered.¹ Birooted primary canines are difficult to detect with regular intraoral examination and are frequently overlooked by dentists. Extra canals are detected and treated with extra care, including meticulous endodontic investigation, different angle radiography, computer tomography, and magnification with a surgical microscope

[3,13,14]. Although these primary canines may resorb and exfoliate without interfering with the development of permanent teeth, the anomaly should be reported to the parents if it is noticed. During exodontic operations, the physician should ensure that the permanent tooth's crown is not stuck in the inter-radicular area of the primary tooth, since this could result in the permanent tooth being accidentally removed. This anomaly should be kept in mind before extracting a primary canine, and radiographs should be obtained on a regular basis before extraction [4].

4. CONCLUSION

Clinician must have thorough knowledge about tooth morphology. Morphological variations in tooth may affect the success of endodontic therapy, extraction and interfere with the eruption of permanent tooth.

CONSENT

Written and oral informed consent was obtained from parents of the patient included in the study.

ETHICAL APPROVAL

As per international standard or university standard written ethical approval has been collected and preserved by the author(s).

DATA AND MATERIAL AVAILABILITY

All data associated with this study are present in the paper.

COMPETING INTERESTS

Authors have declared that no competing interests exist.

REFERENCES

1. Ashraf A, Juneja A, Sultan A, Siddiqui M. Bilateral, Bi-rooted Primary Maxillary

- Canines: A case Report. *J Radiol Med Imaging*. 2020;3(1):1028.
2. Ayse I. Orhan, Sari S. Double-rooted primary canines: A report of three cases. *J Indian Soc Pedod Prev Dent Dec*. 200;204-208.
 3. Jajoo SS. Primary Maxillary Bilateral Central Incisors with Two Roots. *Int J Clin Pediatr Dent* 2017;10(3):309-312.
 4. Shukla S, Garg A, Garoo A. A Rare Case of Bi-rooted Deciduous Canine. *JCDR*. 2017;3-4.
 5. Guler C. Double-Rooted Maxillary Primary Canine : A Case Report and. 2012;57–9.
 6. Kelly JR. Birooted primary canines. *Oral Surg Oral Med Oral Pathol* 1978; 46:872. Source
 7. Vegh T. Bilateral bifurcation of the maxillary deciduous cuspid. *Roentgen-oddities*. 1975;40(6):817.
 8. Ahmed HMA, Musale PK, El Shahawy OI, Dummer OMH. Application of a new system for classifying tooth , root and canal morphology in the primary dentition. *Int Endod j*. 2020;53(1)27–35.
 9. Ott NW, Ball RN. Birooted primary canines: Report of three cases. *Pediatr Dent* 1996;18:328-30.
 10. Assiry A. Bi-Rooted Primary Maxillary Canines: A Case Report. *J Med Case Reports*. 2019;13: 261.
 11. Mochizuki K, Ohtawa Y, Kubo S, Machida Y, Yakushiji M. Bifurcation, Birooted primary canines: a case report. *Int J Paediatr Dent*. 2001;11:380–1.
 12. Sapna Y, Garg M, Shreya and Chauhan R. Endodontic Management of Mandibular Canine Having Two Roots: A Rare Presentation. *J Dent & Oral Disord*. 2020;6(4):1137.
 13. Nagendra J, Muppalla K, Kavuda K, Punna R, Vanapatla A. Case Report Management of an Unusual Maxillary Canine : A Rare Entity. *Case reports in Dentistry*. 2015;2015:10–3.
 14. Chawla S, Goswami M, Sachdeva P, Walia V. Primary molars with extra root canals – a case series. *J Dent Specialities* 2016; 4(1):55-60.

© 2021 Khakade et al.; This is an Open Access article distributed under the terms of the Creative Commons Attribution License (<http://creativecommons.org/licenses/by/4.0>), which permits unrestricted use, distribution, and reproduction in any medium, provided the original work is properly cited.

Peer-review history:

*The peer review history for this paper can be accessed here:
<https://www.sdiarticle4.com/review-history/75719>*