
THE POSSIBLE PROTECTIVE ROLE OF CABBAGE SEED EXTRACT AGAINST EFFECT OF GAMMA RAYS ON RAT CAUDA EPIDIDYIMIS AND EPIDIDYMAL SPERMS

SAMIA M. ABD EL-WAHAB

Faculty of Science, Zoology Department, Al-Azhar University (For Girls)

Abstract

Cabbage, one of the favorite food in Egypt and many other parts of the world, has been reported for its potent action as antioxidant as well as its content of anticancer compounds. The main objective of this work is to test the antioxidant activity of cabbage seed extract against the effect of gamma rays on the structure of cauda epididymis and epididymal sperm morphology in rat. Silymarin, a plant extract, is a potent antioxidant was used in this study as a comparing reference for the extent of *Brassica* extract activity. Ninety male albino rats were used and divided into six groups: Group 1 (control), group 2 (irradiated control), group 3 (cabbage seed extract), group 4 (cabbage irradiated), group 5 (silymarin extract) and group 6 (silymarin irradiated). The experimental rats were scarificed at 1, 7 and 21 days post- 6 Gy whole body irradiation. Specimens of the cauda epididymidis dissected, smears of semen were collected from them, placed on slides and stained by H and E for studying of spermatozoa. Paraffin sections of cauda epididymidis were prepared and stained by H and E for histological study. Irradiation caused a highly significant decrease in the tubular diameter of the cauda epididymis. It induced degenerative changes in the form of decreased thickness in the lining epithelium of the tubules, congestion of blood vessels, tubular collapse and reduction of luminal spermatozoa with increased abnormal forms as compared to the control. In *Brassica* drenched rats and after irradiation, there was non significant decrease in the diameter of epididymal tubules as compared with the corresponding control. There was a marked improvement in the height of the lining epithelial cells that appeared more or less similar to the control. In most specimens of the epididymidis from silymarin drenched and after one day of irradiation, the tubular epithelium was thin and the lumen was small, irregularly shaped with sticky luminal spermatozoa. However, after three weeks of radiation, sections of the epididymidis showed ameliorative effect of silymarin. In conclusion, *Brassica* seed extract proved to be radioprotective as much or even better than silymarin against radiation effect on epididymis as well as sperms.

Key words: *Brassica oleracia*, Cabbage seed extract, Silymarin, Gamma rays, Sperm abnormalities, Epididymis.

Introduction

The search for the protective and curative value of local plants is needed for its clinical, pharmaceutical and social importance. Cabbage, one of the widely used vegetables in Egypt, has been prescribed by the Arab Scientist, Dawood El-Antaki, as a remedy for several health problems either by using its leaves or seeds. It is cultivated in Egypt and many other parts of the world (Allen and Allen, 2008).

The antioxidant protection of natural plants is a promising therapeutic remedy for free radical pathologies (Halvorsen *et al.*, 2002). Among myriad natural plants, cabbage and other *Brassica* vegetables have been found to have antioxidant, antihyperglycemic (Yokozawa *et al.*, 2003 and Hazem *et al.*, 2008) and anticancer properties (Komatsu *et al.*, 2002, Fowke *et al.*, 2003, Keck & Finley, 2004 and Jon Volden *et al.*, 2008). The principle constituents of cabbage are isothiocyanates (glucosinolate), vitamins A, B, C and anthocyanins (Fowke *et al.*, 2003 and Jagdish Singh *et al.*, 2006), all of which have protective roles against oxidative damage. Anthocyanins, a group of phenolic natural pigments present in cabbage, were found to have the strongest antioxidizing power of 150 flavonoids (Sterling, 2000). Isothiocyanates are anticarcinogenic phytochemicals found in cruciferous vegetables act as substrates and induction for the glutathione *S*-transferases (GSTs) (Steck *et al.*, 2007). The main mechanism proposed for the protective effect of crucifers is the activity of isothiocyanates derived from the metabolism of glucosinolates that accumulate within these vegetables. Isothiocyanates are generated from glucosinolates either by the action of plant thioglucosidases or, if the plant enzymes have been denatured by cooking, by the action of microbial enzymes in the colon (Gasper *et al.*, 2005).

One of the highly prescribed drugs as a hepatoprotective drugs is silymarin. Silymarin is a plant extract which is a potent antioxidant (Wu *et al.*, 2001).

Ionizing radiation injures living cells and destructs the biological systems due to liberation of free radicals (Karbawnik and Reiter, 2000). The degree of injury and destruction is variable among different organs due to their differential radiosensitivity. The chief danger of free radical comes from the damage they can do when they react with important cellular component such as DNA, or the cell membrane. Cells, especially those undergoing division such as spermatogenic cells

may function poorly or die if this occurs. The study of the effect of free radicals and the potency of antioxidants is, therefore, more instructive when performed on the testis (Mattar *et al.*, 1987).

Post-gonad maturation could be an interesting target for therapy especially as it occurs mainly in the epididymal fluid where spermatozoa are far from the complex. In the epididymis, the epithelium removes some testicular factors, takes up materials from the blood, and produces specific compounds, which are useful for sperm maturation and motility (Lenzi *et al.*, 2003). The epididymis is an important organ in the male genital system, which is responsible for the maturation, transportation and storage of spermatozoa. The immature testicular spermatozoa of mammals undergo changes in the morphology, surface properties and biochemical composition during epididymal transit. These changes depend on the epididymal microenvironment, which is formed by the absorptive and secretory functions of the epididymal lining epithelium (Eddy *et al.*, 1985 and Kaur *et al.*, 1992)

The proper function of the epididymis is closely related to its robust physiological metabolism, and free radicals are inevitably produced as a consequence. An excess of free radicals would lead to the oxidative stress of the epididymis, damage the sperm membrane and DNA and seriously affect sperm maturation (Liu and Li, 2009).

The aim of the present study is to test the possible antioxidant action of an alcoholic extract of the seeds of the Egypt-cultivated cabbage (*Brassica oleracea* var. capitata) on the epididymis and epididymal spermatozoa of the rat exposed to radiation. Morphometric and histological studies were used to evaluate its potency. The effectiveness of the extract was evaluated using similar animals drenched a known potent antioxidant plant extract, silymarin extract.

Material And Methods

Experimental animals, feeding and maintenance:

A total of 90 male albino rats weighing 120-180 gm each were used. The animals were housed in especially designed cages, 5 rats per cage, with controlled air, temperature and relative humidity. The animals were fed standard rodent pellets. Food and water were made available *ad-libitum* throughout the whole experimental period.

Gamma –irradiation procedure:

Irradiation process was performed using Gamma Cell-40 achieved by Egypt's National Center for Radiation Research and Technology (NCRRT), Cairo. The gamma cell-40 is a caesium-137 irradiation unit manufactured by Atomic Energy of Canada Limited. The dose rate was 0.62 Gy /min at the time of the experiment.

Cabbage seeds extract:

Cabbage (*Brassica oleracea* var. Capitata) seeds were extracted twice using 95% ethanol. The ethanol was evaporated. The extract was re-dissolved in 3 ml of 95% ethanol and diluted by distilled water to prepare a final extract so that 0.4 ml of final extract in 1% ethanol containing 80 mg of the original seeds. 0.4 ml of the final extract was orally administered by a gastric tube per 100 gm of the body weight of rat for 3 weeks (Mattar, 2008).

Silymarin administration:

Silymarin tablets (70 mg) (Armed Forces Pharmaceutical Factory, Egypt) were crushed and dissolved in distilled water. The drug was administrated orally by gastric tube at a dose of 20 mg/kg body weight/day for 3 weeks. The dose for the rat was calculated according to the Paget's formula on the basis of the human dose (Paget and Barns, 1964).

Experimental design:

The experimental animals were divided into 6 groups. The whole experimental setting was repeated three times as triplica.

Group 1: Untreated control rats.

Group 2: (Irradiated control): animals were exposed to fractionated doses of gamma-irradiation, 2 Gy daily for 3 consecutive days (total of 6 Gy).

Group 3: (Cabbage seed extract): 800 mg extracted seed/kg body weight/day was administrated daily for 3 weeks.

Group 4: (Cabbage irradiated): 800 mg/kg body weight/day of extracted seed was administrated for a period of one week before, during and one week after irradiation.

Group 5: (Silymarin extract): 20 mg/kg body weight silymarin extract was administrated dialy for 3 weeks.

Group 6: (Silymarin irradiated): the animals were orally drenched silymarin extract (20 mg/kg body weight/day) one week before, during and one week after irradiation.

The experimental rats were scarified at 1, 7 and 21 days post-irradiation.

Quantitative morphometric analysis and histological study:

The cauda epididymidis were removed, fixed in neutral buffer formol, processed for paraffin sections and stained with H and E (Humason, 1979). The mean diameter of the cauda epididymal tubules was calculated after measuring of fifty cross sections selected randomly from different experimental and control specimens. Measurements were taken by light microscopy with a precalibrated eye-piece micrometer according to Calvo *et al.* (1999). The percent value of the mean of radiated relative to non radiated group was calculated and graphically presented using Microsoft Excel.

Analysis of spermatozoa abnormalities:

The spermatozoa were obtained by making small cuts in cauda epididymis and vas deferens and placed in saline solution; smears were made on slides, air dried, stained with H and E (Humason, 1979) and microscopically examined. One thousand spermatozoa / rat were examined for shape abnormalities of head and tail and expressed as percentage incidence of abnormal sperms (Narayana *et al.*, 2002). All data were statistically analyzed with student t-test (Snedecor and Cochran, 1980).

Results

Morphometric results

Exposure of rats to whole body γ -irradiation induced significant decrease ($P < 0.01 - 0.001$) in the value of epididymal tubular diameter all over the experimental periods as compared to control group (Table 1 and Fig. 1). The percentage of decrease was -24.83, -15.33 and - 10.08 % for the 1st, 7th and 21st days post-irradiation respectively.

Treatment of irradiated rats with *Brassica* extract exhibited an improvement in the value of the epididymal diameter manifested by the non significant change after 7th and 21st days post-irradiation while very highly significant decrease ($P < 0.001$) in the value of tubular diameter which reached -12.09% was observed after 1st day of irradiation.

Irradiated rats treated with silymarin exhibited non significant change in the mean tubular diameter at 7th and 21st day post-irradiation while induced a significant decrease ($P < 0.05$) in the mean diameter which reached -8.43 % after 1st day of irradiation. These data pointed out to ameliorative effect of silymarin.

From Fig. 1, the value of tubular diameter of the epididymis of all radiated groups was less than control even after 21 days. On the first day, the decrement was highest in radiated control followed by *Brassica* radiated and least in radiated silymarin-treated group. The values for the control radiated group reached a minimum on day one then increased again to reach, on day 21, a value higher than that on day one. In radiated silymarin group, there was a linear increase to reach a value on day 21 near to those of day one. However, in radiated *Brassica* group, there was a linear increase in the value of the diameter of the epididymal tubules over the experimental period.

Table (1): Effect of *Brassica* seed extract or silymarin on cauda epididymal tubular diameter (mm) of γ -irradiated male rats (2x3Gy).

Time groups	One day		7-day		21- day	
	Mean \pm S.E	% change	Mean \pm S.E	% change	Mean \pm S.E	% change
Control group	0.294 \pm 0.008	100.0 %	0.274 \pm 0.007	100.0 %	0.268 \pm 0.009	100.0 %
γ -irradiated group	0.221 \pm 0.005***	75.17%	0.232 \pm 0.008***	84.67%	0.241 \pm 0.005**	89.92%
<i>Brassica oleraceae</i> seed extract group	0.273 \pm 0.006	100.0 %	0.265 \pm 0.008	100.0 %	0.290 \pm 0.009	100.0 %
<i>Brassica oleraceae</i> seed extract + γ -irradiated group	0.240 \pm 0.004***	87.912%	0.252 \pm 0.009	95.09%	0.288 \pm 0.007	99.31%
Silymarin group	0.261 \pm 0.004	100.0 %	0.287 \pm 0.009	100.0 %	0.267 \pm 0.008	100.0 %
Silymarin+ γ -irradiated group	0.239 \pm 0.009*	91.57 %	0.304 \pm 0.006	78.39 %	0.258 \pm 0.012	96.62 %

Each value is the mean of 5 animals \pm S.E.

*, **, ***, is the significant difference when compared at $P < 0.05$, $P < 0.01$, $P < 0.001$ respectively

NS, is non significant.

Percentage of change is in comparison with control.

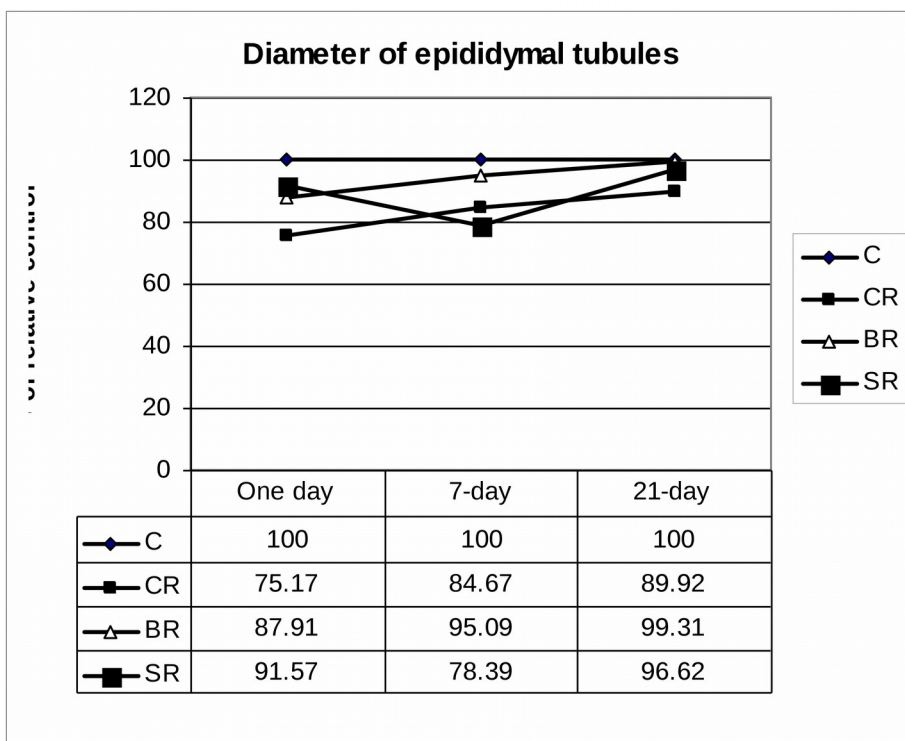


Fig 1: Diameter of epididymal tubules expressed as percent of relative control.
C: Control, CR: Control radiated, BR: Brassica drenched radiated, SR: Silymarin drenched radiated group.

Histopathological results

H and E stain in control animal sections revealed that the epididymal tubules were filled with spermatozoa and separated by intertubular connective tissue (Fig. 2). Sections from animal drenched *Brassica* extract (Fig. 3) showed the epithelium in a healthy form. However, silymarin drenched rats showed reduction of mature spermatozoa (Fig. 4) in the tubular lumen when compared with the epididymis of the control rats (Fig. 2).

1. One day

In control radiated group (Fig. 5), densely stained epithelial cells of boundary tissue and reduction of mature spermatozoa in tubular lumen were evident. Sections from animals exposed to radiation after drenching *Brassica* extract (Fig. 6) presented reduction of spermatozoa in tubular lumen but boundary tissues revealed normal features. Cell injury was more pronounced in radiated silymarin drenched group (Fig. 7) than in the control radiated and radiated *Brassica* drenched group.

2. Seven days

After 7 days of radiation, the tubular epithelium of control radiated group showed mild recovery (Fig. 8). In radiated *Brassica* drenched rat (Fig. 9), wide intertubular space was evident and more pronounced in radiated silymarin-drenched animals (Fig. 10). Fragmented stereocilia and cellular debris were also noticed in radiated silymarin-drenched animals (Fig. 10).

3. 21 days

After 21 days of radiation in the control radiated group (Fig. 11), there was an apparent shrinkage of epithelial cells with absence of stereocilia and reduction of luminal sperms. Application of *Brassica* extract before radiation showed normal appearance of epithelial cell lining (Fig. 12). In silymarin drenched radiated group (Fig. 13), protection was more evident after 21 days of radiation. Sperms appeared healthy.

In section of control group, epithelial lining of the epididymis showed both principal and basal cells (Fig. 14). The principal cells were columnar and exhibited apical stereocilia. Their nuclei were seen in the basal part of the cells with prominent nucleoli. The basal cells were oval or triangular cells scattered between the basal parts of the principal cells.

Some tubules of control radiated group revealed an apparent decrease in the height of their lining epithelium with loss of their luminal margin of stereocilia (Fig. 15) in comparison to the control (Fig. 14). Application of *Brassica* extract before radiation showed that the epididymal tubular epithelium having nearly the same height and intact stereocilia (Fig. 16) as in control group.

Fig. 2: A photomicrograph of cauda epididymal tubules of control rat showing normal appearance of the epithelium (arrow), great concentration of sperms in the lumen (L) and separated with intertubular connective tissue (Ct). (H&E X200).

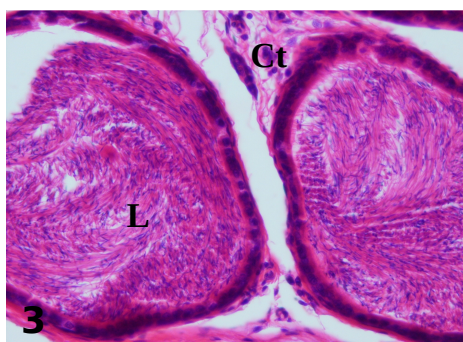
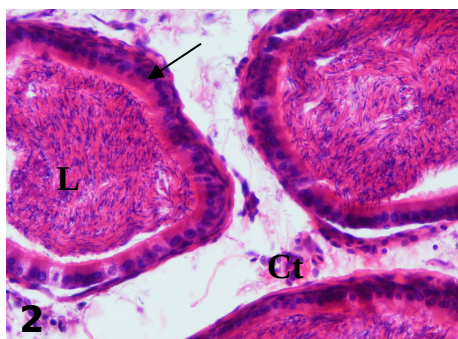
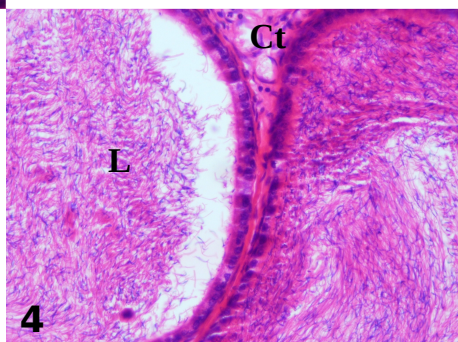


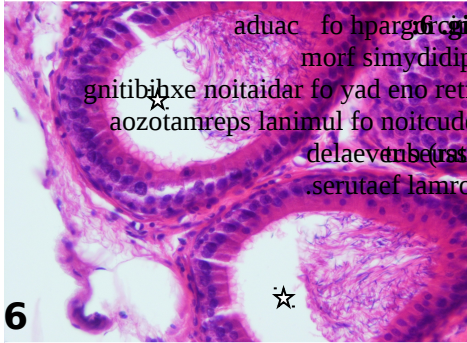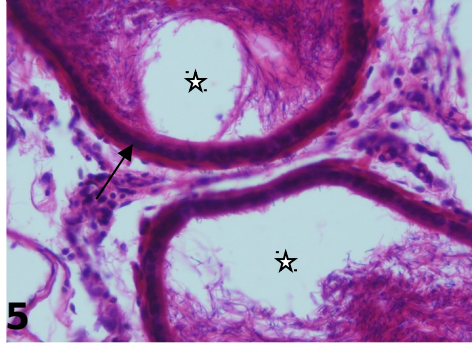
Fig. 3: A photomicrograph of cauda epididymis from *Brassica* drenched rat displaying no observed alteration in the histoarchitecture of cauda epididymis (H&E X200).

Fig. 4: A photomicrograph of cauda epididymis from silymarin drenched rat exhibiting reduction of mature spermatozoa in tubular lumen (L) (H&E X200).



5
 e fo hparg
 morf simydidipe
 noitaidar fo yad
 ailehtipe deniats
 mul fo noitcuder
 .(002X E&H)

dna (worra)
 .(rats



6
 aduac fo hparg
 morf simydidipe
 gnitibixe noitaidar fo yad eno retfa
 aozotamreps lanimul fo noitcuder
 delaevne (uss) yradnuob
 .serutae lamron .(002X E&H)

acissar Behcnerd

7
 e fo hparg
 morf simydidipe
 yad eno retfa tar
 t niht gniyalpsid
 , (slawimul ykcits aozotamreps
 morf dna (worra)
 ussit evitcennoc

owt) muilehtipe

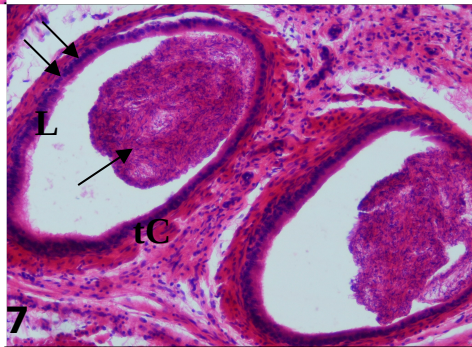


Fig. 8: A photomicrograph of cauda epididymis from control rat after one week of radiation showing less densely stained epithelial cells (arrow) and normal distribution of sperms in the lumen (L). (H&E X200)

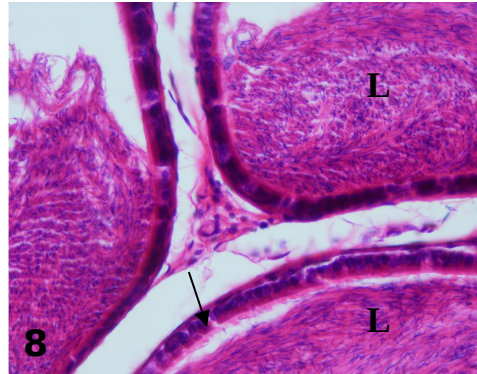


Fig. 9: A photomicrograph of cauda epididymis from *Brassica* drenched rat after one week of radiation exhibiting more or less normal tubules with wide intertubular space (arrow). (H&E X100).

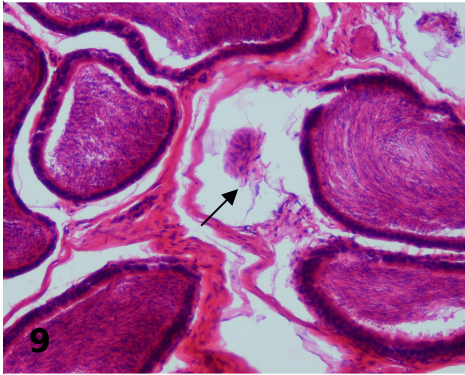


Fig. 10 : A photomicrograph of cauda epididymal tubules from silymarin drenched rat after one week of radiation showing densely stained epithelial cells (two arrows), prominent intertubular connective tissue (Ct) with congested blood vessels (arrow) and absence of mature spermatozoa (star) in lumen of some tubules, replaced by fragmented stereocilia and cellular debris (H&E X200).

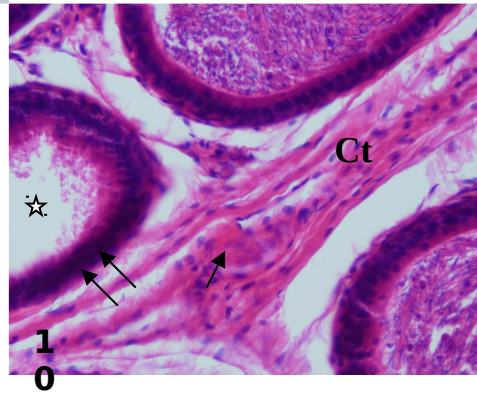


Fig. 11: A photomicrograph of cauda epididymal tubules from rat after three weeks of radiation showing an apparent decrease in their epithelial height, absence of stereocilia (long arrow) and reduction of luminal sperms (star). Prominent muscle cells surrounding the tubules (short arrows). (H&E X200).

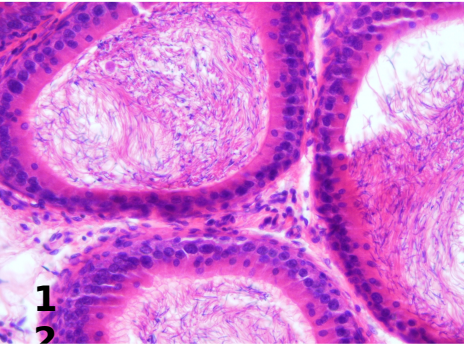
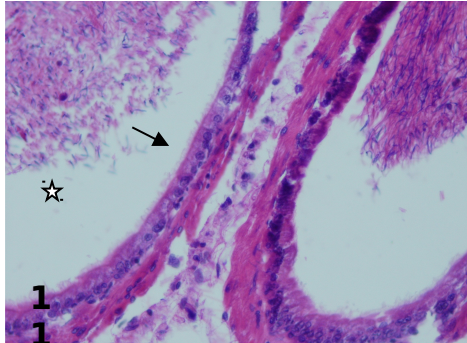


Fig. 12: A photomicrograph of cauda epididymis from *Brassica* drenched rat after three weeks of radiation showing ameliorative effect of *Brassica* extract on the architecture of the epididymal tissue. (H&E X200)

Fig. 13: A photomicrograph of cauda epididymis from silymarin drenched rat after three weeks of radiation exhibiting the ameliorative effect of silymarin. (H&E X200)

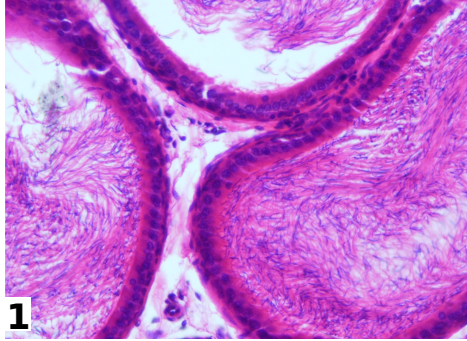


Fig. 14: A photomicrograph of cauda epididymal tubule from control rat showing tall columnar principal cells (P) with large nuclei (N) and apical stereocilia (arrow), basal cells (B), smooth muscle cells (M) and luminal spermatozoa (S). (H&E. X 1000)

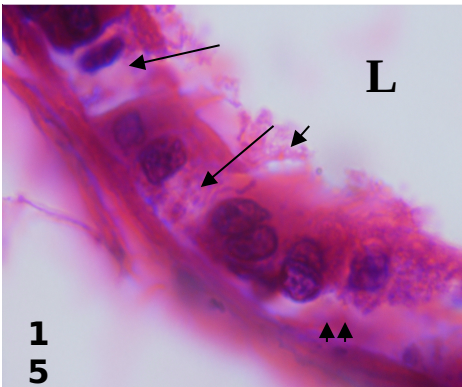
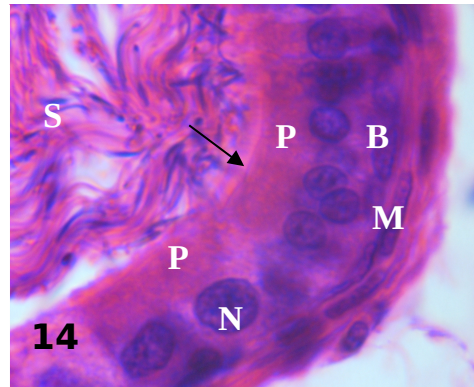
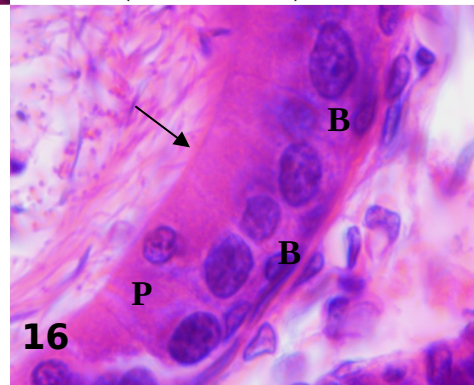


Fig. 15: A photomicrograph of cauda epididymal tubule from rat after 21 day of radiation exhibiting an apparent decrease in its epithelial height with frothy appearance of clear cells (long arrows) and absence of basal cells (two arrow heads). Absence of sperms within the lumen (L) and fragmented stereocilia (short arrow) are also shown. (H&E. X 1000).

Fig. 16: A photomicrograph of cauda epididymal tubule from extract drenched rat after 21 days of radiation showing principal cells (P) with faintly stained cytoplasm and intact stereocilia (arrow). (H&E. X 1000).



Sperm morphological abnormalities

Table (2) compare between the average values of sperm shape abnormalities of rats treated with *Brassica* extract or silymarin and / or exposed to fractionated doses of γ -radiation at different intervals (1, 7 and 21 days post-irradiation).

Exposure of rats to whole body γ -radiation induced a significant increase ($P < 0.05 - 0.001$) in sperm shape abnormalities all over the experimental periods as compared to control group. The percent of abnormal sperms was 8.98, 6.96 and 6.02% for the 1st, 7th and 21st days post-irradiation respectively.

Treatment of irradiated rats with *Brassica* extract reduced the percentage of sperm abnormalities manifested by the non significant change all over the experimental periods as compared to *Brassica* drenched group. The percent of abnormal sperms was 7.14, 5.87 and 4.4% for the 1st, 7th and 21st days post-irradiation respectively.

Irradiated rats treated with silymarin exhibited a very highly significant increase ($P < 0.001$) in sperm abnormalities after one day of irradiation while non significant change in sperm abnormalities was observed after 7th and 21st days of irradiation. These data revealed the ameliorative effect of silymarin.

The average frequencies of different types of sperm deformities namely head deformities, tail deformities and both head and tail deformities in sperms of rats from the different groups are given in Table (3).

Comparing with the control, there was a highly significant increase ($P < 0.01$) in the number of sperm head abnormalities after 21 days of irradiation. They were in the form of coiling tip, flexed head, lack of hook and amorphous head (Fig. 17 B, C, D and E respectively). However, the mean number of sperm tail abnormalities showed highly significant increase ($P < 0.01$) at 1st and 21st days post-irradiation. They were in the form of bent, coiling, detached tail from the head and zigzage tail [Fig. 18 A, (B & C), E and F respectively].

Treatment of irradiated rats with *Brassica* extract showed a highly significant increase ($P < 0.01$) in the mean number of head abnormalities after day one of irradiation. They were in the form of lack of hook (Fig. 17 D). However, there was a non significant difference in different abnormalities after 7th and 21st day of irradiation as compared to the corresponding control. These data revealed the ameliorative effect of *Brassica*.

Irradiated rats treated with silymarin exhibited a very highly significant increase ($P < 0.001$) in the number of tail abnormalities as compared to the corresponding control. They were in the form of coiling tail (Fig. 18 B and C). However, there was a non significant change in the mean number of different abnormalities after 7th and 21st day post-irradiation. These data reflected the ameliorative effect of silymarin.

In the present examination, deformities involving the combined head and tail showed non significant change all over the experimental periods as compared to control group. They were in the form of triangular head and folded tail, flexed head and spiral tail, coiled flagellum and detached head, amorphous head and fusion tails, flexed head and bent tail, and amorphous head and thick flagellum with bent tail (Fig. 19 A – F respectively)

Table (2): Average values of sperm shape abnormalities in control and treated rats.

Groups	Control			γ -irradiated			<i>Brassica oleraceae</i> seed extract			<i>Brassica oleraceae</i> seed extract + γ -irradiation			Silymarin			Silymarin + γ -irradiation		
	No. of normal sperms	No. of abnormal sperms	% abnormality	No. of normal sperms	No. of abnormal sperms	% abnormality	No. of normal sperms	No. of abnormal sperms	% abnormality	No. of normal sperms	No. of abnormal sperms	% abnormality	No. of normal sperms	No. of abnormal sperms	% abnormality			
One day	975.34 ± 2.08	24.66 ± 2.08	2.46	910.2 ± 12.41	89.8*** ± 12.41	8.98	957.8 ± 21.64	42.2 ± 21.64	4.22	928.6 ± 8.68	71.4 ± 8.68	7.14	960 ± 6.32	40 ± 6.32	4	917 ± 5.73	83*** ± 5.73	8.3
7-day	964.66 ± 2.31	35.34 ± 2.31	3.53	930.4 ± 16.30	69.6* ± 16.30	6.96	952 ± 18.01	48 ± 18.01	4.8	941.34 ± 28.08	58.66 ± 28.08	5.87	948.8 ± 16.24	51 ± 16.24	5.12	929.6 ± 15.14	70.4 ± 15.14	7.04
21-day	974.2 ± 1.61	25.8 ± 1.61	2.58	939.8 ± 9.49	60.2** ± 9.49	6.02	959.8 ± 16.05	40.2 ± 16.05	4.02	956 ± 9.74	44 ± 9.74	4.4	965.2 ± 4.74	34.8 ± 4.74	3.48	948 ± 19.51	52 ± 19.51	5.2

Each value is the mean of 5 animals \pm S.E.

* P < 0.05; ** p < 0.01, *** P < 0.001 significantly different from control.

Table (3): Average values of different types of sperm deformities in control and treated rats.

Groups	Types of abnormally shaped sperms / 1000																		
	Control			γ- irradiated			<i>Brassica oleraceae</i> seed extract			<i>Brassica oleraceae</i> seed extract + γ- irradiation			Silymarin			Silymarin + γ- irradiation			
	Head Deformity	Tail Deformity	Head And Tail Deformity	Head Deformity	Tail Deformity	Head And Tail Deformity	Head Deformity	Tail Deformity	Head And Tail Deformity	Head Deformity	Tail Deformity	Head And Tail Deformity	Head Deformity	Tail Deformity	Head And Tail Deformity	Head Deformity	Tail Deformity	Head And Tail Deformity	
Time	16.66 ± 2.16	4.0 ± 6.52	4.0 ± 1.21	14.4 ± 2.85	68.8*** ± 11.65	6.6 ± 1.11	7.6 ± 2.96	34.6 ± 21.46	0.00 ± 0.00	21.6*** ± 2.21	45.8 ± 7.89	4.00 ± 1.87	24.4 ± 2.96	10.8 ± 3.55	4.8 ± 1.65	20.6 ± 3.72	50.6*** ± 2.35	6.58 ± 2.94	
One day	8 ± 2.71	23.34 ± 9.9	4.0 ± 1.05	12.6 ± 1.43	52 ± 16.42	5 ± 1.44	9 ± 1.74	33 ± 15.02	6 ± 2.65	7.8 ± 1.50	44.46 ± 12.00	6.4 ± 2.67	12.6 ± 5.34	36 ± 9.97	2.4 ± 1.73	19.2 ± 2.08	46 ± 13.60	5.2 ± 2.14	
7-day	6.2 ± 2.55	15 ± 2.03	4.6 ± 1.31	25.2*** ± 4.29	35*** ± 5.59	0.00 ± 0.00	9.2 ± 6.23	27 ± 9.45	4 ± 1.01	10 ± 4.05	30 ± 6.34	4 ± 1.12	19.2 ± 4.25	13.2 ± 1.65	2.4 ± 1.04	10 ± 1.13	38.8 ± 19.02	3.2 ± 1.10	
21-day																			

Each value is the mean of 5 animals ± S.E.

* P < 0.05; ** p < 0.01, *** P < 0.001 significantly different from control.

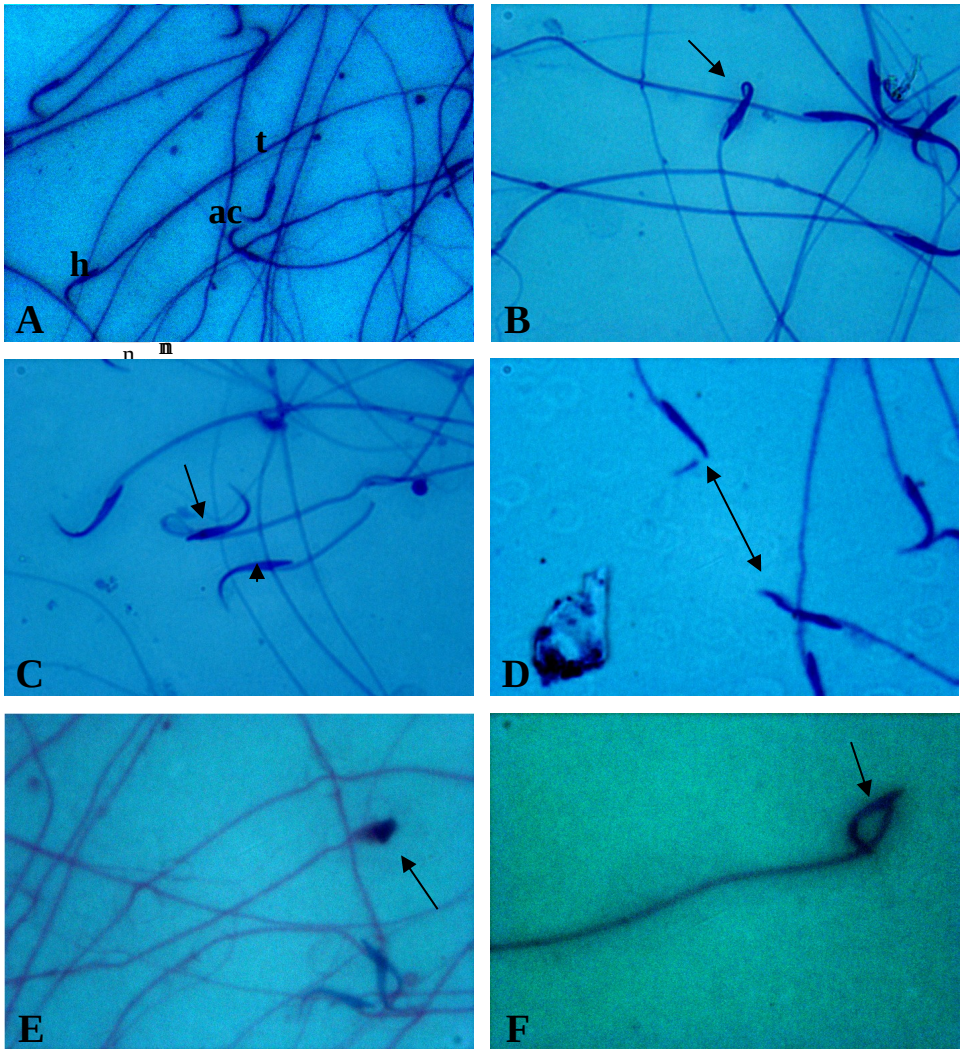


Fig 17: A: Photomicrographs showing H&E stained epididymal sperm abnormalities in head in irradiated rat. A: Spermatozoa from rat epididymis with characteristic hooks and a single tail (h: Head; ac: Acrosome; t: Tail). B: Sperm with coiling tip (X 1000). C: Sperm with flexed head, tip of the head facing towards the flagellum (long arrow) and detached sperm head with a portion of middle piece of tail (short arrow). (X 1000). D: Lack of hook (arrow) (X 1000). E: Sperm with triangular and amorphous head (X 1000). F: Sperm with head flexed, tip of the head facing inwards the flagellum (X1000). Magnification, X 400 (A) and X 1000 (B-F).

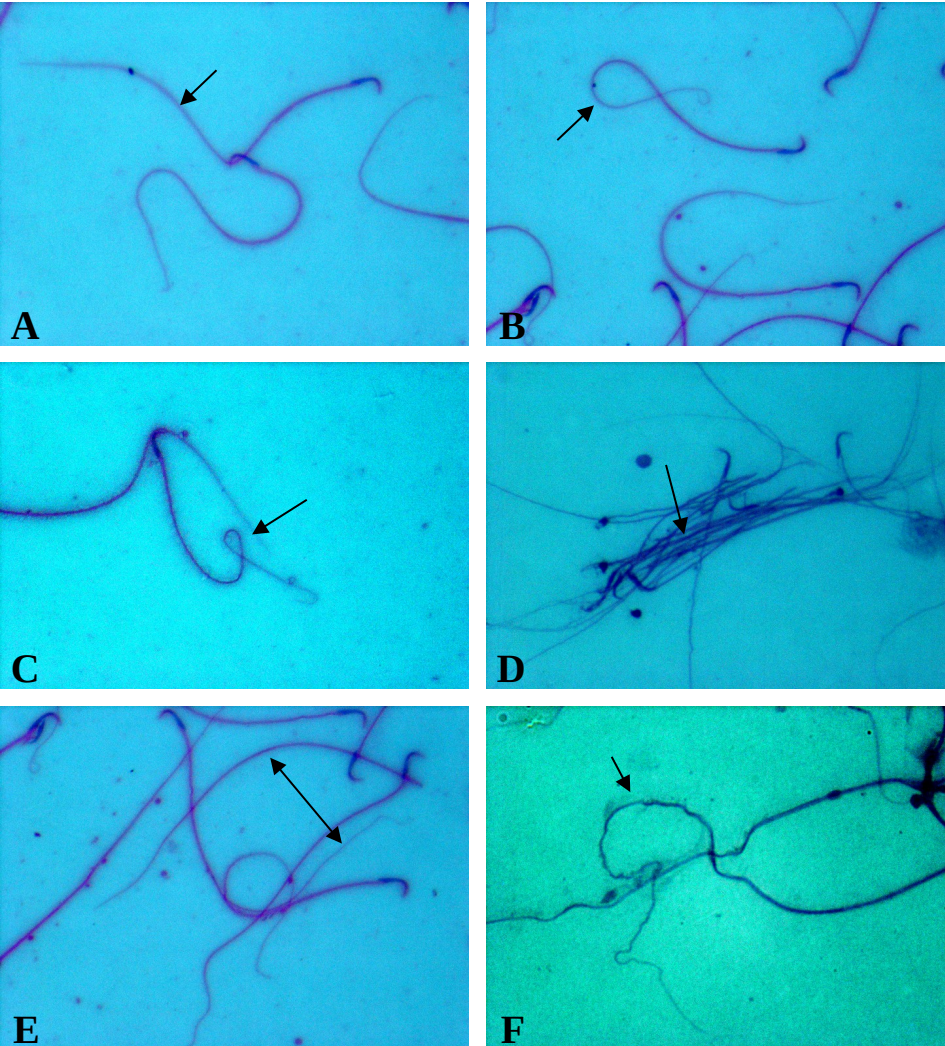


Fig 18: Photomicrographs showing H&E stained epididymal sperm abnormalities in tail in irradiated rat. **A:** Bent tail. **B:** Coiling tail, tip of the tail facing inwards the head. **C:** Coiling tail, tip of the tail facing towards the head. **D:** Fussion sperms. **E:** Detached tails from the heads. **F:** Zigzag tail. X400 (A-E) and X1000 (F).

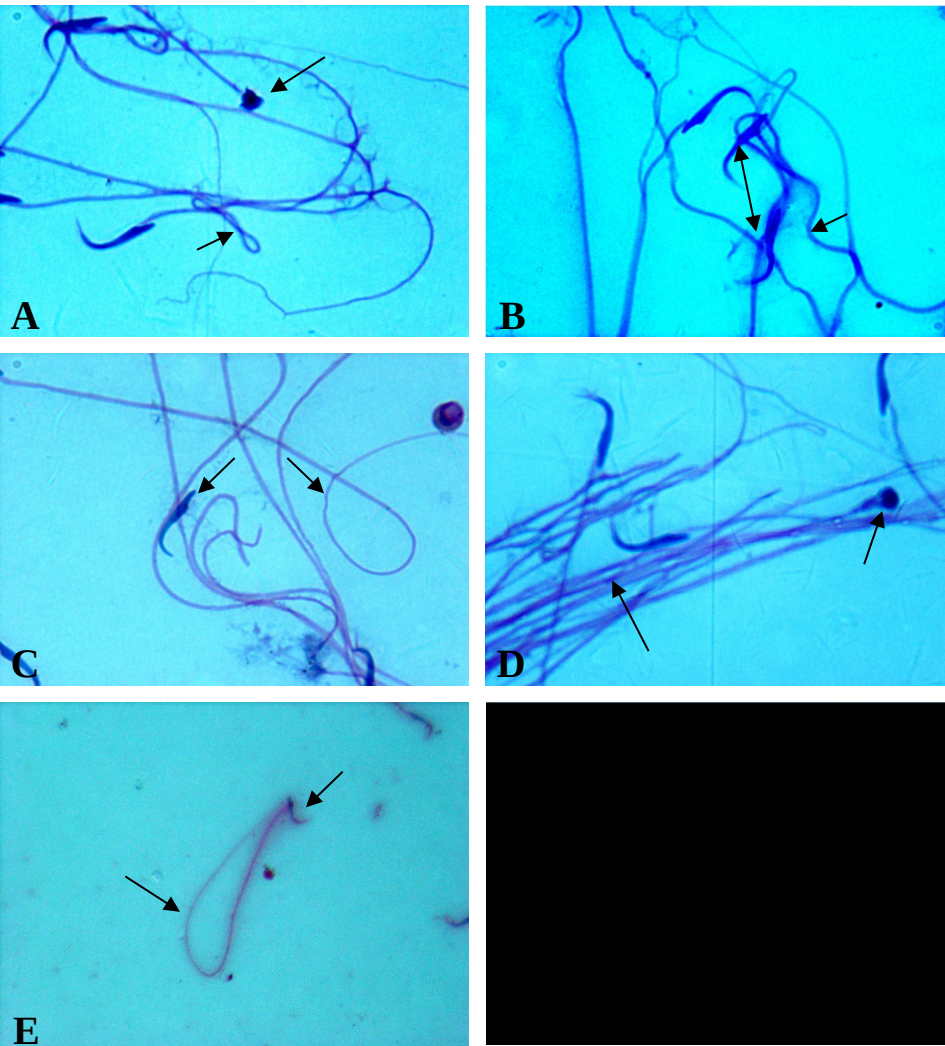


Fig 19: Photomicrographs showing H&E stained epididymal sperm abnormalities in both tail and head in irradiated rat. **A:** Sperm with triangular head (long arrow) and folded tail (short arrows) (X1000). **B:** Flexed head and spiral tail. **C:** Sperm with coiled flagellum and a detached head (X1000). **D:** Sperm with amorphous head (arrow), thick mid-piece and fusion tails (X 1000). **E:** Sperm with flexed head, tip of the head facing towards the flagellum and bent tail (X400). **F:** Sperm with amorphous head and thick flagellum with bent tail. X 1000 (A–D) and X 400 (E, F).

Discussion

In the present study, reduction in the epididymal tubular diameter was accompanied by prominent intertubular connective tissue with congested blood vessels and, in some animals, cellular debris was observed in the lumen of epididymal tubules from silymarin irradiated rats after 7 days of irradiation. These changes were in accordance with Kaur *et al.* (1992) who described these as degenerative changes that occurred as a consequence of androgen deprivation due to competitive inhibition of androgens at the receptor level and so it reflected the higher threshold requirement of cauda epididymis to androgen. In addition, Abdelhafez (2008) stated that, the cross sectional area of seminiferous tubules reached its lowest value in control radiated group and Kumar *et al.* (2007) found that the least testicular weight was on day 7 and 14 after 8 Gy whole body irradiation. Changes in the histology of the epididymis were possibly the consequence of the loss of spermatozoa from the tubular lumen, which can disrupt the absorption and secretory processes of the epithelial lining (Grima *et al.*, 2001). The decrease in the size of the epididymal tubules may also be governed in part by a reduction of the volume and pressure normally exerted upon the tubules by luminal fluids and spermatozoa derived from the testis (Hermo and Papp, 1996).

Tubular diameter on 1st, 7th and 21st day post-irradiation was found to be reduced in irradiated group, but *Brassica* drenched before irradiation increased the diameter on the 21st day post-irradiation comparable to the untreated control.

The prominent intertubular connective tissue in this work might be a compensatory mechanism to the decrease in the diameter of the tubules. The interstitial blood vessels showed congestion which was explained by Huether and McCance (2000) as due to the decrease in the ratio of oxygen supply to oxygen need that results in an increase in the rate of adenosine production (a breakdown product of ATP). This in turn elicited increased blood flow in order to restore this ratio to the equilibrium value.

The collapse of the epididymal tubules was more evident in irradiated control followed by silymarin irradiated and least in the *Brassica* extract drenched irradiated group. [Abdelhafez \(2008\)](#) reported that the interstitial PAS positive glycosaminoglycans is highest in control radiated followed by silymarin drenched while it was slightly higher than control in *Brassica* drenched groups. As

glycosaminoglycans is a product of fibroblasts (Junqueira *et al.*, 1995) it indicated that, the extent of their activity in formation of interstitial components to extend areas resulting from tubular collapse.

Stickness of spermatozoa in lumen of tubules in silymarin drenched animals and after one day of irradiation was observed. This may be due to the principal cell injury, which was proved to secrete immobilin, a glycoprotein used to immobilize the sperms in the epididymis (Hermo *et al.*, 1992; Bakry and Saad, 1993).

The histopathological results of this work revealed presence of damaged sperms in the lumen of the epididymis tubules in silymarin drenched animals after 7 days of radiation. On the other hand, sperms were absent from the lumen of some tubules and replaced by fragmented stereocilia and cellular debris. The lack of sperms may be due to a decrease in their production by the testis (azoospermia) as previously explained by Dhar *et al.* (1982). Moor and Bedford (1979) found that the rat spermatozoa were highly dependent on the high androgen environment of the normal epididymis for their maturation and survival and die within six days after androgenic support of the epididymal epithelium is withdrawn. In the present study, the luminal debris may be due to exfoliation or sloughing of the degenerating cells.

Oxidative destruction of polyunsaturated fatty acids has been shown to be extremely damaging to epididymal membranes, since it proceeds as a self-perpetuating chain reaction (Sevanian and Ursini, 2000). Cell injury results primarily from membrane destruction due to lipid peroxidation, which results from the action of free radicals liberated by radiation (Walden and Farzaneh, 1990). Collapse of seminiferous tubules, was measured by biochemical estimation of malondialdehyde (MDA) which is a product of lipid peroxidation (Sorensen *et al.*, 2001). [Abdelhafez \(2008\)](#) found that both plasma and testicular MDA in radiated group were higher than the non radiated group after 24 hours post irradiation. The value of MDA in testis was less in *Brassica* radiated group than in silymarin radiated group which means higher protective action of *Brassica* exceeding than of silymarin. *Brassica* and silymarin protection against radiation seems to be for both spermatogenic cells and Sertoli cells. The most susceptible organoids for lipid peroxidation are mitochondria (Kumar *et al.*, 2005).

Radiation exposure enhanced sperm abnormalities. The pre-irradiation treatment with *Brassica* reduced the frequency of abnormal sperms observed 21 days after the treatment. Previous results indicated that incubation of ascorbic acid (one of the constituents of cabbage) with the environmental contaminant, methoxychlor, protects epididymal sperm of goats from oxidative damage (Gangadharan *et al.*, 2001). In the present study co-administration of *Brassica* seed extract may reverse the oxidative stress induced by irradiation in epididymal sperm and epididymis of rats.

Decrease in sperm density in the epididymal tubules post-irradiation was reported in the present results. This may be due to an effect on efferent ductules and fluid reabsorption, causing the sperm to be diluted in the cauda epididymis (D'Souza, 2004). Furthermore, radiation exposure may indicate an interference with spermatogenesis and subsequently the sperm counts (Samanta and Goel, 2002). Whereas the sperm count in the epididymis is known to be one of the most sensitive tests for evaluating spermatogenesis, as it gives the result of all the stages of meiosis, spermiogenesis, and transition in the epididymis ([Meistrich, 1989](#)).

The common sperm anomalies observed post-irradiation were abnormal hook, flexed head, coiled flagellar end, amorphous head and zigzag tail. Such findings were corroborated by Bashandy (1992), where irradiation has been reported to increase the frequency of sperm morphology abnormalities. The presence of abnormal sperm indicated that the spermatogenesis process may have been affected ([Krzanowska, 1995 and Abdelhafez, 2008](#)), where the morphology of cauda epididymal spermatozoa is the end result of a highly complex process of cellular modifications that occurs during spermatogenesis (Auger *et al.*, 2001). The reduction of epididymal sperm and increase incidence of abnormal spermatozoa caused by irradiation could be the result of impaired cell division and cytoskeletal-dependent processes during conversion of pachytene / leptotene spermatocytes to sperms. Moreover, irradiation have been reported to cause DNA breaks by means of free-radical mediated reactions ([Shi et al., 1996 and Abdelhafez, 2008](#)). Thus, DNA damage may also be responsible for the increased percentage of abnormal sperm forms.

The breaking away of head from flagellum and flexion of head of the sperm appeared in the present results may be due to impact of irradiation at the neck or connecting piece of flagellum. The main components of the connecting piece are the basal plate, capitulum and segmented columns (Sarathechandiran *et al.*, 2007). Thus, it could be perceived that the irradiation disrupts this protein also as much as disrupting tubulin, causing the breaking away of the head from the flagellum. A less impact at this point would cause the head to flex, or flexion itself may be a step towards the breaking away (Nakai *et al.*, 1992). Coily tail of the sperm suggested some biochemical changes in the sperm surface (Chandiran *et al.*, 2008).

The present study indicated that cabbage seed extract drenched resulted in amelioration of the cauda epididymal spermatozoa from the radiation effect, where the group given *Brassica* before irradiation recorded a decrease in the percentage of abnormal sperms. This suggested that the presence of *Brassica* before irradiation efficiently reduced the damage and enhanced proliferation and differentiation of stem cells of testis. On the other hand, the possible mechanism by which *Brassica* seed extract has reduced sperm abnormalities, might be due to the antioxidant action (Fowke *et al.*, 2003 and Jagdish Singh *et al.*, 2006) which prevents oxidation of cellular constituents (Jon-Volden *et al.*, 2008 and [Abdelhafez, 2008](#)). This extract contains anthocyanin pigments that are described as free-radical scavenging and antioxidant agents that may modulate the oxidative stress caused by irradiation-induced generation free radicals (Jagdish Singh *et al.*, 2006).

The epididymis and spermatozoa are highly rich in polyunsaturated fatty acids and thus susceptible to damages induced by reactive oxygen species (ROS). To counteract the effects of ROS, the epididymis and spermatozoa are equipped with antioxidant defence systems, namely, superoxide dismutase, catalase, glutathione peroxidase and glutathione reductase. On the other hand, epididymal antioxidant enzymes protect spermatozoa from oxidative damage in the epididymal lumen (Zubkova and Robair, 2004). Increased lipid peroxidation due to irradiation may indicate an increased generation of free oxygen radicals in the epididymis, which has been associated with sperm mid-piece abnormalities (Chitra *et al.*, 2003). It was reported that, there was a close correlation between depletion of antioxidant enzymes and increase in lipid peroxidation (Devi and Ganasoundaria, 1999). However, while *Brassica* radiated group seemed to be more capable of antioxidant

restoration in testicular cells than radiated silymarin, its protection against lipid peroxidation was more limited ([Abdelhafez, 2008](#)). Vang *et al.* (1999) reported that dietary broccoli significantly increased the activities of GSTs in rat testes. Another explanation could be that: as prevention of lipid peroxidation needs lipophilic antioxidants, the effective antioxidants in silymarin are lipophilic while those in *Brassica* are hydrophilic (Mattar *et al.*, 1987).

In *Brassica* drenched radiated group, signs of recovery were more evident after 21 days of radiation.

Generally, signs of recovery could be detected after 21 days of radiation. The tubular diameter of control radiated group reached about 89.92% of the control non radiated group. It was slightly less in silymarin radiated group than in control radiated and *Brassica* drenched radiated groups.

In the present study, irradiation induced a complete degeneration of epididymal epithelium with reduction of spermatozoa in the tubular lumen, which may be due to a decrease in serum testosterone, FSH and LH levels (Chitra *et al.*, 2003 and Abdelhafez, 2008) or a reduction in 5 α -reductase activity in the epididymis (Chitra *et al.*, 2003) or antiandrogenic effect as the weights of accessory organs were reduced (Vijaykumar *et al.*, 2004; Chandra *et al.*, 2007; Hamzeh and Robair, 2009). The decrease in the percentage of FSH as a result of radiation may be due to the effect of radiation on pituitary gland and may act as a factor in decrogenesis (Plant and Marshall, 2001). This may also be due to decreased activity of Sertoli cells (Christiansen *et al.*, 2002). Abdelhafez (2008) noticed that the percentage of testosterone in radiated control reached a maximum on day 7. This may be an indicator of Leydig cell activation (Jabbour, 2006). In *Brassica* radiated group, testosterone was elevated indicated the recovery of interstitial Leydig cells (Abdelhafez, 2008), where it was established that testosterone plays a crucial role in maintaining the integrity of epididymal structure and function (Chandra *et al.*, 2007). [Hamzeh](#) and [Robaire](#) (2009) observed that, the epithelial cell proliferation decreased after testosterone withdrawal and increased following testosterone administration, where the principal cells were the major cell types that responded to testosterone after regression. These observations demonstrated that, the mammalian epididymis providing insight in the role of androgen in restoration and maintenance of the architecture of the epididymis ([Hamzeh](#) and [Robaire](#), 2009).

This study confirms that irradiation induces the shrinkage and atrophy of cauda epididymal tubules with increase in sperm abnormalities in rats. Silymarin, a plant extract was used as a drug for its antioxidant properties and as a comparing reference for the extent of *Brassica* seed extract activity. In conclusion, *Brassica* seed extract proved to be radioprotective as much or even better than silymarin.

References

1. ABDELHAFEZ HM (2008): Effect of cabbage *Brassica oleraceae* (var. capitata) seed extract and gamma rays on rat testis. M. Sc. Thesis, Faculty of Science, Al-Azhar Univ. for Girls.
2. ALLEN Z AND ALLEN R (2008): Cabbage takes a roller coaster ride through the centuries. Los Angeles Vegetarian Web Magazine,10 (8)
<http://www.vegparadise.com/highestperch33.html>.
3. [AUGER J](#), [EUSTACHE F](#), [ANDERSEN AG](#), [IRVINE DS](#), [JORGENSEN N](#), [SKAKKEBAEK NE](#), [SUOMINEN J](#), [TOPPARI J](#), [VIERULA M](#) AND [JOUANNET P](#) (2001): Sperm morphological defects related to environment, lifestyle and medical history of 1001 male partners of pregnant women from four European cities. [Hum. Reprod.](#), 16 (12): 2710-2717.
4. BAKRY M AND SAAD MF (1993): Fine structure of the ductus epididymis of adult albino rat. Egypt. J. Histol. 16 (2): 467-476.
5. BASHANDY SA (1992): Biological effect of vicin, radiation and antioxidants on gonadal activity of male albino rat. Ph. D. Thesis, Faculty of Science, Al-Azhar University.
6. CALVO A, PASTOR LM, MARTINEZ E, VAZQUEZ JM AND ROCA J (1999): Age-related changes in the hamster epididymis. *Ana. Rec.*, 256: 335-346.
7. CHANDIRAN S, VRUSHABENDRA SWAMY BM, PAVAN KUMAR B, NARAYANAN V, VINOTH KUMAR S, MURALIDHARAN P AND KARIMULLA SK (2008): Studies on spermatotoxic effect of ethanolic extract of root of "*Caesalpinia digyna* (Rottler)". *Pharmacologyonline*, 2: 790-795.
8. CHANDRA AK, GHOSH R, CHATTERJEE A AND SARKAR M (2007): Effects of vanadate on male rat reproductive tract histology, oxidative stress markers and androgenic enzyme activities. *J. Inorg. Biochem.*, 101(6): 944-956.
9. CHITRA KC, RAMACHANDRA RAO K, AND MATHUR PP (2003): Effect of bisphenol A and co-administration of bisphenol A and vitamin C on epididymis of adult rats: A histological and biochemical study. *Asian J. Androl.*, 5: 203-208.
10. CHRISTIANSEN, PAM, ANDERSSON NE, SKAKKEBAEK AND JUUL A (2002): Serum inhibin B, FSH, LH and testosterone levels before and after human chorionic

- gonadotropin stimulation in prepubertal boys with cryptorchidism. *Eur. J. Endocrinol.*, 147 (1): 95-101.
11. DEVI PU AND GANASOUNDARIA A (1999): Modulation of glutathione and antioxidant enzymes by *Ocimum sanctum* and its role in protection against radiation injury. *Indian J. Exp. Biol.*, 37: 26-35.
 12. DHAR JD, SRIVASTAVA SR AND SELLY BS (1982): Flutamide as an androgen antagonist on epididymal function in the rat. *Andrologia*, 14 (1): 55-61.
 13. D'SOUZA UJA (2004): Effect of tamoxifen on spermatogenesis and tubular morphology in rats. *Asian J. Androl.*, 6: 223-226.
 14. EDDY EM, VERNON RB, MUELLER LH, MAHNEL AC AND FENDERSON BA (1985): Immunodissection of sperm surface modifications during epididymal maturation. *Am. J. Anat.*, 174: 225-237.
 15. FOWKE JH, CHUNG FL, JIN F, QI D, CAI Q AND CONAWAY C (2003): Urinary isothiocyanate level, *Brassica*, and human breast cancer. *Cancer Res.*, 63: 3980–3986.
 16. GANGADHARAN B, MURUGAN MA AND MATHUR PP (2001): Effect of methoxychlor on antioxidant system of goat epididymal sperm in vitro. *Asian J. Androl.*, 3: 285-288.
 17. GASPER AV, AL-JANOBI A, SMITH AJ, BACON JR, FORTUN P, ATHERTON C, TAYLOR MA, HAWKEY CJ, BARRETT DA AND MITHEN RF (2005): Glutathione S-transferase M1 polymorphism and metabolism of sulforaphane from standard and high-glucosinolate broccoli. *Am. J. Clin. Nutr.*, 82: 1283–1291.
 18. GRIMA J, SILVESTRINI B AND YAN CHENG C (2001): Reversible Inhibition of Spermatogenesis in Rats Using a New Male Contraceptive, 1-(2, 4-Dichlorobenzyl)-Indazole-3-Carbohydrazide. *Biol. Reprod.*, 64: 1500-1508.
 19. HALVORSEN BL, HOLTE K, MYHRSTAD MC, BARIKMO I, HVATTUM E AND REMBERG SF (2002): A systematic screening of total antioxidants in dietary plants. *J. Nutr.*, 132: 461–471.
 20. [HAMZEH M](#) AND [ROBAIRE B](#) (2009): Effect of testosterone on epithelial cell proliferation in the regressed rat epididymis. [J. Androl.](#), 30 (2): 200-212.
 21. HAZEM A, KATAYA H AND HAMZA AEA (2008): Red Cabbage (*Brassica oleracea*) Ameliorates Diabetic Nephropathy in Rats Evidence-based Complementary and Alternative Medicine, 5 (3): 281-287.
 22. HERMO L, OKO R AND ROBAIR B (1992): Epithelial cells of the epididymis show regional variations with respect to the secretion and endocytosis of immobilin, as revealed by light and electron microscope immunocytochemistry. *Anat. Rec.*, 232 (20): 202-212.

23. HERMO L AND PAPP S (1996): Effects of ligation, orchidectomy and hypophysectomy on expression of the Yf subunit of GST-P in principal and basal cells of the adult rat epididymis and on basal cell shape and overall arrangement. *Anat. Rec.*, 244: 259–269.
24. HUETHER SE AND MCCANCE KM (2000): *Understanding Pathophysiology*. 2nd ed. Mosby Boston, New York and London. Pp. 446-448.
25. HUMASON GL (1979): *Animal Tissue Techniques*. 2nd ed., Freeman, W. H. and Company, P. 661.
26. JABBOUR SA (2006): Follicle stimulating hormone abnormalities. e.medicine: www.emedicine.com
27. JAGDISH SINGH AK, UPADHYAY A, BAHADUR B, SINGH B, SINGH KP AND MATHURA RAI AK (2006): Antioxidant phytochemicals in cabbage (*Brassica oleracea* L. var. capitata). *Sci. Horticult.*, 108: 233–237.
28. JON VOLDEN J, WICKLUND T, VERKERK R AND DEKKER M (2008): Kinetics of Changes in Glucosinolate Concentrations during Long-Term Cooking of White Cabbage (*Brassica oleracea* L. ssp. capitata f. alba). *J. Agric. Food Chem.*, 56 (6): 2068–2073.
29. JUNQUERIA LC, CARNERIOR J AND KELLEY RO (1995): *Basic Histology*. 9th ed. Chapter 22: 410-417.
30. KARBOWNIK M AND REITER RJ (2000): Antioxidative effects of melatonin in protection against cellular damage caused by ionizing radiation. *Proc. Exp. Biol. Med.*, 225 (1): 9–22.
31. KAUR J, RAMAKRISHNAN PR AND RAJALAKSHMI M (1992): Effect of cyproterone acetate on structure and function of rhesus monkey reproductive organs. *Anat. Res.*, 234: 62-72.
32. [KECK AS](#) AND [FINLEY JW](#) (2004): Cruciferous vegetables: cancer protective mechanisms of glucosinolate hydrolysis products and selenium. [Integr. Cancer Ther.](#), 3(1): 5-12.
33. KOMATSU W, MIURA Y AND YAGASAKI K. (2002): Induction of tumor necrosis factor production and antitumor effect by cabbage extract. *Nutr. Cancer*, 43: 82–89.
34. KRZANOWSKA H, STYRNA J AND WABIK-LIZ B (1995): Analysis of sperm quality in recombinant inbred mouse strains: correlation of sperm head shape with sperm abnormalities and with the incidence of supplementary spermatozoa in the perivitelline space. *J. Reprod. Fertil.*, 104: 347-354.
35. KUMAR, ROBBINS AND COTRAN (2005): *Pathologic Basis of Disease*. 7th ed., Copyright Saunders, An Imprint of Elsevier
36. KUMAR M, SAMARTH R, KUMAR M, SELVAN SR, SAHARAN B AND KUMAR A (2007): Protective Effect of *Adhatoda vasica* Nees Against Radiation-Induced Damage at

- Cellular, Biochemical and Chromosomal Levels in Swiss Albino Mice. *Evid. Based Complement Alternat. Med.*, 4 (3): 343–350.
37. LENZI A, LOMBARDO F, SGRO P, SALACONE P, CAPONECCHIA L AND GANDINI L (2003): Use of Carnitine therapy in selected cases of male factor infertility: a double-blind crossover trial. *Fertil. Steril.*, 79 (2): 292-300.
 38. LIU X AND LI JY (2009): Update of the studies on epididymal oxidative stress. [*Zhonghua Nan Ke Xue.*](#), 15(2): 161-164.
 39. MATTAR FE (2008): Personal communication.
 40. MATTAR FE, FARID NM, ELTOUNSY MM AND ABD EL-WAHAB S (1987): Histological and quantitative cytochemical study on the possible radioprotective effect of butylated hydroxytoluene on rat testis. *Egypt. J. Histol.*, 10: 173-177.
 41. MEISTRICH ML (1989): Evaluation of reproductive toxicity by testicular sperm head counts. *Int. J. Toxicol.*, 8: 551–567.
 42. MOOR HDM AND BEDFORD JM (1979): Short –term effects of androgen withdrawal on the structure of different epithelial cells in the rat epididymis. *Anat. Rec.*, 193: 293-312.
 43. NAKAI M, HESS RA, MOORE BJ, GUTTROFF RF, STRADER LF AND LINDER RE (1992): Acute and long-term effects of a single dose of the fungicide carbendazim (methyl 2-benzimidazole carbamate) on the male reproductive system in the rat. *J. Androl.*, 13: 507-518.
 44. NARAYANA K, D'SOUZA UJ AND RAO KP (2002): Effect of ribavirin on epididymal sperm count in rat. *Indian J. Physiol. Pharmacol.*, 46: 97-101.
 45. PAGET GE AND BARNES JM (1964): Evaluation of drug activity. *Pharmaceutics* Laurence and Bacharach eds., vol. 1, Academic press, New York.
 46. PLANT TM AND MARSHALL GR (2001): The Functional Significance of FSH in Spermatogenesis and the Control of Its Secretion in Male Primates. *Endocrine Rev.*, 22 (6): 764-786.
 47. SAMANTA N AND GOEL HC (2002): Protection against radiation induced damage to spermatogenesis by *Podophyllum hexandrum*. *J. Ethnopharmacol.*, 81 (2): 217-224.
 48. SARATHCHANDIRAN L, MANAVALAN R, AKBARSHA MA, KADALMANI B AND KARAR PK (2007): Effects of ethanolic extract of *Capparis aphylla* (Roth) on testicular steroidogenesis in rats. *J. Biol. Sci.*, 7 (3): 582-584.
 49. SEVANI A AND URSINI F (2000): Lipid peroxidation in membranes and low-density lipoproteins: similarities and differences. *Free Radic. Biol. Med.*, 29: 306-311.
 50. SHI X, WANG P, JIANG H, MAO Y, AHMED N AND DALAL N (1996): Vanadium (IV) causes 2-deoxyribonucleic acid damage via free radical reactions. *Ann. Clin. Lab. Sci.*, 26 (1): 39-49.

51. SNEDECOR WG AND COCHRAN GW (1980): Statistical method. 7th ed., Iowa State University Press, Ames. Iowa.
52. SORENSEN M, JENSEN BR, POULSEN HE, DENG X, TYGSTRUP N, DALHOFF K AND LOFT S (2001): Effects of a Brussels sprouts extract on oxidative DNA damage and metabolising enzymes in rat liver. *Food Toxicol.*, 39 (6): 533-540.
53. STECK SE, GAUDET MM, BRITTON JA, TEITELBAUM SL, TERRY MB, NEUGUT AI, SANTELLA RM AND GAMMON MD (2007): Interactions among GSTM1, GSTT1 and GSTP1 polymorphisms, cruciferous vegetable intake and breast cancer risk. *Carcinogenesis*, 28 (9): 1954-1959.
54. STERLING M (2000): Got anthocyanins. These plant pigments are more than coloring agents for fruit juices, wine and other beverages; they also contain an array of health-promoting benefits. *NSN*, 5: 231-234.
55. VANG O, MEHROTA K, GEORGELLIS A AND ANDERSEN O (1999): Effects of dietary broccoli on rat testicular xenobiotic metabolizing enzymes. *Eur. J. Drug. Metab. Pharmacokinet.*, 24(4): 353-359.
56. VIJAYKUMAR B, SANGAMMA I, SHARANABASAPPA A AND PATIL SB (2004): [Antispermato-genic and hormonal effects of *Crotalaria juncea* Linn. seed extracts in male mice.](#) *Asian J. Androl. Mar.*, 6 (1): 67-70.
57. WALDEN TL AND FARZANEH NK (1990): "Biochemistry of ionizing radiation". Reven Press. 181(3): 635-639, New York.
58. WU SJ, WANG JS, LIN CC AND CHANGE CH (2001): Evaluation of hepatoprotective activity of legumes. *Phytomedicine*, 8 (3): 213-219.
59. YOKOZAWA T, KIM HY, CHO EJ, YAMABE N AND CHOI JS (2003): Protective effects of mustard leaf (*Brassica juncea*) against diabetic oxidative stress. *J. Nutr. Sci. Vitaminol.*, 49: 87-93.
60. ZUBKOVA EV AND ROBAIRE B (2004): Effect of glutathione depletion on antioxidant enzymes in the epididymis, seminal vesicles, and liver and on spermatozoa motility in the aging rat. *Biol. Reprod.*, 71(3): 1002-1008.

الدور الوقائي المحتمل لمستخلص بذور الكرنب ضد تأثير أشعة جاما على ذيل البربخ والحيوانات المنوية للجرذ

سامية محمد عبد الوهاب

قسم علم الحيوان - كلية العلوم - جامعة الأزهر- فرع البنات

من النباتات المستخدمة كغذاء لدى المصريين نبات الكرنب (*براسيكا أوليراسيا* كابتانا) وقد ثبت أن كثيرا من الكرنبيات تحتوي على مواد مضادة للأكسدة ومواد لها تأثير وقائي في حالات سرطان القولون وسرطان الثدي .

في هذا البحث إستخدم مستخلص كحولي لبذور الكرنب المصرى لدراسة تأثيره على تركيب ذيل البربخ ومورفولوجية الحيوانات المنوية في الجرذ كنموذج للكائنات الثديية ومنها الإنسان، ولتأكيد النتائج إستخدم مستخلص السلیمارين المعروف علميا بأثره كمضاد للأكسدة كعامل للمقارنة.

ونظراً لأن مضادات الأكسدة تعمل أساسا على معادلة الشقاق الحرة التى تنتج في الخلايا والأنسجة فقد تم تشيع الفئران المستخدمة في البحث لإطلاق ودراسة مدى الوقاية من تأثيرها بواسطة المستخلصات المستخدمة في البحث.

ولذلك كان الهدف الرئيسي لهذه الدراسة هو تأثير المستخلص على تركيب البربخ بعد تعرضه لأشعة جاما وذلك بالطرق الهستولوجية على أسس وصفية وكمية مع التحليل الإحصائي للنتائج وقد إستخدم في هذا البحث تسعون جرذاً أبيض بالغ، قسموا إلى ست مجموعات :

المجموعة الأولى : مجموعة ضابطة.

المجموعة الثانية : مجموعة ضابطة عرضت أجسادها لجرعات مجزئة من أشعة جاما ، 2 راد يوميا لمدة ثلاثة أيام متتالية.

المجموعة الثالثة : مجموعة تناولت 800 مجم/كجم/يوم من مستخلص بذور الكرنب يوميا لمدة ثلاثة أسابيع .

المجموعة الرابعة: مجموعة تناولت 800 مجم/كجم/يوم من مستخلص بذور الكرنب يوميا لمدة ثلاثة أسابيع (اسبوع قبل وأثناء وبعد التشيع) .

المجموعة الخامسة: مجموعة تناولت 20 مجم/كجم/يوم من مستخلص السلیمارين يوميا لمدة ثلاثة أسابيع .

المجموعة السادسة: مجموعة تناولت 20 مجم/كجم/يوم من مستخلص السلیمارين يوميا لمدة ثلاثة أسابيع (اسبوع قبل وأثناء وبعد التشيع) .

ذبحت الجرذان في اليوم الأول والسابع والواحد والعشرون بعد التشعيع وأخذت عينات من رؤوس البربخ وتم عمل سحبات منوية منها صبغت بالهيماتوكسولين والإيوسين لدراسة التشوهات المورفولوجية في الحيوانات المنوية . حضرت قطاعات شمعية من البربخ وصبغت بالهيماتوكسولين والإيوسين وذلك للدراسة الهستولوجية . وقد أظهرت النتائج حدوث تغيرات في ذيل البربخ للحيوانات التي تعرضت للإشعاع إذا ما قورنت بالحيوانات الضابطة منها إختزال في قطر الأنبيبات وإحتقان الأوعية الدموية وتدمير بعض الأنبيبات مع زيادة في المادة البينية وكذلك قلة كثافة الحيوانات المنوية مع زيادة الأشكال المشوهة .

وقد أظهرت النتائج أن لمستخلص بذور الكرنب تأثير وقائي ضد الإشعاع لا يقل عن تأثير السليمارين من حيث حمايته لتأثير التشعيع على حياة وتركيب الخلايا الطلائية المبطننة لأنبيبات البربخ وكذلك الحيوانات المنوية من التحلل .

