

Single and Double Fused Roots with C-shaped Canal Configuration in the Posterior Teeth of a Patient: A Rare Case Report

AFZAL ALI¹, BANU ARICIOĞLU², HANY MOHAMED ALY AHMED³, ASMA ZOYA⁴, HAKAN ARSLAN⁵

ABSTRACT

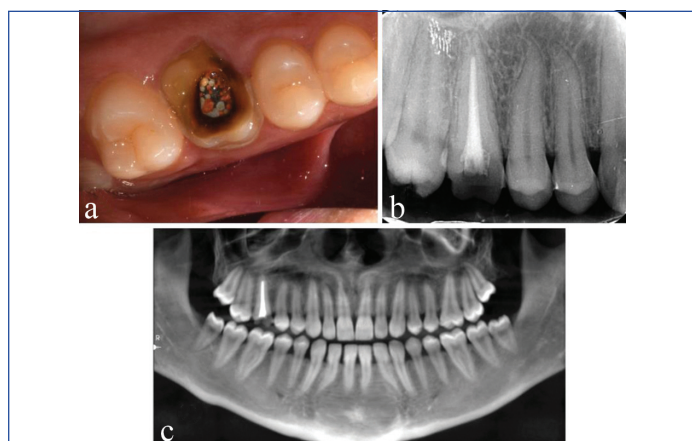
Cone Beam Computed Tomography (CBCT) allows three-dimensional evaluation of external root morphology and internal canal configuration of teeth thus allowing accurate diagnosis of rare complexities in the root canal system. This case study presented root canal re-treatment of a maxillary first molar #16 of a 29 years old female patient, wherein, thorough radiographic examination revealed single root morphology in all the teeth. CBCT analysis confirmed the root form and root canal configuration. Endodontic retreatment of the #16 was performed. The maxillary first molars had double fused roots with C-shaped canal configuration while maxillary second and third molars had O-shaped canals with single roots bilaterally. The mandibular first molars had two completely fused roots with C-shaped canal configuration. While the mandibular second and third molars also had C-shaped canal configuration with single roots. The canal configuration of maxillary and mandibular molars was classified according to Martin's and Fan's classification respectively. This unique finding of single and double fused roots with C-shaped canal configuration in the posterior teeth in a single patient has rarely been reported in literature.

Keywords: Carious, Endodontic, Fissure, Molars, Retreatment

CASE REPORT

A 29-year-old Indian female patient presented to the Department of Endodontics, with intermittent pain in relation to the upper right back tooth since one year. Medical history was non contributory. There was no congenital tooth deficiency or a familial presentation. Past dental history revealed that patient underwent root canal treatment of the maxillary right first molar two years ago.

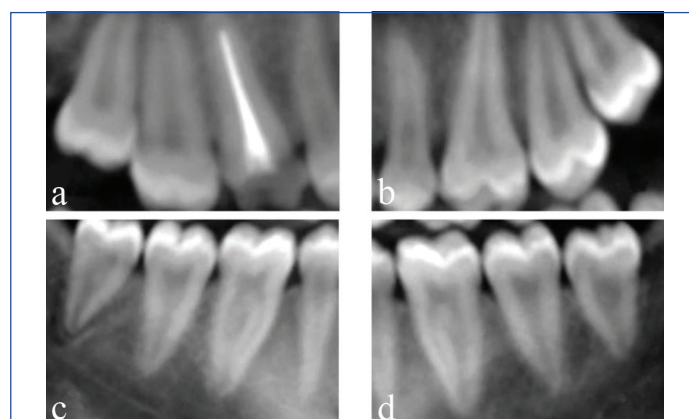
Intraoral examination revealed a pit and fissure carious lesion related to the maxillary left first molar #26. The maxillary right first molar #16 was tender on percussion. The root canal obturation material was visible as there was no post-endodontic restoration in #16 [Table/Fig-1a]. Intraoral periapical radiographic image revealed the presence of single root with non satisfactory obturation and periodontal widening in tooth #16 [Table/Fig-1b]. The tooth #16 was diagnosed as previously treated with chronic apical periodontitis. Root canal re-treatment was scheduled for tooth #16. A panoramic re-construction from CBCT images was obtained [Table/Fig-1c] to assess the number of roots or any gross anatomic variations in all the teeth.



[Table/Fig-1]: a) Illustrations representing pre-operative clinical view; b) Pre-operative radiographic view; c) Panoramic reconstruction from CBCT Scan.

The periapical radiographic image revealed all maxillary right molars with single root and single canal configuration (#16, 17 and #18) [Table/Fig-2a-d]. Radiographs of the contralateral maxillary molars

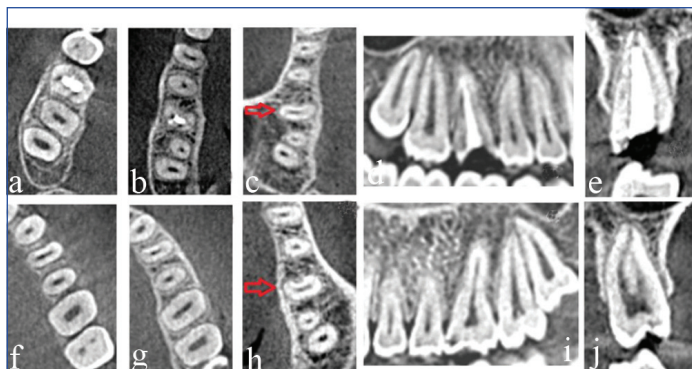
(#26, #27 and #28) were taken due to carious involvement of tooth #26, which revealed similar root morphology. Due to the unusual root morphology of all maxillary posterior teeth, periapical radiographic imaging was performed for the mandibular molar [1]. These radiographs were also suggestive of single root morphologies of mandibular molars except for first molars (#36, #46). Due to the atypical root anatomy of all the molars, CBCT imaging was performed with the informed patient consent, following the guidelines suggested by the American Association of Endodontists and the European society of Endodontology [2,3]. A CBCT full scan was obtained (Carestream 9300; Carestream Health, Rochester, NY, USA) at 84 kV, 6 mA, 250 μ m voxel size with 12 seconds exposure [Table/Fig-2a-d].



[Table/Fig-2]: Illustrations representing preoperative periapical radiographic view of maxillary a) #16, #17, #18; b) #26, #27, #28; c) and mandibular #36, #37, #38 (d); #46, #47, #48 molars.

The assessment of axial, sagittal and coronal section of CBCT images of maxillary molars confirmed the presence of single-root form in all the teeth [Table/Fig-3a-j]. The sagittal sections of maxillary molars also confirm the same. The coronal section of #16 tooth confirms single root, single canal form with the non-satisfactory obturation.

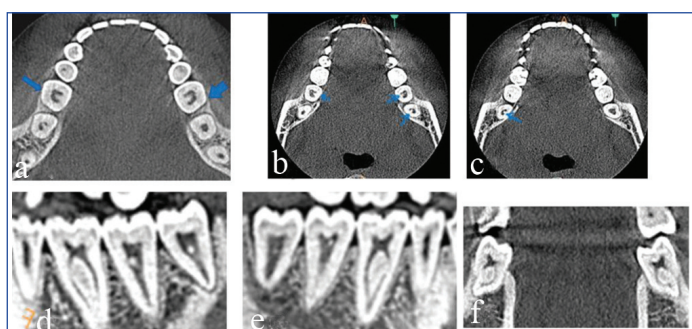
In the present reported case, the maxillary first molars had unusual radiographic appearance. There was impression of superimposed buccal and palatal roots and absence of two divergent mesiobuccal



[Table/Fig-3]: CBCT images representing (a-c) Axial section; (d) sagittal view; (e) coronal section of #16 Tooth; (f-h) axial sections; (i) sagittal view; (j) coronal sections of tooth #26. C shaped root cross-section for upper first molars of #16 (c) and #26 (h).

and distobuccal roots. CBCT revealed root fusion between single buccal and palatal root with semilunar cross-section and C-shaped root canal bilaterally.

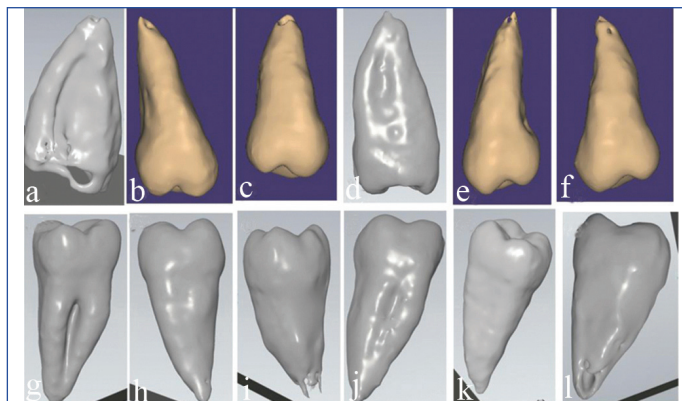
Similarly, the CBCT assessment of mandibular molars was performed in coronal, sagittal and axial sections. These teeth also showed single root, single canal form except the mandibular first molars (#36 and #46) which had two fused roots and C-shaped canal configurations [Table/Fig-4a-f]. The mandibular second and third molars also had C-shaped canal configurations with single roots, bilaterally. Likewise, bilateral maxillary first molars (#16 and #26) had C-shaped canal with fused buccal and palatal roots, while maxillary second and third molars were found to have O-shaped canals with single roots. All the maxillary and mandibular premolars had single roots. For better understanding of external surface characteristics, external morphologic images were obtained from Dicom data and stereolithographic files [Table/Fig-5a-l]. Longitudinal groove was observed over the root surface in maxillary and mandibular molars. Shallow longitudinal groove was present at the distal root surface of #26, while deep longitudinal groove was present at the distal root surface of #16. Fused root can be appreciated for the mandibular first molars (#36, #46), while single root form can be appreciated with the maxillary and mandibular second and third molars [Table/Fig-5]. All the teeth including first molars had a single apical foramen [Table/Fig-5a-l].



[Table/Fig-4]: CBCT images representing (a-c) axial section of mandibular molars; (d) sagittal section 36, 37 & 38; (e) sagittal section 46,47 & 48; (f) coronal view 36 and 46 Tooth.

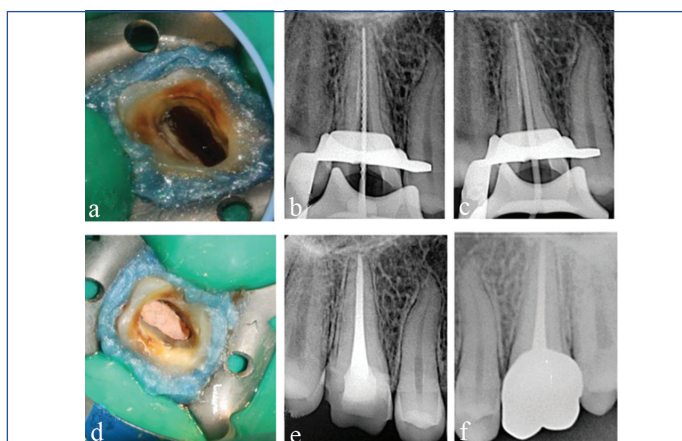
Root canal retreatment for 16 was planned. The informed valid consent was obtained before the treatment. Local anaesthesia was administered through buccal infiltrations using (1.8 ml) of 2% lidocaine with 1:100,000 epinephrine (Lidocaine HCl, Huons Co., Seoul, Korea). After rubber dam isolation, the previous root canal obturation material was removed with Hedström files (Dentsply Maillefer, Ballaigues, Switzerland) and core build up was done [Table/Fig-6a].

The working length of the root canal (18 mm) was estimated with an electronic apex locator (Propex pixi, Dentsply Maillefer, Ballaigues, Switzerland) and verified by a periapical radiograph [Table/Fig-6b]. The large single root canal of tooth #16 was prepared up to size #60 K-file (Dentsply Maillefer, Ballaigues, Switzerland). The



[Table/Fig-5]: External surface morphology image extracted from STL file and CBCT data of (a) #16 tooth; (b) #17 tooth; (c) # 18 tooth; (d) #26 tooth; (e) #27 tooth; (f) # 28 tooth; (g) #36 tooth; (h) #37 tooth; (i) #38 tooth; (j) #46 tooth; (k) #47 tooth; (l) #48 tooth.

master cone was verified radiographically [Table/Fig-6c]. A 3% sodium hypochlorite (Novo Dental Product Pvt., Ltd., Mumbai, MH, India) was used intermittently during canal shaping along with sonic activation (EDDY; VDW, Munich, Germany). The root canal was irrigated for one minute with 17% EDTA and distilled water, then dried with paper points. Calcium hydroxide (CleaniCal, Maruchi; Wonju, Korea) was placed as an intracanal medicament for five days. At the next appointment, the intracanal medicament was removed by copious irrigation with 3% sodium hypochlorite and distilled water. Root canal obturation was completed with size 60/0.02 taper master gutta-percha cone (Dentsply Maillefer, Ballaigues, Switzerland) and EndoSeal MTA sealer (Maruchi; Wonju, Korea) with the combination of cold lateral and warm vertical compaction techniques [Table/Fig-6d]. The access cavity was cleaned using an alcohol-moistened cotton pellet. Coronal access was built with Filtek-Z350 resin composite (3M ESPE Dental Product) [Table/Fig-6e]. Tooth #16 was asymptomatic clinically and radiographically in the follow-up visit [Table/Fig-6f].



[Table/Fig-6]: Illustrations representing (a) Clinical view after GP removal and core build-up (b); Radiograph showing working length (c); Master cone (d); immediate postobturation clinical view (e); Radiograph after post-endodontic restoration and; (f) one year follow-up radiograph of tooth #16.

DISCUSSION

The purpose of this case study was to present the atypical morphologic root formation as single root and single canal in all posterior teeth (except #36 and #46) in a patient diagnosed with 3D imaging technique (CBCT).

A root with a conical canal and a single apical foramen is regarded as an exception in general [4]. The development of Hertwig's Epithelial Root Sheath (HERS) differs in single and multi-rooted teeth. Differential growth along with the proliferation of epithelial diaphragm causes division of roots and determines single or multiple roots [5]. The most common explanation for the formation of the C-shaped canal configuration is the failure of HERS to fuse during the formation of multiple roots. Failure of HERS to fuse on

the buccal side results in a lingual groove, and failure to fuse on the lingual side results in a buccal groove. When the sheath fails to fuse on both the sides it leads to the formation of a conical or prism-shaped root. Fusion of roots is most likely to occur if the distance between the root canals is small [6]. Teeth with fused roots present with a wide variety of internal morphologies across the length of the root, including merged and C-shaped canal configurations [7].

It has been reported that genetic changes of candidate genes such as Bone Morphogenetic Proteins (BMP), Fibroblast Growth Factor (FGF), Sonic Hedgehog Gene (SHH), which play a role in differential growth of the epithelial diaphragm, are effective in the root and canal model. These genes affect molar morphogenesis by influencing homeobox genes 1, 2, 6, and 7 [8].

In the present case, all the teeth including first molars had a single apical foramen. Single canal (Vertucci Type I configuration) was present for all teeth except first molars (#26, #36 and #46). There was bilateral symmetry for all the teeth. However, the 2-canal configuration could not be appreciated in tooth #16 during the re-treatment procedure possibly due to over preparation of root canal during primary endodontic treatment. The presence of bilateral C-shaped canal configuration has been speculated in over 70% of individuals [9].

From a clinical perspective, when the initial radiograph reveals an atypical anatomic form, it is recommended to take a radiograph of the contralateral tooth. Additional radiographs with mesial or distal projections are also indicated for further information [1]. The same procedure was performed to identify the anomalous behaviour in the present case.

Root fusion in mandibular molars commonly appears as C-shaped root, however in maxillary molars fused roots present a variety of shapes due to the possibility of partial or entire fusion of two or more roots [7]. C-shaped root canals can arise either as a result of complete fusion of all roots into one root canal system or as a result of partial fusion of root canals joined by an isthmus. Mandibular molars with a C-shaped canal can have a single fused root or two juxtaposed roots with communications, the latter of which is difficult to distinguish on radiographs [10].

In the present case, the C-shaped mandibular first molars had radiographic appearance of two roots. While other mandibular molars had single conical roots with C-shaped cross-section. Fan B et al., observed three characteristics in mandibular teeth with a C-shaped canal system: fused roots, a longitudinal groove on the root's lingual or buccal surfaces, and at least one cross-section of the canal with the C1, C2, or C3 form [11]. In the present case all the mandibular molars exhibited fused roots/longitudinal groove on the root surface.

Martin JN et al., in a CBCT study, identified the maxillary C shape with two criteria's: root fusion and three consecutive axial cross-sections with an upper-C (UC) 1 or UC2 configuration in the fused root [7]. The UC configuration system is a modification for the upper molars based on Fan et al study regarding the lower molars. The UC system has five axial root canal system configurations (UC1-UC5). Maxillary first molars (#16 and #26) were categorised as C-shaped according to Martin's criteria for maxillary molars [7]. While mandibular C-shaped molars were classified according to Fan's modification of Melton's classification [Table/Fig-7] [11]. All other posterior teeth were classified according to Vertucci FJ and Ahmed HMA and Dummer PMH, classification and are summarised in [Table/Fig-8] [12,13]. Both classification were able to classify the root and canal configurations. However, Ahmed HMA and Dummer PMH classification [13] provided additional information for teeth with fused roots (with separate or connected canals) as shown in [Table/Fig-8].

The anatomical abnormalities of teeth may vary not only according to the sex, but also geographic regions and ethnicity. This may

C- shape canal configurations	Coronal root axial section	Middle root axial section	Apical root axial section
16	UC1	UC1	UC4
26	UC1	UC2	UC1
36	C1	C3	C1
46	C1	C3	C1
37	C1	C4	C4
47	C1	C2	C4
38	C1	C4	C4
48	C1	C4	C4

[Table/Fig-7]: Occurrence of C shape canal configuration in different tooth.

The root canal system of maxillary molars was classified according to Martins JN et al., classification as maxillary Upper-C (UC). UC1: Continuous large C-shaped canal system; UC2: Continuous C-shaped canal with 2 main canal lumen in the extremities connected by a large isthmus; UC3: 2 separated root canals; UC4: A single round or oval root canal; UC5: No canal lumen [7].

Tooth*	Root Number	Vertucci Classification ¹	New Classification ²	Tooth*	Root Number	Vertucci Classification ¹	New Classification ²
11	1	Type I	'11 ¹	21	1	Type I	'21 ¹
12	1	Type I	'12 ¹	22	1	Type I	'22 ¹
13	1	Type I	'13 ¹	23	1	Type I	'23 ¹
14	1	Type II	'14 ²⁻¹	24	1	Type I	'24 ¹
15	1	Type I	'15 ¹	25	1	Type I	'25 ¹
16	1	Type I	² 16 B// P ¹	26	1	Type III	'26 ¹⁻²⁻¹
17	1	Type I	'17 ¹	27	1	Type I	'27 ¹
18	1	Type I	'18 ¹	28	1	Type I	'28 ¹
31	1	Type I	'31 ¹	41	1	Type I	'41 ¹
32	1	Type I	'32 ¹	42	1	Type I	'42 ¹
33	1	Type I	'33 ¹	43	1	Type I	'43 ¹
34	1	Type I	'34 ¹	44	1	Type I	'44 ¹
35	1	Type I	'35 ¹	45	1	Type I	'45 ¹
36	2	D:Type I M:Type II	² 36 M ²⁻¹ / D ¹	46	2	D:Type I M:Type II	² 46 M ²⁻¹ / D ¹
37	1	Type I	'37 ¹	47	1	Type I	'47 ¹
38	1	Type I	'38 ¹	48	1	Type III	'48 ¹⁻²⁻¹

[Table/Fig-8]: Number of roots and canal morphologies.

*FDI World Dental Federation System for tooth classification. ¹Vertucci FJ classification system-Type I- 1 canal; Type II-2-1 canal [12]; ²Ahmed HMA et al., classification system- Details of classification in multi-rooted teeth are 'TN R1^{0-C-F} R2^{0-C-F} Rn^{0-C-F} [13]. Here 'n' number of roots, TN tooth number, R root, the orifice(s) (O), through the canal (C) to the foramen (foramina) (F). "/" is placed for fused roots with separate canals. "-" is placed for fused roots with connected canals.

explain the different results observed between the different regions of the world. For example, the prevalence rate of single root and one canal anatomy in the mandibular second molar was 1.3% in the American population, 2.1% Turkish, and 2.2% in Burmese population. In the literature the frequency rate of single-rooted tooth with conical or C-shaped configuration is about 21.8%. However, the prevalence rate is quite low for maxillary and mandibular molars [14]. In a staining and clearing study, Singh S et al., reported single rooted morphology in 5% of the second molars and 15 % in the third molars, however, this anatomy was in a rare occasion in the maxillary molars [15].

Two reports documented the incidence as 0.5% and 0.6%, respectively, in maxillary second molars by radiographic evaluation [16,17]. While Pérez-Heredia M et al., observed single root and canal configuration rate was in 2.1% and 17% in maxillary first and second molars, respectively [18]. Additionally, the frequency was 1.6% and 16% for mandibular first and second molars. The studies and case reports regarding the reported rarity of single-rooted and canal morphology of molars are summarised in [Table/Fig-9,10] [15-36].

The main anatomical feature of C-shaped canals is the presence of a fin or web connecting the individual root canals. Roots containing

Investigators-years	Detection method	Population	Details
Newton CW and McDonald S [25], 1984	Periapical radiograph	Caucasian	1 Case (maxillary first molar)
Dankner E et al., [26], 1990	Periapical radiograph	Caucasian	1 case (maxillary first molar)
De Moor R [27], 2002	Periapical radiographs	Caucasian	4 cases (maxillary first molar)
Yilmaz Z et al., [28], 2006	Periapical radiographs	Caucasian	
Gopikrishna V et al., [29], 2006	Pantomograph, Intraoral Periapical Radiographs, CBCT	Asian (Indian)	1 case (maxillary first molar)
Cobankara FK et al., [30], 2008	Spiral Computed Tomography	Caucasian (Turkish)	1 case (maxillary. first molar)
de la Torre F et al., [31], 2008	Periapical Radiograph	Caucasian (Spanish)	1 case (maxillary first molar)
Ioannidis K et al., [32], 2011	Radiographs, CBCT	Caucasian (Greek)	7 cases (4 maxillary first and second molars bilaterally-3 mandibular first and second molars)
Jaikrishnan S et al., [33], 2015	CBCT	Asian (Indian)	6 cases (maxillary first and second molars)
Kharouf N et al., [34], 2019	Periapical radiograph	Caucasian	2 cases (maxillary first molar)
Shin Y et al., [35], 2013	Periapical Radiographs, CBCT	Korean	1 case (maxillary first molar Intentional replantation)

[Table/Fig-9]: Clinical case reports of single rooted molars [25-35].

S. No.	Author(s)	Year	Population	Prevalence	
				Maxillary	Mandibular
1.	Hartwell G and Bellizzi R [17]	1982	European	2 nd molar (0.6%)	-
2.	Libfeld H and Rotstein I [16]	1989	Palestine	2 nd molar (0.5%)	-
3.	Neelakantan P et al., [19]	2010	Indian	1 st molar (0.9%), 2 nd molar (0.9%), single rooted	-
4.	Zhang Q et al., [36]	2014	Chinese	2 nd Molar (25%), single root, one canal	-
5.	Zhang W et al., [20]	2018	Chinese		Maxillary and mandibular third Molar
6.	Rawtiya M et al., [21]	2016	Indian	3 rd molar (16%)	-
7.	Somasundaram P et al., [22]	2017	Indian	3 rd molar (9.4%), single root, C-shape	-
8.	Pérez-Heredia M et al., [18]	2017	Spanish	1 st molar (2.1%), 2 nd molar (17%), single root, one canal	1 st molar (1.6%), 2 nd molar (16%)
9.	Martins J et al., [23]	2019	Portugese	1 st molar (1.1%), C-shape, 2 nd molar (3.4%), C-shape	1 st molar (1.7%), 2 nd molar (3.5-44%) C-shape
10.	Kantilieraki E et al., [24]	2019	Greek	-	1 st molar (0.2%), single root, one canal
11.	Singh S et al., [15]	2020	Indian	-	2 nd molar (5%), 3 rd molar (15%)

[Table/Fig-10]: Prevalence rate of single root and one canal anatomy in similar studies [15-24,36].

a C-shaped canal often have a conical or square configuration [11]. According to De Moor R, the probability of observing a C-shaped

canal in a maxillary first molar was as low as 0.091% [27]. Gopikrishna V et al., presented a case of bilateral maxillary first molar with single root and single oval canal [29]. Kharouf N et al., presented a case of female patient with bilateral C-shaped maxillary first molars and quadrilateral C-shaped second molars [34].

C-shaped canals in maxillary first molars have been accounted rarely in a small number of case reports and studies. A micro-CT study on mandibular second molars with fused roots by Amoroso-Silva P et al., stated that the cross-sectional canal shape is determined by the extension and depth of the radicular grooves, and the lower depth of the groove or its absence allowed for an oval- or round-shaped canal [37]. This could account for the occurrence of C- and O-shaped canals in the single patient with all fused rooted teeth.

Several authors have used the terminology O-shape apart from C-shaped canal. Kantilieraki E et al., categorised single rooted mandibular molars on the basis of root cross-section outline into O shape and C shape [24]. The O-shaped molars presented a round or oval cross-section along the entire root length, while C-shaped molars displayed a C-shaped cross-section at least at one point along the root. Shin Y et al., first reported a case of maxillary first molar with an O-shaped root and considered it as an extension of C-shaped root which occurs when there is complete fusion of the three roots [35].

In a CBCT study of maxillary molars Kim JW et al., have classified 8 types of C-shaped roots depending upon the fusion of roots [38]. The eighth type of this classification includes O- shaped root canal i.e., when all the three roots fuse together and present a circular or oval cross-section with single oval canal. They found 0.3% prevalence of O-shaped root canal in maxillary molars.

In the present reported case, the maxillary first molars had unusual radiographic appearance. There was impression of superimposed buccal and palatal roots and absence of two divergent mesiobuccal and distobuccal roots. CBCT revealed root fusion between single buccal and palatal root with semilunar cross-section and C-shaped root canal bilaterally.

The prevalence of root fusion in maxillary second molars has been reported to be 5.9%-40.1%. The maxillary second and third molars had O-shaped canals with single conical completely fused roots. Zhang Q et al., classified root fusion into 6 types and Martins JN et al., added type 7 which includes single conical root as another variant of root fusion [7,36]. In the present case, the second and third maxillary molars represented type 7 root fusion according to Martin's modification of Zhang i.e., single conical root with complete canal merging.

The single rooted maxillary molars represent a trend of root reduction or fusion. In a CBCT study of Indian population Neelankantan P et al., reported the prevalence of single rooted maxillary first and second molars as 0.9% each [19]. The type of root fusion could be classified as type 6 according to Zhang's classification [36] of root fusion. The root canal in a maxillary molar with the fused root can be either merging or C-shape. Shallow longitudinal groove was present at the distal root surface of #26, while deep longitudinal groove was present at the distal root surface of #16. The C-shape canal configuration for both the maxillary first molars (#16 and #26) were found to be similar to type II subtype A classified by Jo HH et al., because of the fusion of all three root canals [39].

According to Jo HH et al., maxillary second and third molars (#17,#18, #27 and #28) could also be classified as 'All root' type root fusion, due to the oval cross-section image of coronal root and circular cross-section image of the apical root and complete fusion of three roots [39]. Martin J et al., in their systematic review and meta-analysis reported the prevalence of maxillary and mandibular first molars, mandibular second molars with C-shaped canal morphology [23]. Zhang W et al., in their micro-CT study reported

single root, single canal configuration in maxillary third molars [20]. CBCT analysis of Indian population also reported single root single canal configuration of maxillary and mandibular third molars.

CONCLUSION(S)

Root canal morphology can demonstrate variations. Besides the ethnic origin, C-shaped canal configuration can be seen in systematically healthy people as well as syndromic patients. The present rare case of an Indian female patient reported the single root, single canal form in premolars as well as molars. Although it is rare, the recognition with periapical radiographs and CBCT should not be underestimated by the clinicians.

REFERENCES

- Fava L, Dummer P. Periapical radiographic techniques during endodontic diagnosis and treatment. *Int Endod J.* 1997;30(4):250-61.
- Fayad MI, Nair M, Levin MD, Benavides E, Rubinstein RA, Barghan S, et al. AAE and AAOMR joint position statement: use of cone beam computed tomography in endodontics 2015 update. *Oral Surg Oral Med Oral Radiol.* 2015;120(4):508-12.
- Patel S, Durack C, Abella F, Roig M, Shemesh H, Lambrechts P, et al. European Society of Endodontology position statement: the use of CBCT in endodontics. *Int Endod J.* 2014;47(6):502-04.
- Baghbani A, Bagherpour A, Ahmadis Z, Dehban A, Shahmohammadi R, Jafarzadeh H. The efficacy of five different techniques in identifying C-shaped canals in mandibular molars. *Aust Endod J.* 2021;47(2):170-77.
- Jeddy N, Radhika T, Nithya S, Krithika C, Prabakar R. Single rooted permanent premolars and molars-a rare clinical presentation confirmed using cone beam computed tomography. *J Clin Diagn Res.* 2015;9(8):ZD15.
- Fernandes M, De Ataide I, Wagle R. C-shaped root canal configuration: A review of literature. *J Conserv Dent.* 2014;17(4):312.
- Martins JN, Mata A, Marques D, Caramês J. Prevalence of root fusions and main root canal merging in human upper and lower molars: a cone-beam computed tomography in vivo study. *J Endod.* 2016;42(6):900-08.
- Agarwal A, Gundappa M, Miglani S, Nagar R. Asyndromic hypodontia associated with tooth morphology alteration: A rare case report. *J Conserv Dent.* 2013;16(3):269.
- Sabala CL, Benenati FW, Neas BR. Bilateral root or root canal aberrations in a dental school patient population. *J Endod.* 1994;20(1):38-42.
- Gulabivala K, Aung T, Alavi A, Ng YL. Root and canal morphology of Burmese mandibular molars. *Int Endod J.* 2001;34(5):359-70.
- Fan B, Cheung GS, Fan M, Gutmann JL, Bian Z. C-shaped canal system in mandibular second molars: part I- anatomical features. *J Endod.* 2004;30(12):899-903.
- Vertucci FJ. Root canal anatomy of the human permanent teeth. *Oral Surg Oral Med Oral Pathol.* 1984;58(5):589-99.
- Ahmed HMA, Dummer PMH. A new system for classifying tooth, root and canal anomalies. *Int Endod J.* 2018;51(4):389-404.
- Roy A, Velmurugan N, Suresh N. Mandibular second molar with a single root and a single canal: Case series. *J Clin Diagn Res.* 2013;7(11):2637.
- Singh S, Pawar M, Podar R, Kulkarni G, Bhanushali N. Root canal morphology of South Asian Indian mandibular first, second, and third molar: A dye penetration and clearing study. *J Conserv Dent.* 2020;23(3):284.
- Libfeld H, Rotstein I. Incidence of four-rooted maxillary second molars: literature review and radiographic survey of 1,200 teeth. *J Endod.* 1989;15(3):129-31.
- Hartwell G, Bellizzi R. Clinical investigation of in vivo endodontically treated mandibular and maxillary molars. *J Endod.* 1982;8(12):555-57.
- Pérez-Heredia M, Ferrer-Luque CM, Bravo M, Castelo-Baz P, Ruíz-Piñón M, Baca P. Cone-beam computed tomographic study of root anatomy and canal configuration of molars in a Spanish population. *J Endod.* 2017;43(9):1511-16.
- Neelakantan P, Subbarao C, Ahuja R, Subbarao CV, Gutmann JL. Cone-beam computed tomography study of root and canal morphology of maxillary first and second molars in an Indian population. *J Endod.* 2010;36(10):1622-27.
- Zhang W, Tang Y, Liu C, Shen Y, Feng X, Gu Y. Root and root canal variations of the human maxillary and mandibular third molars in a Chinese population: A micro-computed tomographic study. *Arch Oral Biol.* 2018;95:134-40. <https://pubmed.ncbi.nlm.nih.gov/30107301/>.
- Rawtiya M, Somasundaram P, Wadhvani S, Munuga S, Agarwal M, Sethi P. Retrospective study of root canal configurations of maxillary third molars in Central India population using cone beam computed tomography Part-I. *Eur J Dent.* 2016;10(01):097-102.
- Somasundaram P, Rawtiya M, Wadhvani S, Uthappa R, Shivagange V, Khan S. Retrospective study of root canal configurations of mandibular third molars using CBCT-part-II. *J Clin Diagn Res.* 2017;11(6):ZC55.
- Martins J, Marques D, Silva E, Caramês J, Mata A, Versiani M. Prevalence of C-shaped canal morphology using cone beam computed tomography-a systematic review with meta-analysis. *Int Endod J.* 2019;52(11):1556-72.
- Kantilieraki E, Delantoni A, Angelopoulos C, Beltes P. Evaluation of root and root canal morphology of mandibular first and second molars in a Greek population: a CBCT study. *Eur Endod J.* 2019;4(2):62-68.
- Newton CW, McDonald S. A C-shaped canal configuration in a maxillary first molar. *J Endod.* 1984;10(8):397-99.
- Dankner E, Friedman S, Stabholz A. Bilateral C shape configuration in maxillary first molars. *J Endod.* 1990;16(12):601-03.
- De Moor R. C-shaped root canal configuration in maxillary first molars. *Int Endod J.* 2002;35(2):200-08.
- Yilmaz Z, Tuncel B, Serper A, Calt S. C-shaped root canal in a maxillary first molar: a case report. *Int Endod J.* 2006;39(2):162-66.
- Gopikrishna V, Bhargavi N, Kandaswamy D. Endodontic management of a maxillary first molar with a single root and a single canal diagnosed with the aid of spiral CT: a case report. *J Endod.* 2006;32(7):687-91.
- Cobankara FK, Terlemez A, Orucoglu H. Maxillary first molar with an unusual morphology: report of a rare case. *Oral Surg Oral Med Oral Pathol Oral Radiol Endod.* 2008;106(6):e62-e65.
- de la Torre F, Cisneros-Cabello R, Aranguren JL, Estévez R, Velasco-Ortega E, Segura-Egea JJ. Single-rooted maxillary first molar with a single canal: endodontic retreatment. *Oral Surg Oral Med Oral Pathol Oral Radiol Endod.* 2008;106(6):e66-e68.
- Ioannidis K, Lambrianidis T, Beltes P, Besi E, Malliari M. Endodontic management and cone-beam computed tomography evaluation of seven maxillary and mandibular molars with single roots and single canals in a patient. *J Endod.* 2011;37(1):103-09.
- Jaikrishnan S, Kottoor J, Mathew J, Kumar SR, George S, Hari K. Evaluation and endodontic management of a patient with 6 single-rooted molars: a case report. *Gen Dent.* 2015;63(5):e35-37.
- Kharouf N, Haikel Y, Mancino D. Unusual maxillary first molars with c-shaped morphology on the same patient: variation in root canal anatomy. *Case Rep Dent.* 2019;2019:1857289. Doi: 10.1155/2019/1857289.
- Shin Y, Kim Y, Roh B-D. Maxillary first molar with an O-shaped root morphology: report of a case. *Int J Oral Sci.* 2013;5(4):242-44.
- Zhang Q, Chen H, Fan B, Fan W, Gutmann JL. Root and root canal morphology in maxillary second molar with fused root from a native Chinese population. *J Endod.* 2014;40(6):871-75.
- Amoroso-Silva P, De Moraes IG, Marceliano-Alves M, Bramante CM, Zapata RO, Duarte MAH. Analysis of mandibular second molars with fused roots and shallow radicular grooves by using micro-computed tomography. *J Conserv Dent.* 2018;21(2):169.
- Kim J-W, Ji H-J, Cho K-M, Kim S-M, Park S-H. A cone-beam computed tomographic study of C-shaped root and root canal in maxillary molars. *J Dent Rehabil Appl Sci.* 2015;31(2):104-11.
- Jo H-H, Min J-B, Hwang H-K. Analysis of C-shaped root canal configuration in maxillary molars in a Korean population using cone-beam computed tomography. *Restor Dent Endod.* 2016;41(1):55-62.

PARTICULARS OF CONTRIBUTORS:

- Reader, Department of Conservative Dentistry and Endodontics, Pacific Dental College and Hospital, Udaipur, Rajasthan, India.
- Assistant Professor, Department of Endodontics, Faculty of Dentistry, Istanbul Medeniyet University, Istanbul, Turkey
- Senior Lecturer, Department of Restorative Dentistry, Faculty of Dentistry, University of Malaya, Kuala Lumpur, Malaysia.
- Endodontist, Department of Consultant Endodontist, Dentino Centre of Advanced Dentistry, Aligarh, Uttar Pradesh, India.
- Professor, Department of Endodontics, Faculty of Dentistry, Istanbul, Medeniyet University, Istanbul, Turkey.

NAME, ADDRESS, E-MAIL ID OF THE CORRESPONDING AUTHOR:

Asma Zoya,
Endodontist, Department of Consultant Endodontist, Dentino Centre of Advanced
Dentistry, Aligarh, Uttar Pradesh, India.
E-mail: asmazoya@gmail.com

PLAGIARISM CHECKING METHODS: [\[Jain H et al.\]](#)

- Plagiarism X-checker: May 23, 2022
- Manual Googling: Oct 20, 2022
- iThenticate Software: Mar 30, 2023 (12%)

ETYMOLOGY: Author Origin

AUTHOR DECLARATION:

- Financial or Other Competing Interests: None
- Was informed consent obtained from the subjects involved in the study? Yes
- For any images presented appropriate consent has been obtained from the subjects. Yes

Date of Submission: **May 20, 2022**

Date of Peer Review: **Jul 21, 2022**

Date of Acceptance: **Apr 11, 2023**

Date of Publishing: **May 01, 2023**