



Three-dimensional CT Study of the Canine Head Using Volume Rendered 3D Computed Tomographic Reconstruction

Alberto Arencibia^{1*} and José Raduán Jáber¹

¹Department of Morphology, Veterinary Faculty, University of Las Palmas de Gran Canaria, Arucas 35416, Spain.

Authors' contributions

Author AA designed the study, wrote the protocol and wrote the first draft of the manuscript.
Authors AA and JRJ managed the analyses of the CT images. All authors read and approved the final manuscript.

Short Communication

Received 27th November 2013
Accepted 24th February 2014
Published 6th March 2014

ABSTRACT

Aims: To provide a description of normal anatomy of the bony structures of canine head using volume rendered 3D computed tomography (CT) reconstruction images as a tool for clinical and educational purposes.

Study Design: Application of CT for the study of the bony structures of the head in two male dogs, using three-dimensional reconstructed images.

Methodology: The images were obtained using a-CT axial equipment. Throughout the procedure, the dogs were positioned in ventral recumbency during scanning time. Contiguous transverse slices were acquired from the external nares to the occipital condyles of the skull. Scans were processed with a detailed algorithm to enhance bony structures using a wide window. The original data were stored and transferred to an image analysis workstation capable of generating 3D volume-rendered CT reconstructed images of the head, using a standard DICOM 3D format. CT images were compared to the corresponding osseous anatomic preparations and textbook to identify the normal 3D CT anatomy of the bony structures of the canine head.

Results: In the volume rendered 3D reformatted CT images, anatomical details of cranial and facial bones, mandible, hyoid bone and teeth were identified and labelled in the corresponding figures.

Conclusion: The volume-rendered 3D reformatted CT images obtained in this study

*Corresponding author: E-mail: aarencibia@dmor.ulpgc.es;

provided valid information on anatomic characteristics of bony structures of the head in dogs. These images should be useful for guiding clinical evaluation of this anatomic region in dogs.

Keywords: Volume rendered; computed tomography; anatomy; head; bones; dog.

1. INTRODUCTION

In veterinary medicine, modern image diagnostic techniques, especially Computed Tomography (CT), make it possible to obtain body sections from different tomographic planes, achieving images with a good anatomical resolution, high contrast between different structures and excellent tissues differentiation, contributing significantly to the progress of diagnostic imaging. In small animals, CT has been used sparingly for descriptive anatomic research [1-3], and diagnosing diseases of the head [4-6].

Advances and refinements in CT technology involve the application of computer software for the generation of three-dimensional (3D) reconstruction of an area of anatomic interest [7]. This technique requires multiple thin section images and advantages of this procedure are that anatomical detail is improved and bony structures can be imaged with different degrees of rotation [8].

In veterinary medicine, 3D CT reconstruction has been applied previously for several anatomic studies such as those done in the immature California sea lion head [9], in the temporomandibular joint in the young horse [10], in the equine cervical spine [11] and for assessment of canine cervical and lumbar spine [12] and in the diagnosis of neoplastic and non-neoplastic processes in dogs [13,14], but to the author's knowledge, there is no published material describing the results of CT anatomy of the head bones in dogs applying volume rendered 3D CT reformatted images. CT images provided excellent details of bony structures of the canine head. Knowledge of anatomy of the canine head is essential for the evaluation of CT scans. This study could be useful as an initial reference to aid in the diagnosis by CT of bone disorders of the canine head, using volume rendered 3D-reformatted images. In our study, anatomic structures of the head were seen using bone window settings and detailed algorithm. In addition, several criteria were used to reduce the presence of image artefacts and increase image contrast resolution, including thin anatomical slices, higher x-ray parameters and detailed imaged algorithms. Further studies concerning the CT appearance of the head in dogs would be necessary using soft-tissue CT window.

CT imaging is a diagnostic technique that offers considerable advantages over traditional radiography: a lack of superimposition of the tissues and a higher differentiation of tissue densities [1-3,10,15-16]. CT provides excellent spatial resolution and good discrimination between bone and soft tissue of the head [10,15-16]. CT is more sensitive in detecting diseases, and distinguishes normal and abnormal structures accurately [4-6,10,16]. In dogs, the principal disadvantages of CT imaging are related to the availability of the equipment and the need for general anaesthesia [16]. With developing technology, CT imaging may soon become more readily available for canine medicine. Reports of CT imaging of the head in dogs [1-3] and horses [10] applied similar technical parameters (kV, Ma and matrix). Recent studies described the potential of 3D CT reconstruction in veterinary medicine [9-14]. Volume rendered 3D-CT reformatted images canine head were obtained in lateral, dorsal, ventral and rostral aspects. The acquisition of three-dimensional CT images is not complicated, and

many images can be obtained viewing the bony structures in different aspects of the head. In our study, the volume-3D reconstructed images were helpful to visualize in four views the bony structures in canine head.

An accurate CT interpretation of the canine head could be useful in the evaluation and diagnosis of different pathological processes such as fractures, congenital diseases, infections, inflammations or tumours. The purpose of this study is to provide an overview of the normal anatomy of the canine head using 3D CT reconstruction images. These CT images are intended to be a useful anatomic reference for clinical studies of the head in dogs.

2. MATERIALS AND METHODS

Two mature mixed-breed male dogs were used for this study. The first dog was five years-old and a weight of 29Kg and the other animal was seven years-old and a weight of 40Kg. This work was approved by the Ethical Committee of the Veterinary Faculty of Las Palmas de Gran Canaria University. Animals were under clinical examination that included observation and palpation of the head. No external head lesions were seen in the two dogs used in this study. The dogs were sedated with 0.2mg/kg of acepromazine (Calmo Neosan; Pfizer, New York, USA) and anaesthetized with 15mg/kg intravenous of pentobarbital sodium (Braun, Braun Medical, Melsungen, Germany). Cone-Beam CT imaging was performed at the Human Radiodiagnostic Service of the San Roque Hospital of Las Palmas de Gran Canaria (Spain), with an-axial third generation CT equipment (General Electric Medical System®, Genesis Foreign, Tustin, CA, USA). Throughout the procedure, the dogs were positioned in ventral recumbency during scanning time. Contiguous transverse slices were acquired starting at the most rostral aspect of the external nares and continuing caudally up to the occipital condyles of the skull. CT images were obtained using the following parameters: 120kV, 200mA, 3 mm slice thickness and 3mm image spacing. The defined field of view was 25cm with a pixel matrix of 512x512. Scans were processed with a detailed algorithm to enhance bony structures using a wide window. The window width (WW) and window level were adjusted as required to achieve optimal images (WW=2639; WL=-567). The original data were stored and transferred to an image analysis workstation capable of generating 3D volume-rendered reconstructed images of the head, using a standard DICOM 3D format. 3D models have been reconstructed processing DICOM IMAGES by means of 3D Slicer, version 3.2. 3D slicer is an end-user application to process medical images and to generate 3D volumetric data set, which can be used to provide primary reconstruction images [17]. For volume rendered 3D CT-reformatted images WL was 163 and WW was 134.

CT images were compared to the corresponding osseous anatomic preparations and with anatomy literature [18-20] to identify the normal 3D CT anatomy of the bony structures of the canine head. According to an internationally accepted veterinary anatomical nomenclature [21], several cranial and facial bones, mandible and hyoid bone were identified.

3. RESULTS AND DISCUSSION

In this study, the results are presented in three figures. Fig. 1 is a volume rendered 3D-reformatted image of the lateral aspect of the canine head. Fig.2 is composed by two volume rendered 3D CT-reformatted images of the dorsal aspect Fig. 2A and the ventral aspect Fig. 2B. Fig. 3 is a volume rendered 3D-reformatted image of

the rostral aspect of the canine head. No internal head lesions were seen on CT images. Cranial and facial bones, mandible and hyoid bone have been evaluated and labelled according to location. In this study, several cranial bones such as the occipital bone (with their basilar part, lateral parts and squama), temporal (with their squamous, petrous and tympanic parts), the basisphenoid bone (body and wing), the presphenoid bone (body and wing), frontal bone (orbital part and squama) and the parietal bone could be identified. The paired frontal and parietal bones form the dorsum of the braincase. The parietal bone joints the frontal bone rostrally and it's fellow medially. Caudally, the parietal bone meets the occipital bone which forms the caudal surface of the skull. Rostral to the parietal bone, the frontal bone is observed, which forms the dorsomedial part of the orbit Fig. 1 and 2A. In addition, the sagittal crest is shown as a median ridge formed by the parietal and interparietal bones. Caudal structures such as the external occipital protuberance and the nuchal crest of the occipital bone are also identified. In the lateral surface of the skull Fig. 1, the squamous part of the temporal bone is well observed; it forms the ventral portion of the temporal fossa and bears the zygomatic process. In Fig. 2B, the ventral surface of the skull is observed, showing the ventral aspect of the braincase that is composed by the basilar part of occipital bone, tympanic and petrosal parts of temporal bone, the basisphenoid bone and the presphenoid bone.

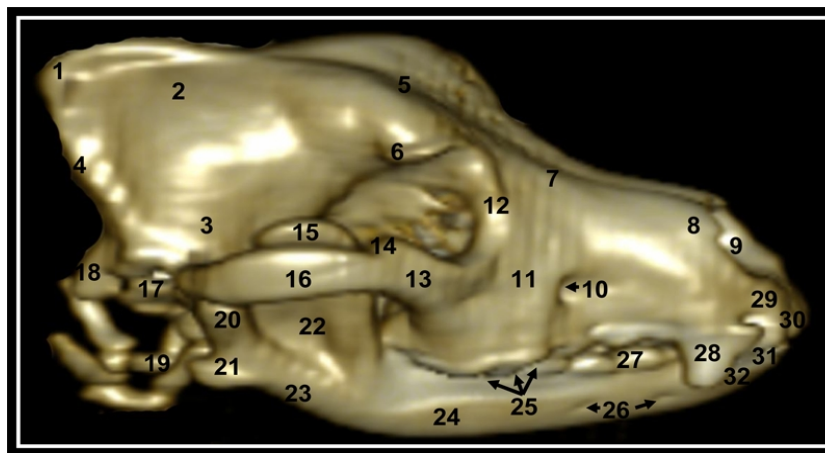


Fig. 1. Volume rendered 3D-reformatted image of the lateral aspect of the canine head 1, external occipital protuberance; 2, parietal bone; 3, squamous part of temporal bone; 4, nuchal crest; 5, frontal bone; 6, zygomatic process of frontal bone; 7, nasal bone; 8, rostral process of nasal bone; 9, nasal process of palatine bone; 10, infraorbital canal; 11, maxillary bone; 12, lacrimal bone; 13, temporal process of zygomatic bone; 14, frontal process of zygomatic bone; 15, coronoid process of mandible; 16, zygomatic process of temporal bone; 17, basilar part of occipital bone; 18, lateral part of occipital bone; 19, hyoid bone; 20, condylar process of mandible; 21, angular process of mandible; 22, masseteric fossa; 23, angle of the mandible; 24, molar part of mandible; 25, molars teeth; 26, mental foramina; 27, premolars teeth; 28, canine tooth; 29, body of incisive bone; 30, upper incisive teeth; 31, lower incisive teeth; 32, incisive part of mandible.

The facial part of the skull is composed by parts of the frontal bone (nasal part), external surface of the nasal bone, maxilla (with their facial surface, alveolar process, infraorbital canal and palatine process), the lacrimal bone (with their facial and orbital surfaces), zygomatic (with their facial and orbital surfaces, and the temporal and frontal processes), the palatine bone (with their perpendicular and horizontal plates), the vomer and the incisive bone (with their body, nasal and alveolar processes) were also visible in the figures.

In Figs. 1, 2B and 3, the molar (with their alveolar process) and incisive (with their alveolar process and mental foramina) parts of the body of mandible was clearly observed. In Fig. 1, on the lateral surface of the ramus of the mandible was clearly identified the triangular masseteric fossa for the insertion of the masseter muscle. In the dorsal half of the ramus could be seen the coronoid process, whereas in its ventral part the characteristic angular process was identified.

Other anatomic structures such as hyoid bone are observed especially in the Figs. 1 and 2A. However, it was difficult identified the molars, premolars, canine and incisive teeth in the corresponding figures.

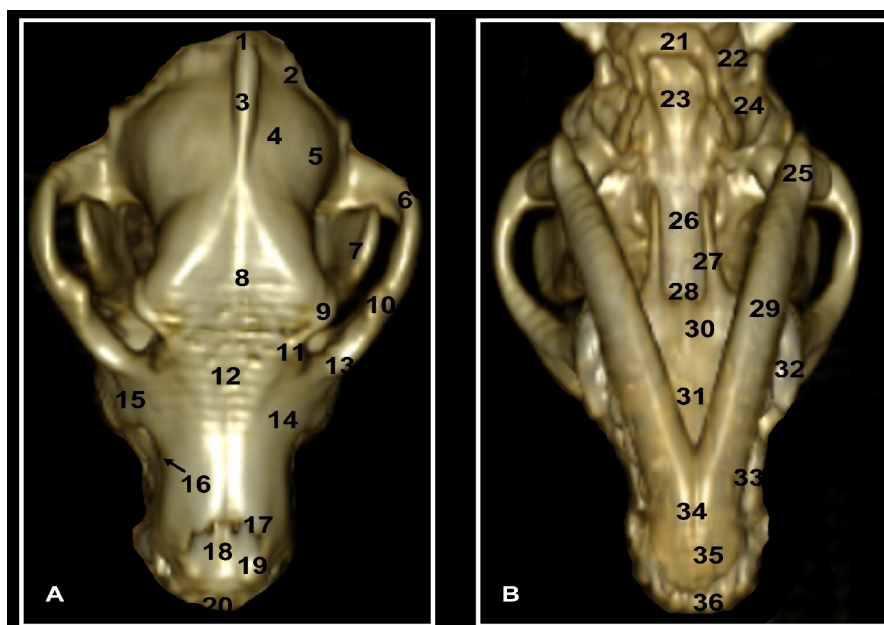


Fig. 2. Volume rendered 3D-reformatted images of the dorsal aspect (A) and the ventral aspect (B) of the canine head

1, external occipital protuberance; 2, nuchal crest; 3, external sagittal crest; 4, parietal bone; 5, squamous part of temporal bone; 6, zygomatic process of temporal bone; 7, coronoid process of mandible; 8, frontal bone; 9, zygomatic process of frontal bone; 10, frontal process of zygomatic bone; 11, lacrimal bone; 12, nasal bone; 13, zygomatic process of temporal bone; 14, maxillary bone; 15, zygomatic bone; 16, infraorbital canal; 17, rostral process of nasal bone; 18, vomer bone; 19, incisive bone; 20, upper incisive teeth; 21, hyoid bone; 22, lateral part of occipital bone; 23, basilar part of occipital bone; 24, petrous and tympanic parts of temporal bone; 25, angular process of mandible; 26, body of basisphenoid bone; 27, perpendicular plate of palatine bone; 28, body of presphenoid bone; 29, molar part of mandible; 30, horizontal plate of palatine bone; 31, palatine process of maxillary bone; 32, molars teeth; 33, premolars teeth; 34, interincisive joint; 35, incisive part of mandible; 36, lower incisive teeth.

To achieve the objective a free software used and tested in the healthcare sphere as the Osirix. The Osirix incorporates several mathematical algorithms implemented for processing and visualization of images. We have used the algorithm has the default Osirix for volume rendering reconstructions and the parameters used are the corresponding that has a default Osirix in its basic version. (manual or website) to find technical details of the algorithm. For us, since it is not the aim of the paper is not vital configure a volume rendering

reconstruction specified, but with a generic you enough for your anatomical description. For obtaining high definition 3D images, slices of 1mm in thickness and 1mm space are required, but in our case, the reason of this choice (3mm) was because we did a study of the entire dog body. It was done with the purpose to analyze the efficacy and definition of CT-images obtained with this thickness. The images obtained with these parameters allowed an anatomic identification of the main bony structures of the dog head.

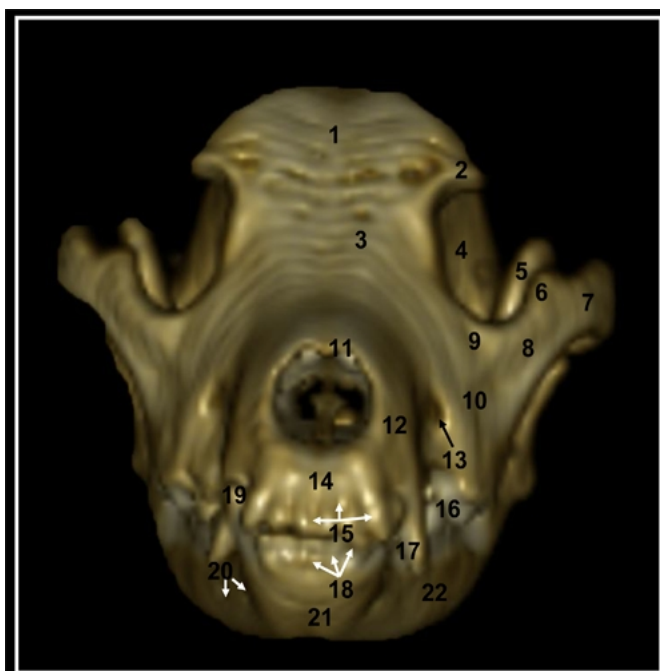


Fig. 3. Volume rendered 3D-reformatted image of the rostral aspect of the canine head

1, frontal bone; 2, zygomatic process of temporal bone; 3, external surface of nasal bone; 4, orbit; 5, coronoid process of ramus of mandible; 6, frontal process of zygomatic bone; 7, zygomatic process of temporal bone; 8, temporal process of zygomatic bone; 9, facial surface of zygomatic bone; 10, facial surface of maxillary bone; 11, rostral process of nasal bone; 12, nasal process of incisive bone; 13, infraorbital canal; 14, body of incisive bone; 15, upper incisive teeth; 16, premolar teeth; 17, upper canine tooth; 18, lower incisive teeth; 19, lower canine tooth; 20, mental foramina; 21, interincisive joint; 22, incisive part of body of mandible.

4. CONCLUSION

Advanced volume rendered 3D CT-reformatted images are excellent for the detailed assessment of the bony structures of canine head. The 3D CT reconstruction provides many anatomical details to identify the cranial and facial bones, mandible and hyoid bone. Volume rendered 3D CT images should provide initial anatomic reference for further anatomical and clinical CT imaging studies of the head of the dogs.

COMPETING INTERESTS

Authors have declared that no competing interests exist.

REFERENCES

1. George TF, Smallwood JE. Anatomic atlas for computed tomography in the metacephalic dog: Head and neck. *Vet Radiol Ultrasound*. 1992;33(4):217-240.
2. Probst A, Kneissl S. Computed tomography anatomy of the canine temporal bone. *Anat Histol Embryol*. 2006;35(1):19-22.
3. Parry AT, Volk HA. Imaging the cranial nerves. *Vet Radiol Ultrasound*. 2011;52(1):32-41.
4. Kraft SL, Gavin PR. Intracranial neoplasia. *Clin Tech Small Anim Pract*. 1999;14(2):112-123.
5. Bilderback AL, Faissler D. Surgical management of a canine intracranial abscess due to a bite wound. *J Vet Emerg Crit Care*. 2009;19(5):507-512.
6. Martin-Vaquero P, Moore SA, Wolk KE, Oglesbee MJ. Cerebral vascular hematoma in a geriatric cat. *J Feline Med Surg*. 2011;13(4):286-290.
7. Grossman C. *Magnetic resonance imaging and computed tomography of the head and spine*. Baltimore: Williams & Wilkins; 1990.
8. Kraus M, Mahaffey M, Girard E, Chambers J, Brown C, Coates J. Diagnosis of C5-C6 spinal luxation using three-dimensional computed tomographic reconstruction. *Vet Radiol Ultrasound*. 1997;38(1):39-41.
9. Dennison SE, Schwarz T. Computed tomographic imaging of the normal immature California sea lion head (*Zalophus californianus*), *Vet Radiol Ultrasound*. 2008;49(6):557-563.
10. Rodríguez MJ, Latorre R, López-Albors O, Soler M, Aguirre C, Vázquez JM, Querol M, Agut A. Computed tomographic anatomy of the temporomandibular joint in the young horse. *Equine Vet J*. 2008;40(6):566-571.
11. Zafra R, Carrascosa C, Rivero M, Peña S, Fernández T, Suárez-Bonnet A, Jaber JR. Analysis of equine cervical spine using three-dimensional computed tomographic reconstruction. *J App Anim Res*. 2012;40(2):108-111.
12. Drees R, Dennison SE, Keuler NS, Schwarz T. Computed tomographic imaging protocol for the canine cervical and lumbar spine. *Vet Radiol Ultrasound*. 2009; 50(1):74-79.
13. Saunders JH, van Bree H, Gielen I, de Rooster H. Diagnostic value of computed tomography with chronic nasal disease. *Vet Radiol Ultrasound*. 2003;44(4):409-413.
14. Zafra R, Carrascosa C, Suárez-Bonnet A, Melián C, Fernández T, Monzón M, Quesada O, Suárez F, Jaber JR. Three-dimensional reconstruction by computed tomography of an undifferentiated sarcoma in a dog. *J App Anim Res*. 2012;40(4):289-291.
15. Collard M, Dupont H, Noel G. New era of Neuroradiology: The transverse axial computed tomography TATC (Emi-Scanner) and its indications. *J Radiol*. 1975;56(6-7):453-469.
16. Ottesen N, Moe L. An introduction to computed tomography (CT) in the dog. *Eur J Compan Anim Pract*. 1998;8(1):29-36.
17. Frisardi G, Chessa G, Barone S, Paoli A, Razonale A, Frisardi F. Integration of 3D anatomical data obtained by CT imaging and 3D optical scanning for computer aided implant surgery. *BMC Med Imag*. 2011;11:5.
18. Vázquez Autón JM, Gil Cano F, Moreno Medina F, Latorre Reviriego R, Ramírez Zarzosa G. *Atlas en color. Anatomía veterinaria. Volumen I: Cabeza*. Murcia; Compobell SL; 1992.
19. Ruberte J, Sautet J. *Atlas of anatomy of the dog and cat. Head and neck*. Multimédica, Barcelona. 1995;1.

20. Sandoval J. Treaty of veterinary anatomy. Head and visceral systems. León: José Sandoval Juárez; 2000.
21. Schaller O. Illustrated veterinary anatomical nomenclature. 2nd edition. Enke, Stuttgart; 2007.

© 2014 Arencibia and Jáber; This is an Open Access article distributed under the terms of the Creative Commons Attribution License (<http://creativecommons.org/licenses/by/3.0>), which permits unrestricted use, distribution, and reproduction in any medium, provided the original work is properly cited.

Peer-review history:

The peer review history for this paper can be accessed here:

<http://www.sciencedomain.org/review-history.php?iid=441&id=22&aid=3905>