



Comparative Analysis of the Mollon-reffin Minimal Colour Vision Test in Visually ‘Normal’ and Acquired Ocular Disease

Hetan Ajwani¹, Carmel P. Noonan² and Fiona J. Rowe^{3*}

¹School of Medicine, University of Liverpool, Liverpool L69 3GB, UK.

²Department of Ophthalmology, Aintree University Hospital NHS Foundation Trust, Liverpool L7 9AL, UK.

³Department of Health Services Research, University of Liverpool, Liverpool L69 3GB, UK.

Authors' contributions

Author HA designed the study, performed the review and wrote the drafts of the manuscript.

Author CPN coordinated access to the subjects recruited for the patient group and contributed to the drafts of this manuscript. Author FJR provided oversight for the review and contributed to the drafts of the manuscript.

Original Research Article

Received 30th September 2013
Accepted 8th November 2013
Published 7th December 2013

ABSTRACT

Aim: Currently a variety of different colour vision tests exist in clinical practice each with its own merits and limitations. The Ishihara test is commonly used to test for congenital deficiency, causing red-green deficits. However acquired deficiency is also common in any ocular pathology affecting the optic nerve. The aim of this study is to compare the Mollon-reffin Minimal Test (MRMT) against the Ishihara and City colour vision tests.

Methods: All three tests were performed within the same clinic visit with a small rest between tests. The main parameters of interest were correlation levels between tests for defect detection, severity grading and defect type classification. We assessed the time taken to complete testing and evaluated the patients experience of test.

Results: We assessed 100 patients and 54 visually ‘normal’ subjects, with re-testing in the latter group to evaluate test-retest reliability. We found a reasonable level of agreement between the MRMT and the other tests once considering possible confounders for defect detection, severity grading and defect type classification in the patient group. There was a strong level of agreement in the visually normal group which suggests a high specificity relative to the other tests. The time taken to perform the MRMT

*Corresponding author: E-mail:rowef@liverpool.ac.uk;

is clinically acceptable in comparison to the City Test.

Conclusions: Patients experiences of the MRMT were positive and they preferred it to the other tests. We recommend that the MRMT be used detect colour vision defects or monitor deficiency, in patients with a significant visual field defect.

Keywords: Colour vision; city test; Ishihara test; mollon-reffin test; diagnostic accuracy.

1. INTRODUCTION

Normal colour vision perception is dependent on the presence of healthy cone photoreceptors in the retina and functional neural components to process a visual stimulus. Cone photoreceptors form different sub-populations correlating with the primary colours of red, green and blue. Each set of cones detects light within its own spectrum. The red spectrum cones are the most abundant cell population (74%), followed by cones that detect light in the green spectrum (16%) and finally cones which detect blue light (10%). The terms protan ('red' or long-wave), deutan ('green' or middle wave) and tritan ('blue' or short-wave) are used to describe the main colours detected by cones. Colour vision defects usually manifest as one of three types of abnormality; monochromacy, dichromacy or anomalous trichromacy respectively referring to the presence of one, two or three functional types of cone.

Colour vision deficiency (CVD) is one of the commonest disorders of vision, with its causes being either congenital or acquired. Congenital colour vision defects occur most frequently, and tend to affect the red-green colour perception. Congenital red-green colour blindness results from the absence of a single gene on the X chromosome and affects approximately 8% of men and 0.5% of women [1]. Blue-yellow colour blindness is more uncommon and is caused by an autosomal dominant mutation [2]. Acquired colour vision deficiency is the consequence of a variety of different ocular insults ranging from disease, trauma and drug toxicity [3]. The defects seen in congenital CVD affect both eyes equally and the defect remains consistent throughout a lifetime however acquired defects are usually monocular, the deficiency is progressive in severity and is often associated with reduced visual acuity and visual field defects [4,5]. Generally optic nerve lesions are characterized by defective protan/deutan (red/green) discrimination and retinal lesions by tritan (blue/yellow) defects [6,7]. Tritan defects are most commonly attributed to acquired causes. Depending on the extent of the deficiency, patients may be completely unaware of a subtle defect or suffer from handicap in their day to day activities [8]. Colour vision deficiency impacts many day to day activities including driving. Although full colour vision is not a legal requirement for drivers in the UK, one study has linked colour vision deficiency to an increased rate of road accidents [9].

Colour vision testing (CVT) is performed for a number of reasons including to; quickly screen for a defect, grade the severity of the defect, diagnose the type of defect or assess the significance of colour vision deficiency within a particular vocation [4,10]. CVT is often used as a marker of optic nerve function, alongside visual acuity, visual fields and contrast sensitivity measurements [11]. Clinical testing of colour vision can be performed through a variety of different approaches. All should take into account the patients age [12,13], ambient lighting [14], field size and cognitive issues [15]. One of the most popular methods to test for red-green CVD is the Ishihara colour vision test [16,17]. Ishihara plates are constructed of dots of varying hue and size, but similar apparent brightness allowing a normal individual to

distinguish a coloured numeral against a contrasting background. The abbreviated 24 plate version consists of 1 control plate, plates 2-9 are transforming numerals, 10-17 are vanishing numerals, 18-21 are hidden numerals and 22-25 are diagnostic of protan or deutan defects [18,19]. Figures on transforming plates are read differently by individuals with CVD in comparison to normal subjects. Only colour normal subjects can recognise the figure on a vanishing plate and only individuals with CVD can recognise the figure on a hidden plate. Diagnostic plates differentiate between protan and deutan defects once a patient has been identified to have a CVD during the screening section of the test. The test is quick to administer, inexpensive and widely available. Limitations of the Ishihara test are that it fails to test for tritan defects, protan/deutan defects cannot always be classified and the number of errors made is not a useful tool to grade the severity of a defect [16,20].

A further popular test is the City University Test which is a derivative of the Farnworth D-15 test, but in book form [21]. The test is divided into two parts: Part A is a screening tool that consists of triplets of colours, patients are required to state if all spots in each group are the same. Some triplets are made up of identical spots, but some contain an odd-one-out. Each plate displays four colour samples surrounding a central spot and the subject must choose the peripheral colour that resembles the central spot the closest. Each plate provides the opportunity for a normal response as well as protan, deutan and tritan deficient responses. The second edition of test is not robust in its differentiation of protan and deutan responses however the third edition has not yet been validated [16]. This test is useful for identifying tritan defect and using the number of errors made to grade the severity of a defect [22].

The Mollon-reffin Minimalist Test (MRMT) is a relatively new colour vision test and directly assesses the patient's chromatic discrimination along the protan, deutan and tritan confusion axes. There are six different saturations of the same hue along both the deutan and tritan axes, and five along the protan axis. The test specifically identifies and classifies the dichromatic type of inherited colour blindness and is recommended for examination of acquired CVD. The MRMT identifies all three major forms of CVD and provides an indication of severity by testing along dichromatic confusion lines which vary in chroma [23].

In the initial development of the MRMT, it was reported to be equivalent to the D-15 colour vision test for classification of dichromatic defects and able to distinguish between protanopes and deutanopes [23]. It was thus proposed as suitable for examining acquired colour vision defects (for detection and monitoring purposes) and reported as a simple test to administer. The MRMT test was subsequently evaluated in a study of children aged 3 to 10 years and older subjects aged 11 to 39 years and further recommended as useful for detecting and monitoring acquired colour vision defects in younger age groups. Notably there was a significant difference found in performance between tests. All children were able to complete the MRMT test whereas 90% completed the Pease-Allen colour test and 88% completed the Hardy Rand Rittler test [24]. The MRMT was later compared to the Farnsworth-Lanthonydesaturated D-15 test in a population of type I diabetic patients with or without macular oedema. This study found a significant correlation, with high sensitivity and specificity, between the tritan value of the test and the presence of clinically significant macular oedema. Conversely the DD-15 test was not significantly correlated, with low sensitivity for the presence of macular oedema. The difference in performance of the two tests was attributed to the MRMT test assessing the tritan axis separately and directly along the confusion line whereas the DD-15 test only identified the confusion axis for blue-yellow defects. The authors recommended the MRMT as a useful test in the screening and follow-up examination for macular oedema in young diabetic patients [25].

The aims of this study are to assess the clinical effectiveness of the MRMT in comparison to other colour vision tests that are standardly used in our clinical practice in patients attending routine appointments in general or neurological ophthalmology clinics. We performed this study to:

- Compare the level of absolute agreement between tests as determined by the average intraclass correlation coefficient (ICC) for: colour vision defect detection, colour defect severity grading and identification of particular types of colour vision defects.
- Compare the time taken to complete each test for all participants in the patient population and a proportion of the visually normal population.
- Explore the patient group's experience of each test qualitatively by asking patients about their perceptions of the tests.

2. MATERIALS AND METHODS

2.1 Visually Normal Population

Fifty-four participants (108 eyes) without any known ophthalmic or neurological pathology voluntarily took part in this study. None of them complained of any CVD prior to testing. The visually normal subjects were recruited through the Directorate of Orthoptics and Vision Science of the University of Liverpool. All three tests were performed consecutively in the same testing session lasting no more than 20 minutes. The tests were completed in random order to prevent order effects and with a rest time of 3-5 minutes between each test. As acquired defects have a tendency to affect one eye, all testing was conducted monocularly by occluding the opposite eye. Twenty participants (40 eyes) were chosen randomly for retesting on a separate visit following initial assessment.

2.2 Patient Population

One hundred study subjects (197 eyes) were recruited through the Department of Ophthalmology at Aintree University Hospital. This was a pragmatic clinical study recruiting patients attending routine ophthalmology appointments. Patients with confirmed posterior eye disease, such as optic nerve atrophy or papilloedema were identified randomly upon clinic attendance and invited to take part in the study. Patients who were unable to follow instructions for performing the test or too ill to complete the assessment were excluded. Patient demographic details were recorded along with details of clinical diagnosis, level of visual acuity and if any significant visual field defect was present (>50% field loss). Again all tests were completed in the same testing session, with test scores and test duration being recorded for each assessment. The tests were completed in a set order (1: Ishihara, 2: City, 3: MRMT) and with a rest time of 3-5 minutes between each test. At the end of the testing session patients were asked "which test did you prefer to complete?" and "which test did you find the easiest to perform?"

2.3 Ishihara Test

The 24 plate edition (1977) test was used as per standard test protocol. Patients were shown the test plates at arms length and given 4 seconds to respond to each plate. Misread plates were viewed for a second time to allow the opportunity to correct the error. Incorrect responses were recorded when a number was missed or wrongly identified after the second

attempt. Normal patients were defined as those with 0 errors. Mild CVD was defined as four or more incorrect responses [26], moderate deficiency as 5-7 and severe as a score >8.

2.4 City University

The third edition of the test (1998) was used for testing. A normal score for part A would be 10-9, a mild defect would score 8-6, a moderate defect 5-3, and a severe defect 1-2. Defect severity is also assessed by combining the score obtained in part A with that of part B [27].

2.5 Mollon-reffin

MRMT version 6.0 was the final assessment that participants were asked to complete. The testing kit comes with nine grey chips, a set of coloured probe chips (6 deutan, 6 tritan and 5 protan) and an orange demonstration chip. The orange demonstration chip is mixed in amongst five grey chips and the participant is asked to differentiate it from the grey background chips. One chip would then be selected from the middle of each colour spectrum and mixed amongst the grey background chips. If successfully identified, then a less saturated chip would be chosen along the same confusion axis. If unsuccessful, a more saturated probe chip would then be used. Using the deutan chip set as an example, the least saturated chip is numbered 1 and the most heavily saturated chip is numbered 6. The participant would use pointer to identify chips, preventing tarnishing of the chip colours. Participants with normal colour vision should identify chip 1, in mild deficiency they would identify 2, in moderate deficiency 3-4 and in severe deficiency chips 5-6 would be identified, if any at all [23].

2.6 Data Collection and Statistical Analysis

All results were recorded in numerical format to protect subject and patient confidentiality. SPSS version 20 was used to perform intraclass correlation coefficient analysis to establish the level of agreement between results. 95% confidence intervals were calculated for all limits of agreement.

2.7 Ethical Approval

This study received full ethical approval from the National Research Ethics Service, Aintree University Hospital NHS Foundation Trust and the University of Liverpool.

3. RESULTS AND DISCUSSION

3.1 Study Demographics

The visually normal group consisted of 54 subjects (108 eyes) with a mean age of 25 years (range 19 to 54). There were 15 males and 39 females. The patient group consisted of 100 subjects (197 eyes) with a mean age of 45 years (range 11 to 90). There were 32 males and 68 females.

Table 1 outlines the clinical characteristics of the study population. The visually normal group did not report any ophthalmological pathology at the time of testing. The patient group was noticed to have eight patients with a bilateral visual field defect.

Table 1. Demographic and clinical characteristics of the study population

Variable	Patient group		Visually normal group	
	(N=100, 197 eyes)		(N=54, 108 eyes)	
Diagnosis				
• Idiopathic intracranial hypertension (iih)	25		N/A	
• Space occupying lesion	16		N/A	
• Hydrocephalus	7		N/A	
• Vascular (infarct/haemorrhage)	4		N/A	
• Optic neuropathy	10		N/A	
• Other miscellaneous diagnosis	11		N/A	
• Unknown	27		N/A	
Logmar Visual Acuity (VA)	OD	OS	OD	OS
• ≤ 0.0	50	53	50	50
• ≤ 0.5	31	33	4	4
• ≤ 1.0	12	10	0	0
• Hand movements	1	3	0	0
• No perception of light	1	2	0	0
Bilateral Visual Field Defect Present*	OD	OS	OD	OS
	8	8	0	0

* Visual field defect classified as >50% visual field loss after investigation with perimetry.
OD: Right eye, OS: Left eye

3.2 Colour Vision Defect Detection

The visually normal group statistical analysis shows a strong level of absolute agreement, ICC value >0.9, when comparing the ability of each test to detect a colour vision defect. The patient group showed some correlation in the ability of the MRMT to detect defects when compared to the City test (Fig. 1). The ICC values were 0.77 (95% CI 0.65-0.85) and 0.71 (95% CI 0.56-0.81), for the right and left eyes respectively. The correlation between the MRMT and the Ishihara test for defect detection was reduced in the right eye, 0.43 (95% CI 0.2-0.65) and of a similar level to the other test for the left eye, 0.71 (95% CI 0.56-0.81).

3.3 Colour Vision Severity of Defect

Participants in the visually normal group did not exhibit any defects on any of the three tests. In the patient group, correlation between tests for severity agreement was generally reduced. In comparison to the Ishihara test the ICC value was 0.57 (95%CI 0.35-0.72) and 0.73 (95%CI 0.58-0.82) for the right and left eyes respectively (Fig. 2). Again, the City Test showed reduced levels of correlation: 0.61 (95%CI 0.40-0.75) for analysis of patient's right eyes and 0.50 (95%CI 0.24-0.68) for the left eye analysis.

3.4 Colour Vision Type of Defect

Type of colour vision defect involves the classification of any detected colour vision deficiencies into a particular defect form, i.e. protan, deutan and tritan. Classifications were made for the patient group only. The City Test analysis results showed the MRMT to have an ICC value of 0.72 (95% CI 0.58-0.82) and 0.76 (95% CI 0.64-0.85) for the left and right

eyes tested in the patient group (Fig. 3). The Ishihara test showed reduced correlation for the left eyes tested: ICC values of 0.48 (95% CI 0.22-0.66,) and a stronger level of correlation with the right eyes tested, 0.76 (95% CI 0.63-0.84).

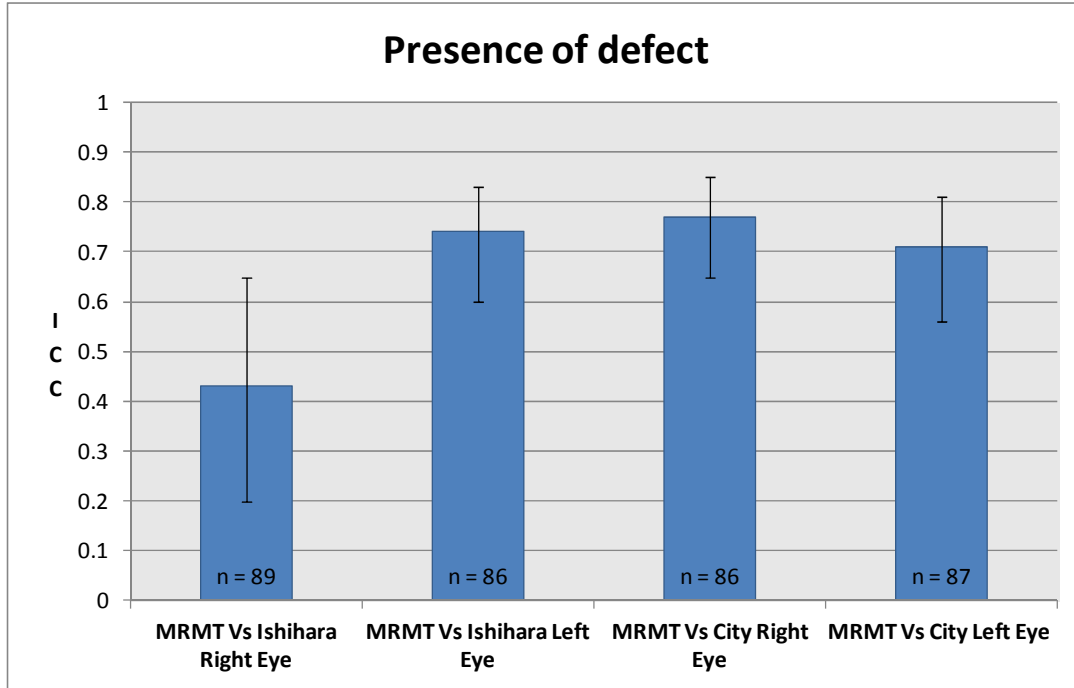


Fig. 1. The level of absolute agreement between tests as determined by the average intraclass correlation coefficient (ICC) for colour vision defect detection. Error bars show 95% confidence intervals for each ICC value. (n = number of patients successfully completing testing with right/left eye).

3.5 Test Duration

Table 2 shows that in both visually normal and patient groups, the Ishihara test on average was the fastest to complete, taking 57.5s (+/-44.3) in the patient group and 35.9s (+/-35.9) in the visually normal group. The MRMT was second fastest in the patient group taking 72.5s (+/-42.8) and marginally slower to the City Test in the visually normal group taking 53.8 (+/-7.8). The standard deviations of the patient group are much greater due to subjective differences such as underlying diagnosis and differences in visual acuity, visual field defects and age.

Table 2. Average time taken for study participants to complete individual tests per eye in seconds (+/-SD)

	Average time: Patient group (s)	Average time: Visually normal group (s)
Ishihara test	57.5 (+/-44.3)	35.9 (+/-5.3)
City test	89.1 (+/-50.9)	53.8 (+/-7.8)
Mollon-reffin test	72.5 (+/-42.28)	55.7 (+/-5.5)

S: Seconds

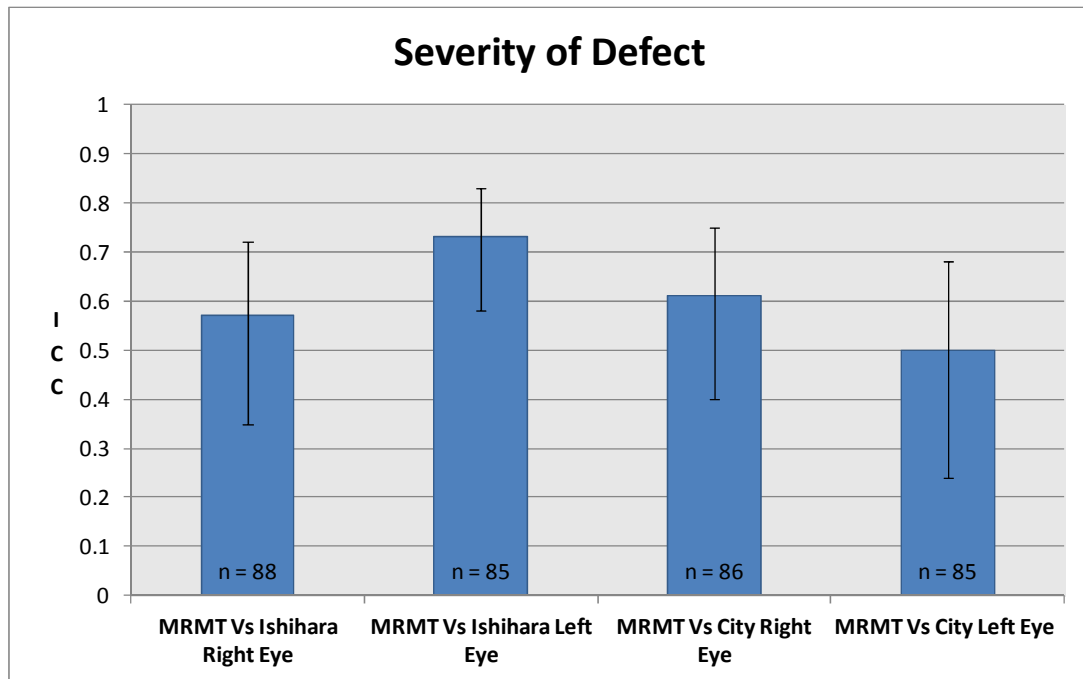


Fig. 2. The level of absolute agreement between tests as determined by the average intraclass correlation coefficient (ICC) for defect severity detection. Error bars show 95% confidence intervals for ICC each value. (n = number of patients successfully completing testing with right/left eye).

3.6 Test Completion

All subjects in the visually normal group were able to complete all three colour vision tests. A number of subjects in the patient group could not complete all colour vision tests. Seven failed to complete the Ishihara test, seven failed to complete the City test and three were unable to complete the MRMT. These patients typically had visual acuity of worse than 6/60 Snellen/1.0 logMAR and greater than 50% visual field loss bilaterally.

3.7 Patient Preference

Qualitative measures of patient testing experiences were obtained throughout the study. Ninety percent of patients preferred the MRMT and 97% of patients found the MRMT the easiest test to complete.

The aim of this study was to directly compare the ability of the MRMT to detect CVD, defect severity and type of defect firstly in a visually normal cohort and secondly in a patient group attending routine ophthalmology appointments. The visually normal group showed a high level of absolute agreement, ICC >0.9, during both initial testing and re-testing. In the patient group this first parameter showed a reasonable level of agreement, ICC >0.70, between the MRMT and right/left eye city comparisons. This is intuitive as they both detect the same set of defects, specifically acquired tritan defects [23,28]. By contrast, the lowest level of agreement was observed with the right eye MRMT vs. Ishihara comparison, giving

an ICC value of only 0.43 (0.20-0.65). Of note here is the fact that eight patients tested positive for mild defects on the MRMT without showing any defect on the Ishihara test. It is likely that the ability of the MRMT to detect subtle CVD may have accounted for this difference. We did not find an explanation as to why this difference was found for the right eye and not the left eye also. Level of visual acuity, visual field loss or extent of ocular disease was not more in the right than the left eyes.

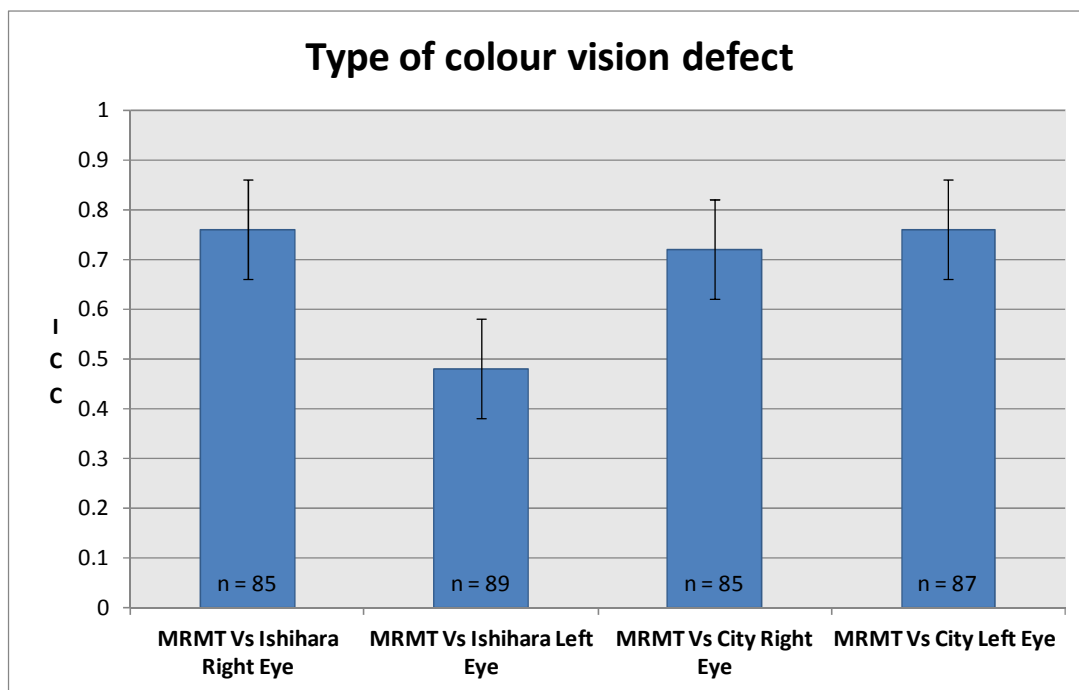


Fig. 3. The level of absolute agreement between tests as determined by the average intraclass correlation coefficient (ICC) for the type of colour vision defect. Error bars show 95% confidence intervals for ICC each value. (n = number of patients successfully completing testing with right/left eye)

It is well known that the number of errors made on the Ishihara test is not a reliable indicator of defect severity [4,29]. We have attempted to utilise this as a means of drawing comparison between the MRMT and Ishihara for defect severity. Even with this caveat, we did notice some correlation with the left Ishihara defect severity and the MRMT. However its ability to detect subtle differences may again account for the reduced correlation levels in the right eye comparison. The ICC value for both right and left city severity comparisons were below 0.70. The severity grading itself showed that the City test was identifying a greater proportion of mild defects when the MRMT was identifying the same patients as normal. As before, we found no differences in visual acuity, visual field loss or extent of ocular disease to explain the discrepancies between right and left eye comparisons.

The average ICC value for the type of defect correlation was >0.70 for all comparisons except MRMT left vs. Ishihara left: for this the value was 0.48 (0.22-0.66). This group had five tritan defects that will not have been detected by the Ishihara test accounting for the weaker correlation in this comparison.

Aside from the diagnostic accuracy of any test, its clinical value is also dependent upon the amount of time it takes to perform. Our timing of the tests showed that the Ishihara test was the quickest in both groups, with little difference between the MRMT and City test in the visually normal group taking <1 minute to complete on average. The MRMT was quicker on average in comparison to the City test in the patient group. However the standard deviations were large due to individual variation. One study by Thyagrajan et al. [30] also showed the Ishihara to be the quickest to complete. Interestingly the purpose of this group's study was to investigate the effect of visual acuity and refractive error on CVT. They found that different tests vary in their threshold acuity at which the accuracy of test results becomes affected. McCulley et al. [31] also considered the factor of a threshold acuity.

As declining visual acuity, field loss and CVDs occur alongside one another in many cases of optic nerve pathology we decided to investigate the impact of visual field defects on ability to complete testing. We are not aware of any previous work that has looked into this specific area of CVT. Our patient group included eight subjects with a VA of worse than 6/60 and a bilateral visual field defect affecting more than 50% of the field. Of this group six patients were unable to complete both the Ishihara and City test; in contrast all members of this group were able to complete the MRMT. The Ishihara test requires patients to have a sufficient visual field to detect the numeral or numerals on each plate, and completion of the City test is dependent on all triplet dots being in the field of view at the same time. Conversely, the MRMT only requires patients to be able to identify one relatively large coloured chip amongst a series of control chips. The larger coloured chips used in the MRMT may make it the most suitable CVT for patients with moderate to severe visual field loss which may be impairing performance in other tests.

Qualitative feedback from the patient group on each testing method provides an insight into the clinical acceptability of the MRMT. The vast majority of patients preferred the MRMT (90%), and also considered it the easiest task to complete (97%). This is consistent with the findings of Shute et al. [24] who recommend the test for young children due to its simplicity and intuitive design. This feature is important as the cognitive capability of a patient and the complexity of a test should be considered on an individual basis so that they may do as well as is subjectively possible [32].

4. CONCLUSION

Our study shows a reasonable level of agreement between the MRMT, the Ishihara test and City test after considering possible confounders for colour defect detection, severity grading and defect type classification in the patient group. There is a strong level of agreement in the visually normal group which suggests a high specificity relative to the other tests. The time taken to perform the MRMT is clinically acceptable in comparison to the City Test. Patients experiences of the MRMT are positive and the MRMT was preferred to the other tests. Notably, patients were able to complete the MRMT when unable to complete the Ishihara and/or City test. This was particularly applicable to the small group with visual field loss. Our recommendations are that the MRMT test is a useful and simple to administer test for the detection and monitoring of colour vision defects in general and neurological ophthalmology clinics and is particularly useful for assessment of patients with a significant visual field defect. It will serve as a useful addition to the assessment armamentarium in ophthalmology clinics.

CONSENT

All authors declare that informed consent was obtained from the patient prior to taking part in this study.

ETHICAL APPROVAL

All authors hereby declare that all experiments have been examined and approved by the appropriate ethics committee and have therefore been performed in accordance with the ethical standards laid down in the 1964 Declaration of Helsinki.

ACKNOWLEDGEMENTS

Financial Disclosure: No funding was provided for the conduct of this review.

We would like to extend our gratitude to all study participants for giving up their time to take part and the Aintree Department of Ophthalmology for helping with patient recruitment and providing support and assistance when needed.

COMPETING INTERESTS

The authors have declared that no competing interests exist.

REFERENCES

1. Deeb SS. The molecular basis of variation in human color vision. *Clinical Genetics*. 2005;67(5):369-77.
2. Neitz M, Mancuso K, Neitz J. *Colour Vision Defects*. In: eLS. John Wiley & Sons, Ltd.; 2001.
3. Formankiewicz M. Acquired Colour Vision Deficiencies. *Optometry Today: Parts I-IV*. 2009;6.
4. Melamud A, Hagstrom S, Traboulsi E. Color vision testing. *Ophthalmic Genetics* 2004;25(3):159-87.
5. Birch J. *Diagnosis of Defective Colour Vision*: Butterworth-Heinemann. 1993:187.
6. Purvin V. Optic neuritis. *Current opinion in ophthalmology*. 1998;9(6):3-9.
7. Eisner A, Fleming SA, Klein ML, Mauldin WM. Sensitivities in older eyes with good acuity: cross-sectional norms. *Investigative ophthalmology & visual science*. 1987;28(11):1824-31.
8. Spalding JA. Colour vision deficiency in the medical profession. *The British Journal of General Practice*. 1999;49(443):469.
9. Verriest G, Neubauer O, Marre M, Uvijls A. New investigations concerning the relationships between congenital colour vision defects and road traffic security. *International ophthalmology*. 1980;2(2):87-99.
10. Gordon N. Colour blindness. *Public Health*. 1998;112(2):81-4.
11. Kanski JJ, Bowling B. *Clinical Ophthalmology: A Systematic Approach*: Saunders; 2011.

12. Verriest G. Further Studies on Acquired Deficiency of Color Discrimination. *Journal of the Optical Society of America*. 1963;53(1):185-&.
13. Beirne RO, McIlreavy L, Zlatkova MB. The effect of age-related lens yellowing on Farnsworth-Munsell 100 hue error score. *Ophthalmic and Physiological Optics*. 2008;28(5):448-56.
14. Dain S, Pereira S, Palmer B, Lewis P, Hammond T. Illuminance and the FM 100 hue test. *Colour Deficiencies V*. Adam Hilger, London. 1980:162-3.
15. Rodgers M, Hodges R, Hawkins J, Hollingworth W, Duffy S, McKibbin M, et al. Colour vision testing for diabetic retinopathy: a systematic review of diagnostic accuracy and economic evaluation; 2009.
16. Dain SJ. Clinical colour vision tests. *Clin Exp Optom*. 2004;87(4-5):276-93.
17. Thiadens AAHJ, Hoyng CB, Polling JR, Bernaerts-Biskop R, van den Born LI, Klaver CCW. Accuracy of Four Commonly Used Color Vision Tests in the Identification of Cone Disorders. *Ophthalmic Epidemiology*. 2013;20(2):114-22.
18. Ishihara S. Test for Colour-Blindness; 1960.
19. Formankiewicz M. Assessment of colour vision. *Optometry Today*. 2009;49(20):28-35.
20. Cole BL. Assessment of inherited colour vision defects in clinical practice. *Clinical and Experimental Optometry*. 2007;90(3):157-75.
21. Fletcher R. Methods of examination of macular colour vision. A modified D-15 test. *Mod Probl Ophthalmol*. 1972;11:22-4.
22. Birch J. Clinical use of the City University Test (2nd edition). *Ophthalmic and Physiological Optics*. 1997;17(6):466-72.
23. Mollon JD, Astell S, Reffin JP. A minimalist test of colour vision. In: Drum B, Moreland JD, Serra A (eds). *Documenta Ophthalmological Proceedings Series. Colour vision deficiencies X*, vol 54. Kluwer Academic Publications, Dordrecht. 1991;59-67.
24. Shute RH, Westall CA. Use of the mollon-reffin minimalist color vision test with young children. *Journal of American Association for Pediatric Ophthalmology and Strabismus*. 2000;4(6):366-72.
25. Maar N, Tittl M, Stur M, Zajic B, Reitner A. A new colour vision arrangement test to detect functional changes in diabetic macular oedema. *British Journal of Ophthalmology*. 2001;85:47-51
26. Cole BL, Lian KY, Lakkis C. The new Richmond HRR pseudoisochromatic test for colour vision is better than the Ishihara test. *Clinical and Experimental Optometry*. 2006;89(2):73-80.
27. Fletcher R. *The City University colour vision test*; 1980.
28. Heron G, Erskine NA, Farquharson E, Moore AT, White H. Color-Vision Screening in Glaucoma - the Tritan Album and Other Simple Tests. *Ophthalmic and Physiological Optics*. 1994;14(3):233-8.
29. Rodriguez-Carmona M, O'Neill-Biba M, Barbur JL. Assessing the severity of color vision loss with implications for aviation and other occupational environments. *Aviation and Space Environment Medicine*. 2012;83:19-29.
30. Thyagarajan S, Moradi P, Membrey L, Alistair D, Laidlaw H. Technical Note: The effect of refractive blur on colour vision evaluated using the Cambridge Colour Test, the Ishihara Pseudoisochromatic Plates and the Farnsworth Munsell 100 Hue Test. *Ophthalmic and Physiological Optics*. 2007;27(3):315-9.

31. McCulley TJ, Golnik KC, Lam BL, Feuer WJ. The effect of decreased visual acuity on clinical color vision testing. *American Journal of Ophthalmology*. 2006;141(1):194-6.
32. Lakowski R. Theory and practice of colour vision testing: A review. Part 2. *British Journal of Industrial Medicine*. 1969;26(4):265-88.

© 2014 Ajwaniet al.; This is an Open Access article distributed under the terms of the Creative Commons Attribution License (<http://creativecommons.org/licenses/by/3.0>), which permits unrestricted use, distribution, and reproduction in any medium, provided the original work is properly cited.

Peer-review history:
The peer review history for this paper can be accessed here:
<http://www.sciencedomain.org/review-history.php?iid=369&id=23&aid=2679>