



## Unilateral Proptosis Due to Orbital Malignancy and Synchronous Carcinoma Elsewhere

Shashi Ahuja<sup>1\*</sup>, K. Praveen Kumar<sup>1</sup>, N. G. Rajesh<sup>2</sup>, Praveen Seth<sup>1</sup> and Debadutt Basu<sup>2</sup>

<sup>1</sup>Department of Ophthalmology, JIPMER, Puducherry, India.

<sup>2</sup>Department of Pathology, JIPMER, Puducherry, India.

### Authors' contributions

*This work was carried out in collaboration between all authors. Author SA was the Critical evaluation of the manuscript. Author NGR managed the Gastric pathology workup and its photography and author KPK managed the Clinical workup and author PS identified the Laboratory investigation including the imaging studies and author DB managed the Eye pathology workup and its photography. All authors read and approved the final manuscript.*

Case Study

Received 27<sup>th</sup> June 2013  
Accepted 15<sup>th</sup> November 2013  
Published 14<sup>th</sup> January 2014

### ABSTRACT

**Introduction:** Unilateral proptosis is usually a diagnostic challenge to an ophthalmologist. Mass lesions constitute a common cause of unilateral proptosis in elderly individuals in which lymphoproliferative lesions account for 11% and metastasis up to 2-9% of cases. Literature review showed various tumors metastasizing to the orbit but simultaneous presence of two unrelated tumors in a person are extremely uncommon. The authors wish to report the same to highlight the importance of systemic examination in an elderly patient presenting as unilateral proptosis.

**Case Presentation:** A 52 year old man presented with complaints of painless, gradually progressing prominence of his right eye (OD) for 8 months. OD showed about 15 degrees of exotropia. Examination revealed an axial proptosis of 6mm by Hertel's exophthalmometry. It was non-tender and non-pulsatile. CT scan of the orbit revealed OD proptosis with enhancing soft tissue attenuation lesion involving extraconal and intraconal compartments in superolateral aspect of the right orbit abutting proximal portion of the right optic nerve. Lacrimal gland could not be distinguished separately from the lesion

\*Corresponding author: E-mail: drshashiahuja@gmail.com;

Lacrimal gland biopsy revealed stratified squamous epithelium with subepithelial infiltration by monomorphic population of small lymphoid cells and few immunoblasts suggesting a low grade lymphoproliferative lesion. Immunohistochemical study confirmed a diagnosis of small lymphocytic lymphoma.

Abdominal ultrasound performed for assessment of intraabdominal lymph nodes or visceral enlargement showed diffuse thickening. An endoscopic antral biopsy revealed gastric adenocarcinoma on histopathological examination.

**Conclusion:** Diagnosis of two synchronous neoplasms of different etiopathogenesis at two sites and exclusion of metastasis is a significant and under-recognized clinical problem. This case highlights the importance of high index of clinical suspicion and thorough systemic examination in the evaluation of a case of unilateral proptosis in an elderly male.

*Keywords: Proptosis; lymphoproliferative malignancy; gastric adenocarcinoma; double malignancy.*

## 1. INTRODUCTION

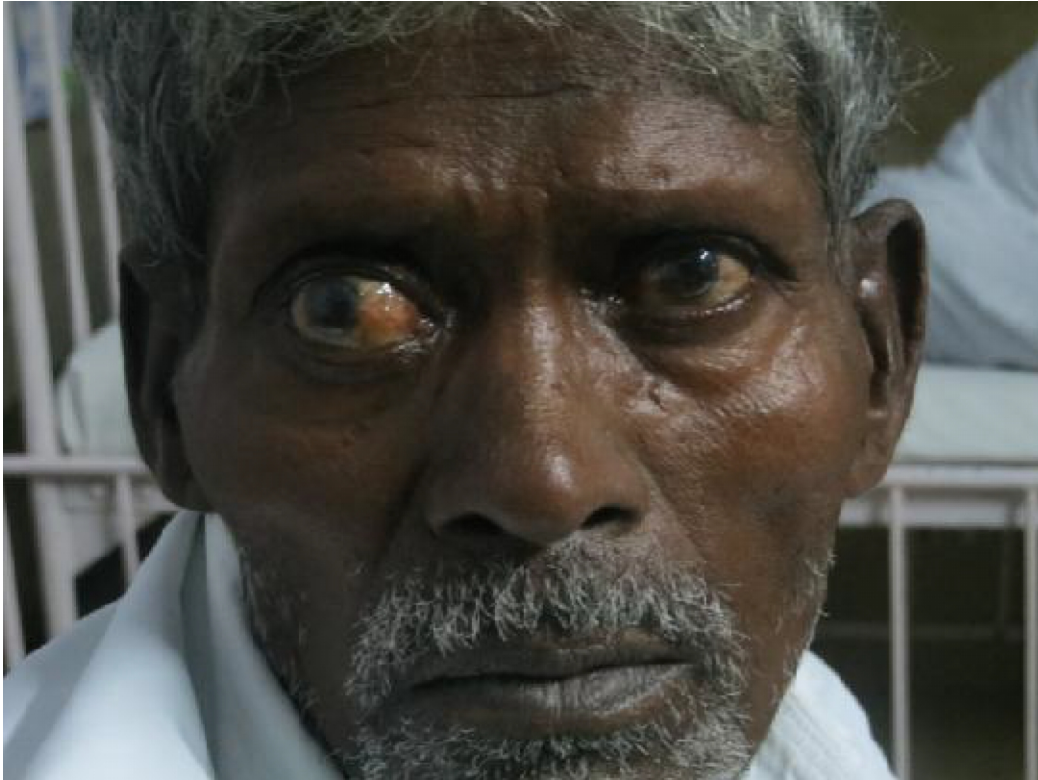Unilateral proptosis is usually a diagnostic challenge to an ophthalmologist. The causes vary to a large extent with Graves' ophthalmopathy contributing to 47% and mass lesions making up to 53% of the total cases. Mass lesions constitute a common cause of unilateral proptosis in elderly individuals in which lymphoproliferative lesions account for 11% of cases and metastasis make up to 2- 9% of cases [1,2,3]. Most tumors metastasizing to the eye are carcinomas, although sarcomas, lymphoproliferative malignancies, and melanomas have also been reported. The most common primary carcinomas metastasizing to the orbit are from breast, lung, gastrointestinal tract, genitourinary tract, thyroid, adrenal glands, and cutaneous malignant melanoma. [4,5]. The presenting signs in patients with metastasis to the orbit include proptosis or a painful, palpable mass and ophthalmoplegia. Less common signs of metastatic orbital tumors include diminution of vision, choroidal folds or an afferent pupillary defect.[6] Review of literature showed various tumours metastasizing to the orbit but simultaneous presence of two unrelated tumors in a patient has not been reported. The authors wish to report the same to highlight the importance of systemic examination in unilateral proptosis in elderly.

## 2. CASE REPORT

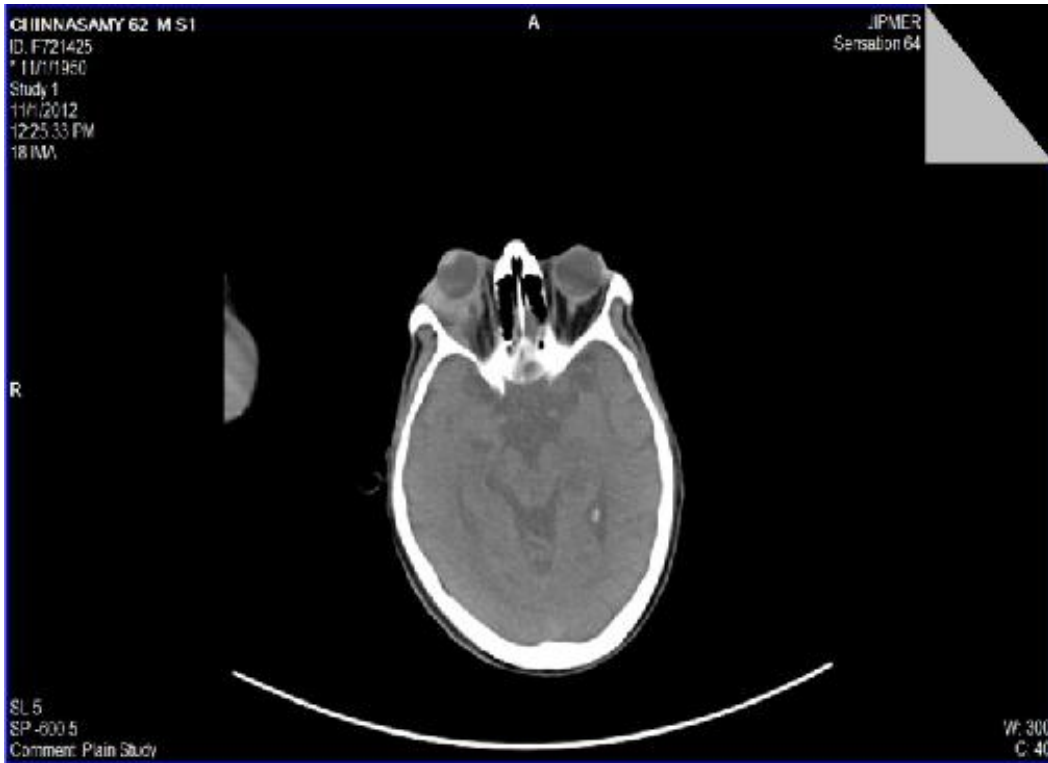A 52 year old male presented with complaints of painless, gradually progressing prominence of right eye for 8 months [Fig. 1]. There was history of squinting of right eye since childhood. There was history of significant weight loss over the past 6 months. On examination his best corrected visual acuity in the right eye was 20/120 and in the left eye was 20/40. There was 15 degrees of exotropia in the right eye. Right eye examination revealed an axial proptosis of 6mm by Hertel's exophthalmometry. It was non tender and non pulsatile . Auscultation did not reveal any bruit over the swelling. Anterior segment examination was within normal limits except for a cataractous lens. Fundus was within normal limits. Left eye examination was within normal limits with a posterior chamber intraocular lens. Systemic examination was within normal limits. CT scan of the orbits revealed right eye proptosis with enhancing soft tissue attenuation lesion involving extraconal and intraconal compartments in superolateral aspect of the right orbit abutting proximal portion of the right optic nerve. All extraocular muscles were involved by the lesion and lacrimal gland could not be distinguished

separately from the lesion [Fig. 2]. Lacrimal gland biopsy revealed stratified squamous epithelium with subepithelial infiltration by monomorphic population of small lymphoid cells and few immunoblasts suggesting a low grade lymphoproliferative lesion. Immunohistochemistry was performed for panel of small 51 cell Non Hodgkin's lymphoma and the panel comprised of CD3, CD20, CD5, CD 23, and Cyclin D1. The lymphoid cells were negative for Cyclin D1 and CD3 while the rest of the markers were positive confirming the diagnosis of small lymphocytic lymphoma [Fig. 3].

Systemic examination was normal. His thyroid function tests revealed a normal thyroid profile. Abdominal ultrasound performed for assessment of intra-abdominal lymph nodes or visceral enlargement showed diffuse thickening. An endoscopic antral biopsy revealed intestinal type of gastric adenocarcinoma on histopathological examination [Fig. 4]. The patient was advised gastric surgery and chemotherapy for further management. The patient refused treatment and was lost to follow-up.



**Fig. 1. Clinical Photograph showing right Eye Proptosis**



**Fig. 2. CT scan of the orbit revealed right eye proptosis with enhancing soft tissue attenuation lesion involving extraconal and intraconal compartments in superolateral aspect of the right orbit abutting proximal portion of the right optic nerve. All extraocular muscles were involved by the lesion and lacrimal gland could not be distinguished separately from the lesion**

### 3. DISCUSSION

Mass lesions constitute one of the common causes of unilateral proptosis in the elderly, out of which lymphoproliferative lesions account for 11% and metastasis account for 2-9% of cases. Orbital lymphoma and lymphoma of the orbital adnexae are relatively rare, representing 0.1% of all lymphomas [7]. Lymphomas of B-cell lineage are more likely to be associated with ocular symptoms and orbital extension than lymphomas of T-cell or NK-cell lineage [8]. Orbital metastases are generally associated with a bad prognosis and most patients succumb to widespread systemic disease within months [9,10,11].

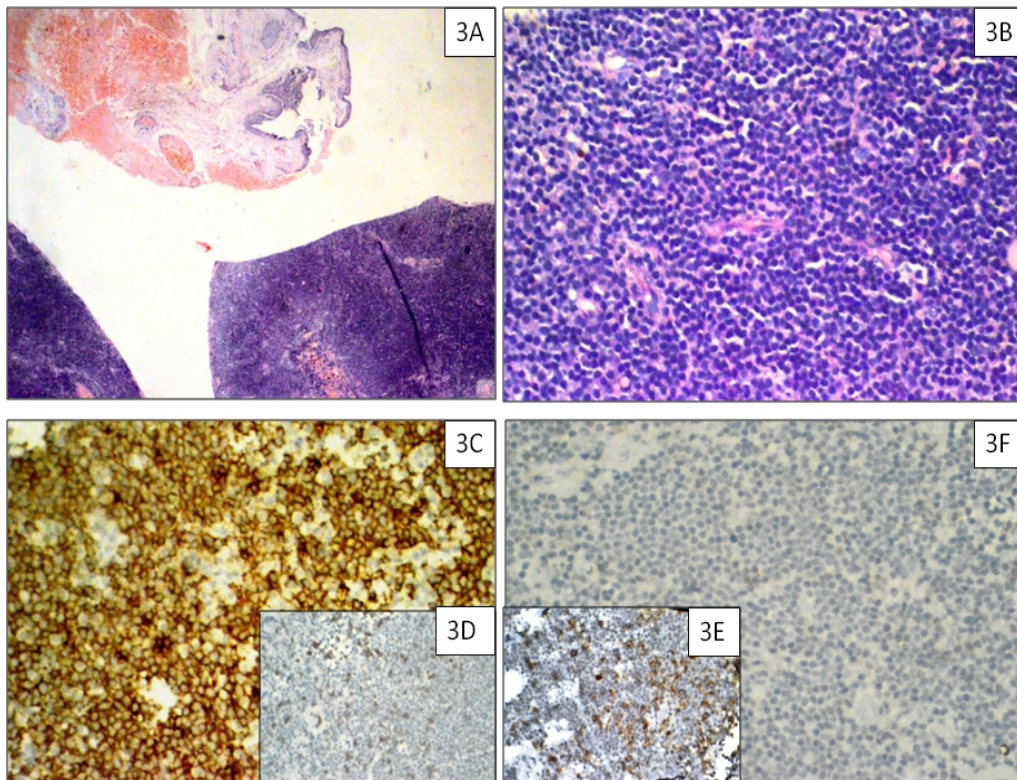
#### 3.1 Eye Pathology Workup and Its Photography

Orbital lymphomas and metastasis to the orbit typically present with proptosis or a palpable mass causing eyelid swelling [12,13]. Other symptoms include restricted extra-ocular movement, diplopia, and pain. The patient in this report had proptosis and lid edema. Decrease in visual acuity is uncommon unless there is optic nerve infiltration or compression caused by the mass [14]. Our patient had decreased vision due to cataract in the eye. One fourth of patients who present with orbital metastases do not have prior history of cancer [14]. So in this patient provisionally a diagnosis of metastasis to the orbit was considered.



Hence a systemic examination was done to rule out any metastasis infiltrating the orbit with specific attention to lung and gastrointestinal malignancies as these malignancies are common causes of orbital metastasis in males [15].

Systemic examination performed for staging of the lymphoma revealed a gastric mass. Biopsy from both sites confirmed that patient had two unrelated primary neoplasms. Careful review of literature shows that synchronous manifestations of two malignancies are uncommon. We did not find any report of unrelated second malignancy in a patient with unilateral proptosis.



**Fig. 3. 3A – Section shows fragments of conjunctival mucosa with dense infiltration by sheets of monomorphic small round lymphoid cells, x40, Hematoxylin and Eosin.**

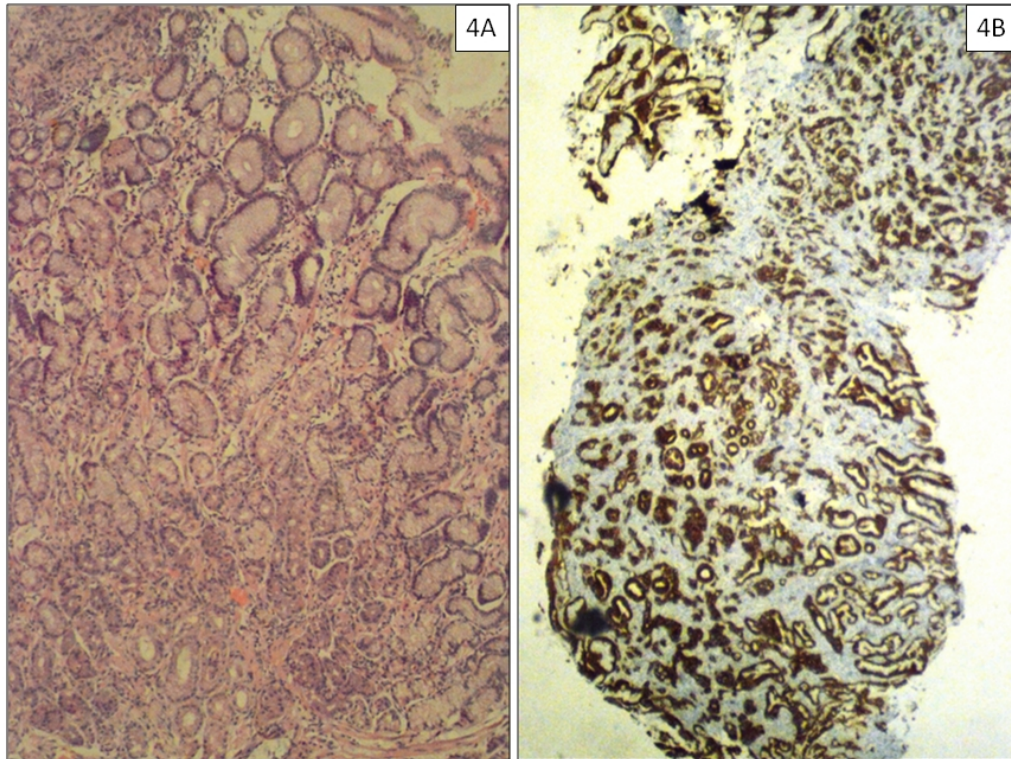
**3B – Section shows sheets of monomorphic small round lymphoid cells with inconspicuous cytoplasm and coarse nuclear chromatin, x400, Hematoxylin and Eosin.**

**3C– Section shows strong membranous positivity for CD 20 in lymphoid cells, x400, DAB stain (Immunohistochemistry with DAKO antibody, USA)**

**3D– Section shows occasional lymphoid cells expressing CD5, x400, DAB stain (Immunohistochemistry with DAKO antibody, USA)**

**3E– Section shows occasional lymphoid cells expressing CD23, x400, DAB stain (Immunohistochemistry with DAKO antibody, USA)**

**3F– Section shows negativity for CD3 in lymphoid cells, x400, DAB stain (Immunohistochemistry with DAKO antibody, USA)**



**Fig. 4. 4A – Section from gastric antral mucosa shows infiltration by tumor cells arranged in glandular pattern, x200, Hematoxylin and Eosin. 4B - Section from gastric antral mucosa shows infiltration by tumor cells arranged in glandular pattern, x40, DAB stain, (Immunohistochemistry with DAKO antibody, USA).**

#### **4. CONCLUSION**

The present case had lymphoma in the orbit and synchronous adenocarcinoma in the stomach. This highlights the importance of high index of clinical suspicion and thorough systemic examination in the evaluation of a case of unilateral proptosis in the elderly.

#### **CONSENT**

Informed consent taken.

#### **ETHICAL APPROVAL**

Ethical approval taken from the ethics committee of the institute.

#### **COMPETING INTERESTS**

The authors have declared that no competing interests exist.

## REFERENCES

1. Shields CL, Shields JA, Peggs M: Metastatic tumors to the orbit. *Ophthalmic Plast Reconstr Surg.* 1988;4:73.
2. Ferry AP, Font RL: Carcinoma metastatic to the eye and orbit Part I. A clinicopathologic study of 227 cases. *Arch Ophthalmol.* 1974;92:276.
3. Hart WM: Metastatic carcinoma to the eye and orbit. In: Zimmermann LE ed.: *Tumours of the eye and adnexa.* Int Ophthalmol Clin. 1962;2:465-482.
4. Henderson JW: *Orbital Tumors.* Philadelphia; WB Saunders. 1973;44-494.
5. Shields JA: *Diagnosis and management of orbital tumors.* Philadelphia: WB Saunders; 1989.
6. Font RL, Maturi RK, Small RG, Gracia-Rojas M: Hepatocellular carcinoma metastatic to the orbit. *Arch Ophthalmol.* 1998;116:942-5.
7. Norton AJ. Monoclonal antibodies in the diagnosis of lymphoproliferative diseases of the orbit and orbital adnexae. *Eye.* 2006;20:1186-8.
8. Cuadra-Garcia I, Proulx GM, Wu CL, et al.: Sinonasal lymphoma: a clinicopathologic analysis of 58 cases from the Massachusetts General Hospital. *Am J Surg Pathol.* 1999; 23:1356-69.
9. Imamura Y, Suzuki M, Nakajima KI, Murata H: gastric signet ring cell adenocarcinoma metastatic to the iris. *Am J Ophthalmol* 2001;131:379-81.
10. Sung JU, Lam BL, Curtin VT, Tse DT: Metastatic gastric carcinoma to the optic nerve. *Arch Ophthalmol.* 1998;116:692-3.
11. Liszauer AD, Wiens JJ, Brownstein S, Deschenes J: Gastric linitis plastica metastatic to the uvea. *Can J Ophthalmol.* 1991;26:325-7.
12. Gedik S, Gür S, Maral T, Akova YA, Demirhan B: Bilateral synchronous primary orbital lymphoma. *Adv Ther.* 2006;23:433-8.
13. Goldberg RA, Rootman J: Clinical characteristics of metastatic orbital tumors. *Ophthalmology.* 1990;97:620-4.
14. Beden U, Sonmez B, Kandemir B, Erkan D: Bilateral simultaneous primary orbital lymphoma presenting with unilateral enophthalmos. *Ophthal Plast Reconstr Surg.* 2008;24:145-7.
15. Shields CL, Shields JA, Gross NE, Schwartz GP, Lally SE: Survey of 520 eyes with choroidal metastases. *Ophthalmology.* 1997;104:1265-76.

© 2014 Ahuja et al.; This is an Open Access article distributed under the terms of the Creative Commons Attribution License (<http://creativecommons.org/licenses/by/3.0>), which permits unrestricted use, distribution, and reproduction in any medium, provided the original work is properly cited.

*Peer-review history:*

*The peer review history for this paper can be accessed here:*  
<http://www.sciencedomain.org/review-history.php?iid=369&id=23&aid=3343>