

Successful Percutaneous Retrieval of Embolised Septal Occluder Device and Device Closure of Atrial Septal Defect in Combined Procedure

**Gurkirat Singh^{1*}, Mahesh Bodkhe¹, Akshat Jain¹
and Narender Omprakash Bansal¹**

¹*Department of Cardiology, Grant Medical College and Sir J. J. Group of Hospitals, Mumbai, India.*

Authors' contributions

This work was carried out in collaboration among all authors. Author GS designed the manuscript, provided the clinical finding, the laboratory findings and images for the study and wrote the first draft of the study. Authors MB and AJ managed the literature searches. Author NOB revised the manuscript. All authors read and approved the final manuscript.

Article Information

DOI: 10.9734/CA/2019/v8i430115

Editor(s):

(1) Dr. Hani Nabeel Mufti, Assistant Professor, Department of Cardiac Surgery, College of Medicine-Jeddah, King Saud bin Abdulaziz University for Health Sciences, Saudi Arabia.

Reviewers:

(1) Francesca Gorini, National Research Council, Italy.
(2) Raymond N. Haddad, Hotel-Dieu de France University Medical Centre, Lebanon.
Complete Peer review History: <http://www.sdiarticle4.com/review-history/52435>

Case Study

Received 18 August 2019
Accepted 22 October 2019
Published 20 November 2019

ABSTRACT

Transcatheter device closure is the treatment of choice in patients with secundum atrial septal defects with adequate rims. It is technically safe, feasible and has the obvious advantage of being a nonsurgical technique. Patient is free from the scar especially young, unmarried females. It is not free of complications. Device embolization and arrhythmias are the major complications. Embolised device can cause hemodynamic compromise by obstructing the blood flow if it gets embolised in pulmonary artery. We report a case of 24 year old female, taken for device closure of atrial septal defect. Device gets embolised in pulmonary artery causing hemodynamic compromise by causing obstruction to blood flow. This embolised device was successfully retrieved percutaneously. The atrial septal defect was closed with one size larger device, in the same sitting. Patient is asymptomatic and is free from any scar.

*Corresponding author: E-mail: singhgs269@yahoo.com;

Keywords: Atrial septal defect; device closure; device embolization; percutaneous retrieval.

ABBREVIATIONS

ASD : Atrial Septal Defect;

IVC : Inferior Vena Cava;

CABG : Coronary Artery Bypass Graft Surgery.

1. INTRODUCTION

Atrial septal defects (ASD) constitute 8% to 10% of congenital heart defects in children. In the past, the incidence of ASDs has been estimated to be 56 per 100,000 live births [1]. With improvements in the imaging modalities and training of the practitioners the recent incidence is 1.6 per 1000 live births [2]. Secundum ASDs constitute approximately 75% of ASDs, followed by ostium primum ASD (20%) and sinus venosus ASD (5%) [3]. Although closure of secundum ASDs can be performed with percutaneous devices or surgically, surgical closure is the only option for sinus venosus, coronary sinus (CS), and primum ASDs. Transcatheter device closure of secundum ASDs with adequate rims is now the procedure of choice in the management of ASDs. Even in the patient with deficient aortic rim, device closure can be done. While device closure has proven to be technically safe and feasible and has the obvious advantage of being a nonsurgical technique, it is not free of

complications [4]. These complications include fracture or embolization of the device, device malalignment, residual shunts, device thrombosis and impingement of adjacent structures such as valves, superior vena cava, coronary sinus, pulmonary veins, or aorta [5,6].

2. CASE PRESENTATION

Twenty four year female, unmarried, admitted with breathlessness on exertion since 1 year. On examination, pulse was 88/min, blood pressure was 110/70 mmHg. On cardiac examination there was a wide and fixed second heart. Electrocardiogram showed right bundle branch block. Routine blood investigations were normal. Transthoracic echocardiography showed 20 mm ASD. Total septal length was 48 mm. Transesophageal echocardiography showed normal pulmonary venous drainage, ASD was 21.7 mm (maximum size in 0° four chamber view), with adequate rims (Fig. 1). Options were explained to the parents. Taken for percutaneous device closure of the ASD. Right femoral venous and arterial access was obtained. Pulmonary artery pressure was 30/16 (mean-22) mmHg. Qp/Qs was 2.1 and PVR was 3.4 Woods Units. The COCOON 26 mm device was selected for closure as the interatrial ASD rim was flimsy.

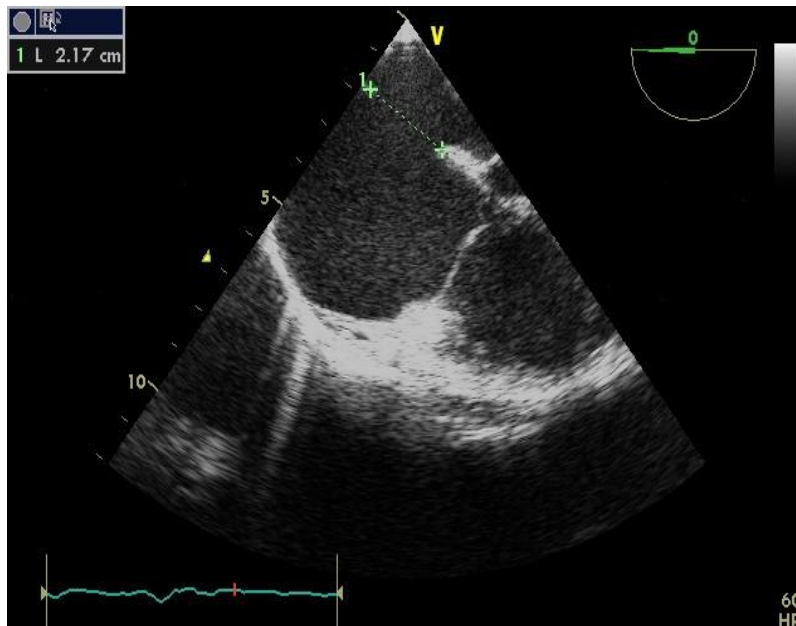


Fig. 1. TEE showing OS ASD of 21.7 mm

When we were checking the position of the device under TEE (Fig. 2), somehow it got detached from the cable and embolised into pulmonary artery (Fig. 3). Patient developed hypotension. Cardiac surgeon was notified but CABG was going on in their operation theater.

Hence we decided to retrieve the device as she was developing hypotension. Through the sheath 25 mm Gooseneck snare was inserted and the device was snared, but part of RA disc was not coming inside the sheath (Fig. 4A).

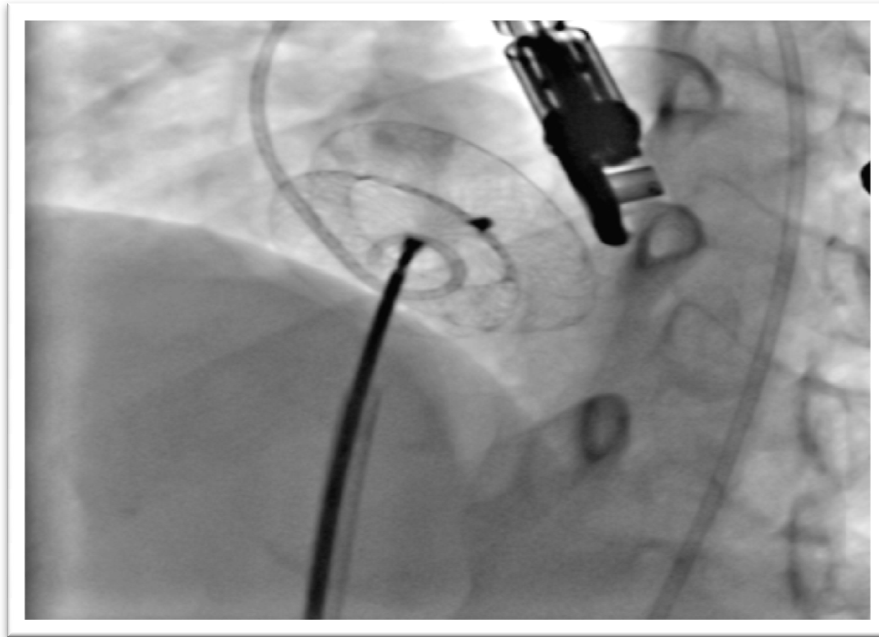


Fig. 2. Position of ASD device just before embolization

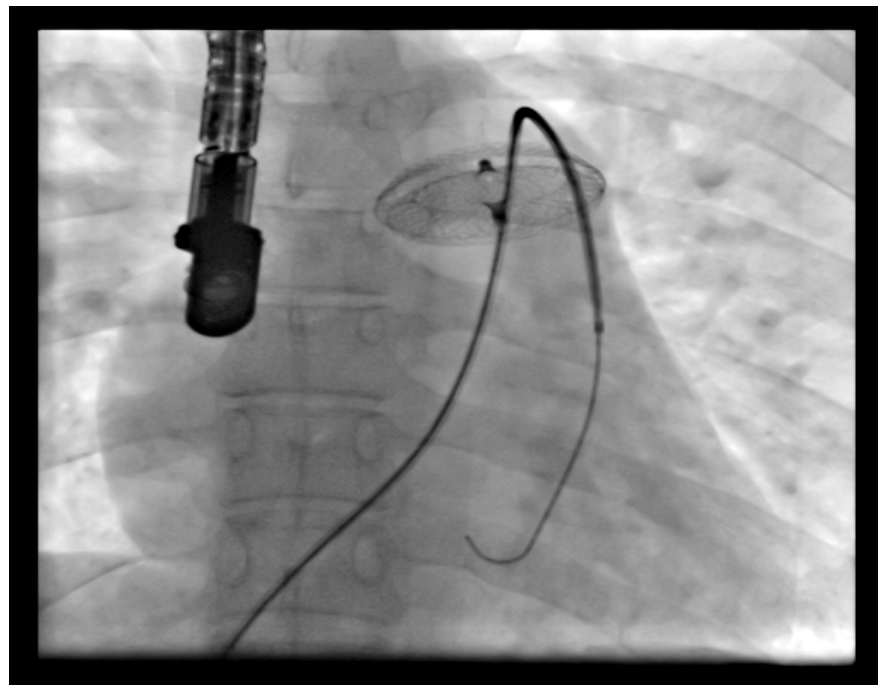


Fig. 3. Embolised ASD device in pulmonary artery

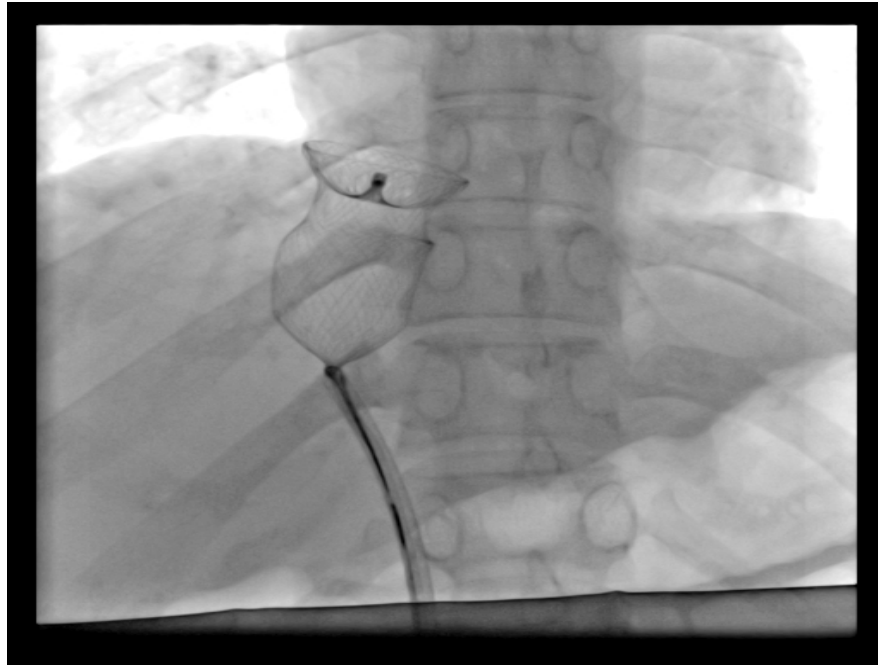


Fig. 4A. Snared ASD device

Through left femoral vein puncture, 14F sheath was inserted and the devices was snared (Fig. 5A, 5B). Then the ASD was successfully closed with COCOON 30 mm device under TEE guidance as a routine procedure (Fig. 6A, 6B). The patient was observed in intensive care unit

for 24 hours, echocardiography showed device in situ with no flow across ASD (Fig. 7A, 7B). There was no tricuspid regurgitation, tricuspid valve was normal. The patient was discharged on the 3rd day. Patient is asymptomatic on subsequent follow ups.

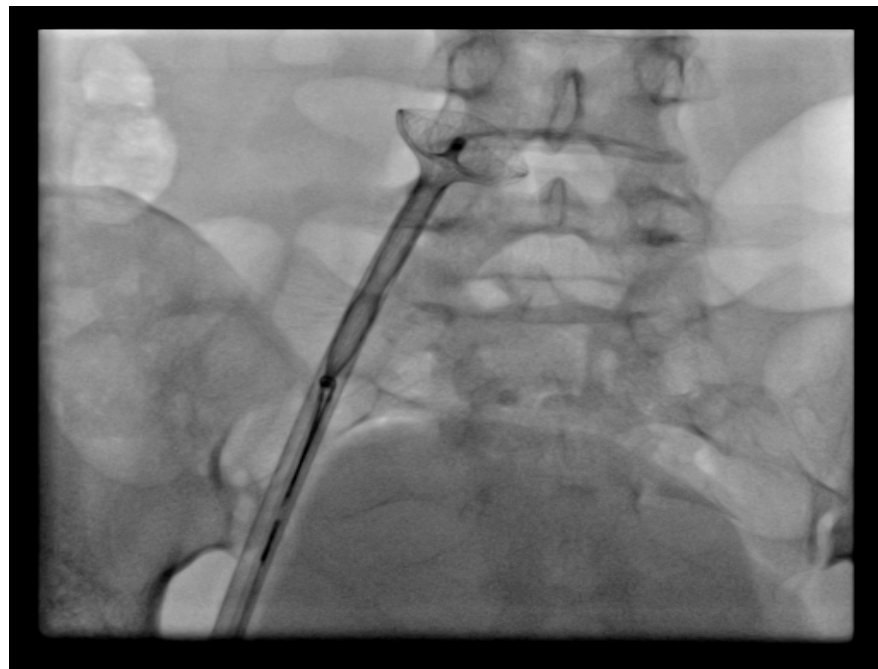


Fig. 4B. Snared ASD device brought up to the level of iliac vein

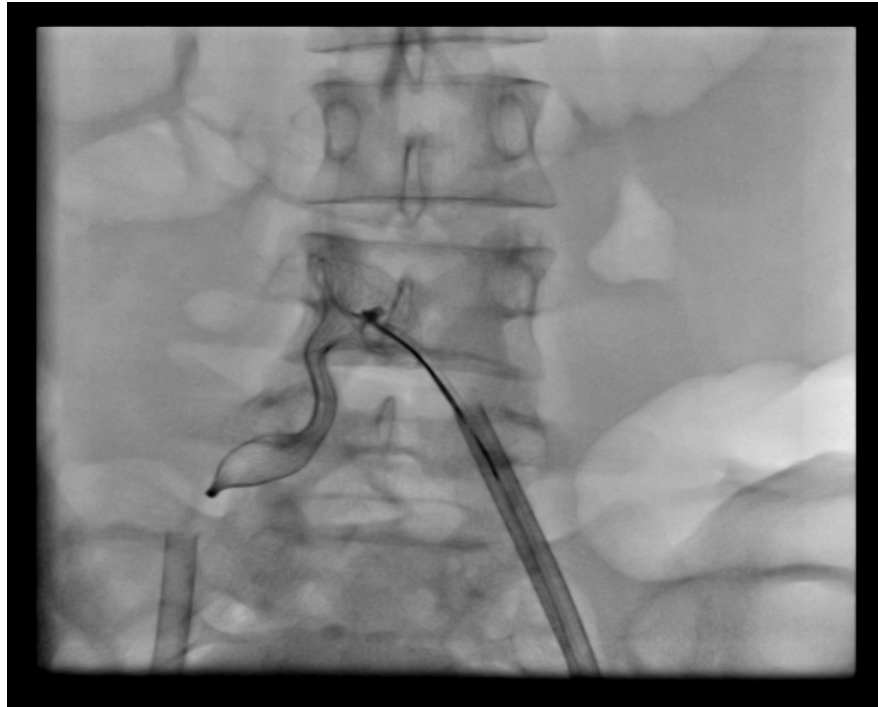


Fig. 5A. ASD device being snared into the sheath inserted through the left femoral vein

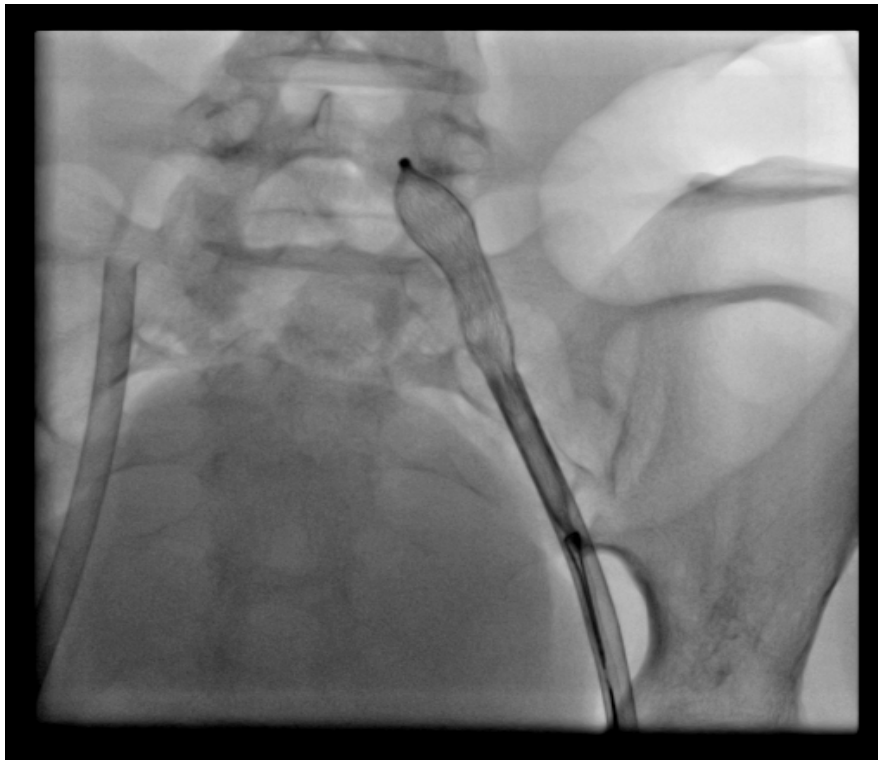


Fig. 5B. Snared ASD device brought into the 14F sheath inserted through the left femoral vein

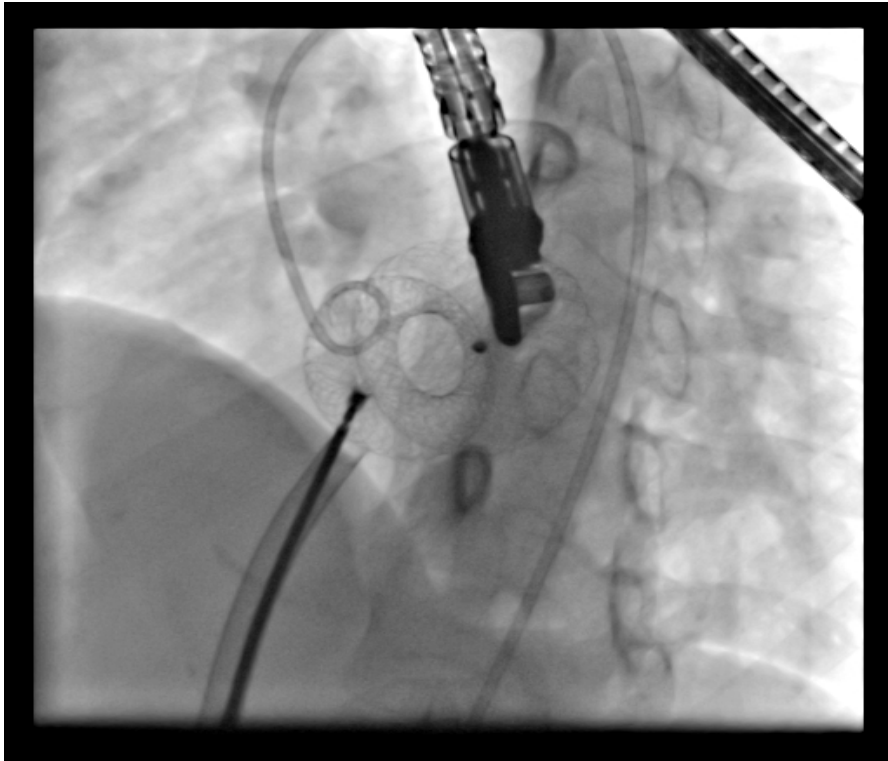


Fig. 6A. ASD device closure being done under TEE guidance

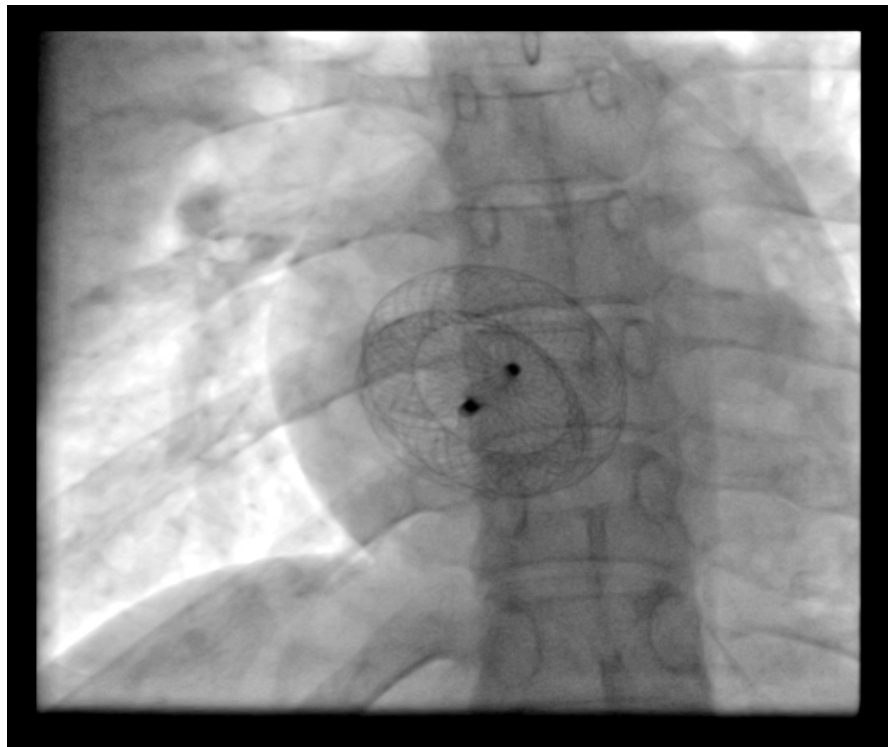


Fig. 6B. ASD device *in situ* seen in PA view

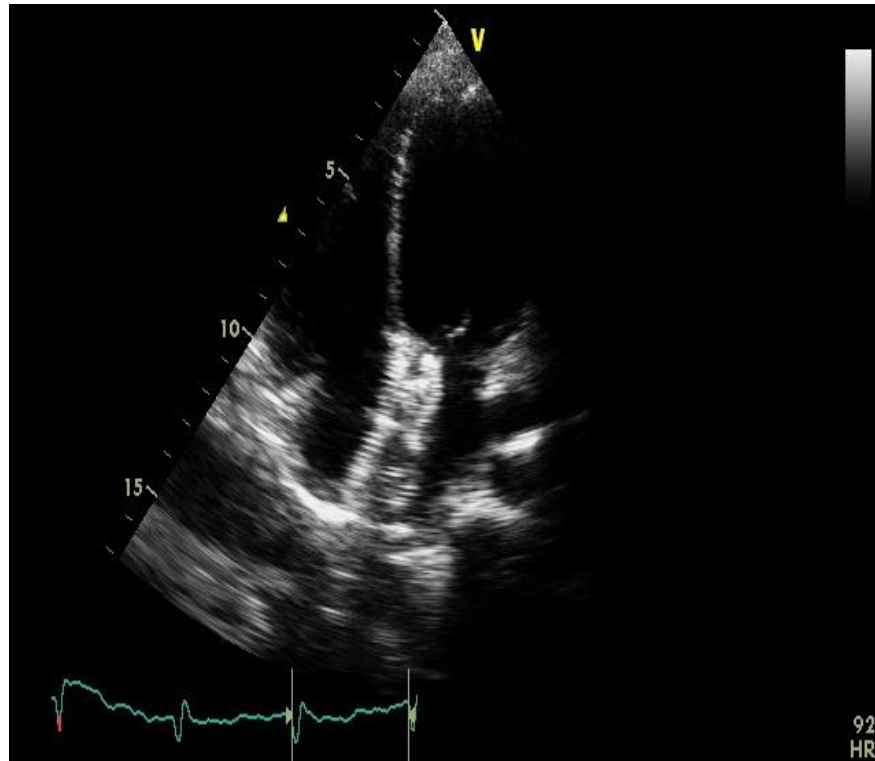


Fig. 7A. ASD device seen in apical 4 chamber view

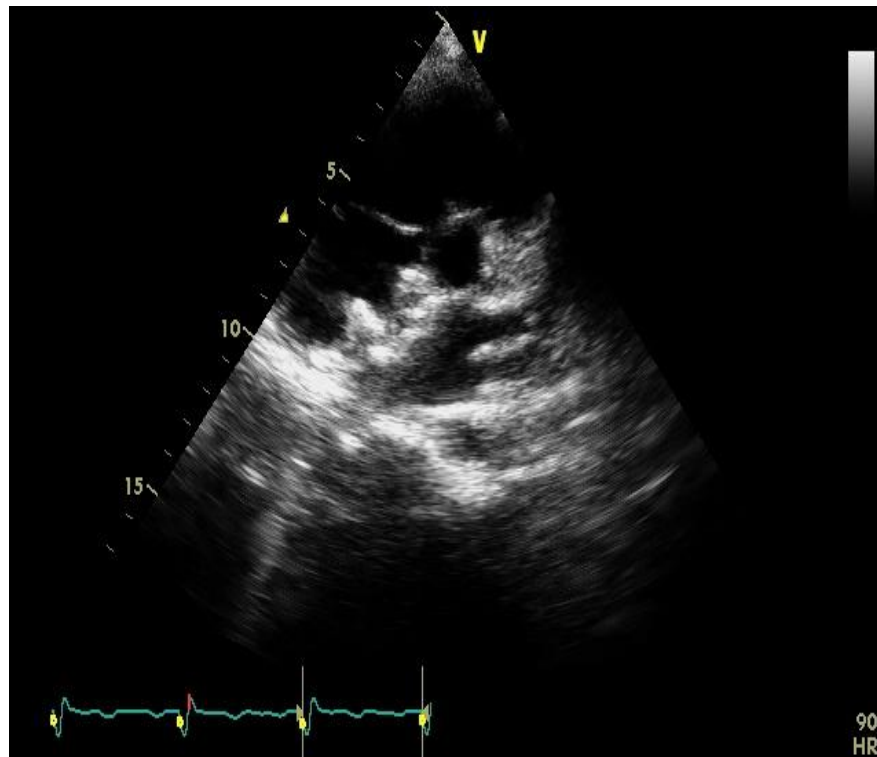


Fig. 7B. ASD device seen in parasternal short axis view

3. DISCUSSION

Major complications after device closure of ASDs are rare. Major adverse cardiac event rate of 1.6% (7 out of 442 patients) was described in Amplatzer pivotal trial. Device embolization and arrhythmias were the major complications. In the study of Amplatzer medical proctors by Levi and Moore, embolization rate of was 0.55% (21 out of 3824 device implants) [7]. In the study by DiBardino and coworkers, using data from the FDA's Manufacturer and User Facility Device Experience (MAUDE) database, estimated embolization rate was 0.62% [8]. In the Helix device pivotal study the rate of embolization requiring catheter retrieval was 1.7% [9] Device embolization can occur to the right heart, the pulmonary artery, the left heart, or the aorta. Most device embolizations occur at the time of or shortly after implantation, although late embolization has been reported. Embolised device can cause hemodynamic compromise, like in our patient when the device is embolised in pulmonary artery thus obstructing the blood flow.

Embolised device can be retrieved percutaneously or surgically. Percutaneous device retrieval is possible in a significant number of patients. First the device should be stabilized with a biopptome or a snare to prevent it from causing hemodynamic compromise. It require a second venous line from either jugular of left femoral vein, one site of access is used to hold the device, and the second is used to snare and subsequently retrieve the device. The right atrial microscrew can then be snared using a gooseneck snare delivered through a 6-Fr cut pigtail catheter or other angled guiding catheter delivered through the retrieval sheath. After the microscrew is snared, the device is pulled back into the sheath. After the microscrew enters the sheath, the entire device may be withdrawn. This method is used when the device is snared by the right atrial disc microscrew [10-14]. Sometimes the device is snared through the left atrial disc microscrew. In these cases it is very difficult to collapse the device into the large sheath. In these cases, another left femoral access is obtained and the device is snared through the right atrial disc microscrew into the larger femoral sheath, as the device is easy to collapse by holding the right atrial disc microscrew, as shown in our case. In another technique, described by Her et al, the waist of the device was captured by a looped 0.014-inch guide wire to stabilize the device. This method is called as "waist capture

technique" [15]. If the device cannot be percutaneously removed, surgical removal is necessary.

4. CONCLUSION

Embolization of ASD device is a rare complication. Inappropriate sizing, flimsy rims and the technical problems are the main causes of embolization. Embolised device can be retrieved percutaneously successfully as shown in our case. Interventional cardiologists need to be familiar with retrieval techniques.

CONSENT

Written informed consent was obtained from the patient for publication of this report and any accompanying images.

ETHICAL APPROVAL

It is not applicable.

COMPETING INTERESTS

Authors have declared that no competing interests exist.

REFERENCES

1. Hoffman JI, Kaplan S. The incidence of congenital heart disease. *J Am Coll Cardiol.* 2002;39:1890–1900.
2. Chelu RG, Horowitz M, Sucha D, Kardys I, Ingremeau D, Vasanawala S, Nieman K, Paul JF, Hsiao A. Evaluation of atrial septal defects with 4D flow MRI-multilevel and inter-reader reproducibility for quantification of shunt severity. *MAGMA.* 2019;32(2):269-279.
3. Kirklin JW, Barratt-Boyes BG. *Cardiac Surgery.* New York, NY: John Wiley & Sons; 1986.
4. Moore J, Hegde S, El-Said H, et al. Transcatheter device closure of atrial septal defects: A safety review. *JACC Cardiovasc Interv.* 2013;6:433–442.
5. Chan KC, Godman MJ, Walsh K, Wilson N, Redington A, Gibbs JL. Transcatheter closure of atrial septal defect and interatrial communications with a new self expanding nitinol double disc device (Amplatzer septal occluder): multicentre UK experience. *Heart.* 1999;82:300–306.
6. Prieto LR, Foreman CK, Cheatham JP, Latson LA. Intermediate-term outcome of

- transcatheter secundum atrial septal defect closure using the Bard Clamshell Septal Umbrella. *Am J Cardiol.* 1996;78:1310–1312.
7. Levi DS, Moore JW. Embolization and retrieval of the Amplatzer Septal Occluder. *Catheter Cardiovasc Interv.* 2004;61:543–547.
 8. Dibardino SJ, McElhinney DB, Kaza AK, et al. Analysis of the US food and drug administration manufacturer and user facility device experience database for adverse events involving Amplatzer Septal Occluder devices and comparison with the society of thoracic surgery congenital cardiac surgery database. *J Thorac Cardiovasc Surg.* 2009;137:1334–1339.
 9. Jones TK, Latson LA. Multicenter Pivotal Study of the HELEX Septal Occluder Investigators, et al. Results of the US multicenter pivotal study of the HELEX septal occluder for percutaneous closure of secundum atrial septal defects. *J Am Coll Cardiol.* 2007;49:2215-21.
 10. Balbi M, Pongiglione G, Bezante GP. Percutaneous rescue of left ventricular embolized Amplatzer septal occluder device. *Catheter Cardiovasc Interv.* 2008; 72(4):559-62.
 11. Shirodkar S, Patil S, Pinto R, Dalvi B. Successful retrieval of migrated Amplatzer septal occluder. *Ann Pediatr Cardiol.* 2010; 3(1):83-6.
 12. Chan KT, Cheng BC. Retrieval of an embolized Amplatzer septal occluder. *Catheter Cardiovasc Interv* 2010;75(3): 465-8.
 13. Peuster M, Boekenkamp R, Kaulitz R, Fink C, Hausdorf G. Transcatheter retrieval and repositioning of an Amplatzer device embolized into the left atrium. *Catheter Cardiovasc Interv.* 2000;51(3):297-300.
 14. Goel PK, Kapoor A, Batra A, Khanna R. Transcatheter retrieval of embolized AMPLATZER Septal Occluder. *Tex Heart Inst J.* 2012;39:653-6.
 15. Her AE, Lim KH, Shin ES. Transcatheter Retrieval of Embolized Atrial Septal Defect Occluder Device by Waist Capture Technique. *Int Heart J.* 2018;59:226-228.

© 2019 Singh et al.; This is an Open Access article distributed under the terms of the Creative Commons Attribution License (<http://creativecommons.org/licenses/by/4.0>), which permits unrestricted use, distribution, and reproduction in any medium, provided the original work is properly cited.

Peer-review history:

*The peer review history for this paper can be accessed here:
<http://www.sdiarticle4.com/review-history/52435>*