



Peripapillary and Macular Microvascular Density after Selective Laser Trabeculoplasty in Exfoliative Glaucoma: OCT-Angiography Study on 30 Cases

Meriem Elakhdari ^{a##}, Younes Akanour ^{a#}, Chaimae Bardi ^{a#},
Kamal Elmajdoubi ^{a#}, Louaye Serguni ^{a++}
and Amina Berraho ^{a++}

^a Hospital of Specialities, University Mohammed V Rabat, Morocco.

Authors' contributions

This work was carried out in collaboration among all authors. All authors read and approved the final manuscript.

Article Information

Open Peer Review History:

This journal follows the Advanced Open Peer Review policy. Identity of the Reviewers, Editor(s) and additional Reviewers, peer review comments, different versions of the manuscript, comments of the editors, etc are available here: <https://www.sdiarticle5.com/review-history/97181>

Original Research Article

Received: 30/12/2022

Accepted: 01/03/2023

Published: 06/03/2023

ABSTRACT

Exfoliative glaucoma is a particularly aggressive type of open-angle glaucoma, characterized by a faster rate of progression and poorer response to medical therapy [1].

Selective laser trabeculoplasty is a safe and noteworthy treatment option to reduce IOP exfoliative glaucoma eyes, especially with pre-SLT intraocular pressure (IOP) over 18 mmHg [2].

We present a prospective study on 30 eyes with exfoliative glaucoma with high intraocular pressure treated by Selective Laser Trabeculoplasty (SLT). Fifteen (15) patients were involved in the study and were followed up over a period of 6 months.

Interne in ophthalmology;

** *Professor in Ophthalmology;*

* *Corresponding author: E-mail: meriemelakhdari8@gmail.com;*

The peripapillary and macular microvascular density increased temporarily before returning to their initial values after 6 months. No correlation was found between microvascular fluctuations and IOP. The aim of this study is to evaluate the changes in the microvascular density (VD) of the peripapillary and the macular area using OCT angiography before and after the treatment by Selective Laser Trabeculoplasty.

Keywords: Exfoliative glaucoma; microvascular density; OCT angiography; selective laser trabeculoplasty.

ABREVIATIONS

OMAG : Optical Micro-Angiography
 SLT : Selective Laser Trabeculoplasty
 OCT : Optical Coherence Tomography
 IOP : Intraocular Pressure
 VD : Microvascular Density

1. INTRODUCTION

Pseudoexfoliation syndrome is a systemic disease with primarily ocular manifestations characterized by deposition of whitish-gray protein on the lens, iris, ciliary epithelium, corneal endothelium and trabecular meshwork. It is the most common cause of secondary glaucoma worldwide, and the most frequent cause of unilateral glaucoma [3,4].

Pseudoexfoliation glaucoma responds poorly to medical therapy compared to other types of glaucoma and can lead to rapid progression of optic nerve damage [5].

Selective laser trabeculoplasty is a safe and noteworthy treatment option to reduce IOP in exfoliative glaucoma eyes.

2. METHODS

This is a prospective study conducted between January and June 2021 at the Ibn Sina Department of Ophthalmology in Morocco on 30 eyes of 15 patients with exfoliative glaucoma treated with SLT.

Before and after SLT treatment, the following information was collected for each patient: age, gender, complete examination with visual acuity measurement, intraocular pressure measured by applanation tonometer, biomicroscopic examination, gonioscopy, pachymetry, and angio-OCT.

The OMAG algorithm (OpticalMicroAngiography) was used to analyze the microvascular density in the peripapillary and macular areas of patients over a 6-month period.

3. RESULTS

The study included fifteen patients, with a median age of 58.1 (35 to 84 years old), nine males and six females, for a male to female ratio of 1.5.

All patients had exfoliative glaucoma at different stages: early: 4 (27%), moderate: 8 (53%), advanced: 3 (20%) rebellious to medical treatment.

The average IOP before the SLT was 24.26 mmHg and the central corneal thickness was 530.04± 38.83 µm.

SLT was executed on 180° of trabecular surface in 26 eyes and 360° in 4 eyes. The SLT laser delivered 0.77 mJ of energy, which varied between 0.4 and 0.9 mJ.

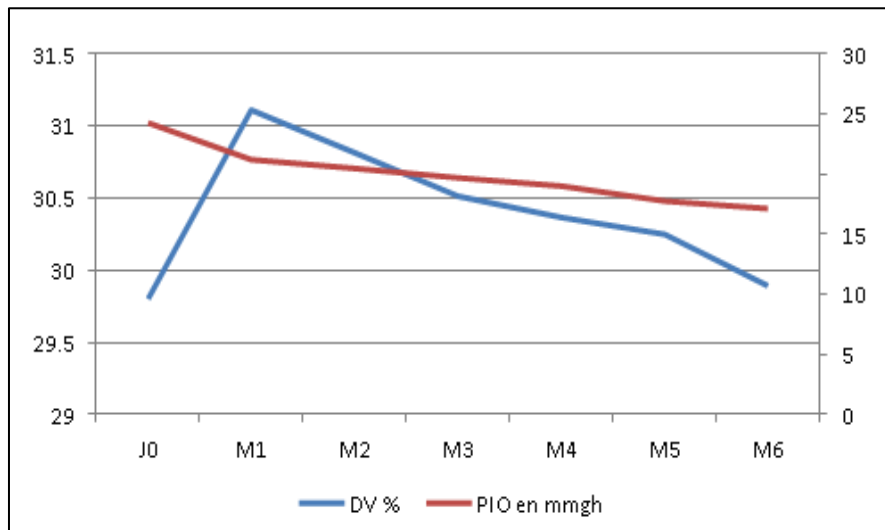
The SLT laser's efficiency was defined by a decrease in intraocular pressure of 20% or more.

Mean IOP decreased from 24.26 to 17.11 mmHg after 6 months post-SLT, we observe a decrease in intraocular pressure over six months post SLT (Table 1).

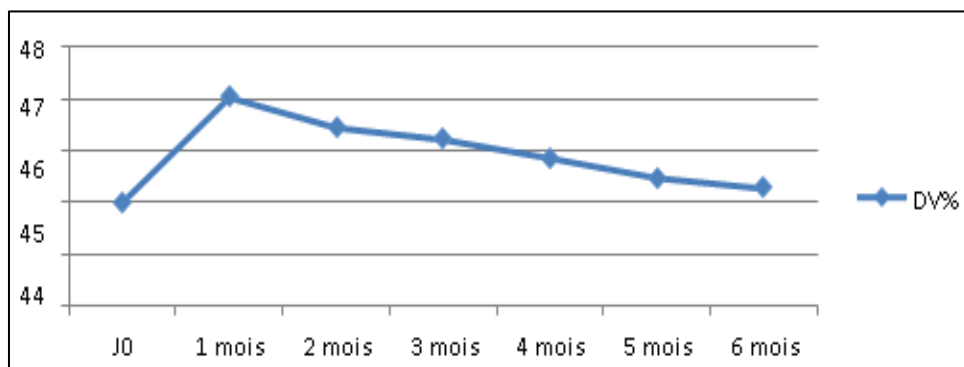
After one month post SLT microvascular density was increase of 4.4% (ranging from 29.8% to 31.11%) at the peripapillary area, and of 5% at the macular area (ranging from 45% to 47.25%) (Graphic 1 and 2).

Table 1. Evolution of IOP in mmHg

	J0	1month	2months	3months	4months	5months	6months
IOP inmmgh	24,26	21,19	20,47	19,68	18,97	17,72	17,11



Graphic 1. Variation in peripapillary microvascular density and the IOP



Graphic 2. Variation in macular microvascular density

After 6 months of SLT, this microvascular density was decrease of 0.3% at the peripapillary area and of 0.6% at the macular area, without correlation with IOP (Graphic 1 and 2).

4. DISCUSSION

During this study, we were able to evaluate the changes in the microvascular density in peripapillary and macular area before and after SLT, in patients with exfoliative glaucoma.

In our study, the efficacy of SLT was determined by a statistically significant reduction in IOP from the first month and proceeded for three and six months. After 1 month we have noticed an increase in microvascular density of peripapillary radial capillary plexus and macular regions (foveal, para and perifoveal) after SLT, related to a negative correlation with IOP. This increase was noticed in all stages of glaucoma but it was more important in patients with early glaucoma.

However, after 6 months post SLT all mean vascular densities returned to their initial levels.

This study had several limitations: first; the sample size was relatively small, second; the follow-up period was six months post SLT, which may be relatively short considering that exfoliative glaucoma is a progressive degenerative disease.

A study with a longer duration and larger population may confirm our findings.

5. CONCLUSION

The variation in retinal blood flow is a risk factor for glaucoma progression, in this study we determine the effect of reducing the intraocular pressure on peripapillary and macular vascularization in exfoliative glaucoma treated by SLT as a second line of therapy, by using OCT

Angiography, and we clarified the importance of early management of exfoliative glaucoma and reduce of IOP in regeneration of retinal microvascularization.

CONSENT

The patient has given their informed consent for the case report to be published.

ETHICAL APPROVAL

As per international standard or university standard written ethical approval has been collected and preserved by the author(s).

COMPETING INTERESTS

Authors have declared that no competing interests exist.

REFERENCES

1. Miglior S, Bertuzzi F. Exfoliative glaucoma: New evidence in the pathogenesis and treatment. Elsevier Volume. 2015;221:233-241.
Available :<https://doi.org/10.1016/bs.pbr.2015.06.007>
2. Ilveskoski L, Taipale C, Tuuminen R. Selective laser trabeculoplasty in exfoliative glaucoma eyes with prior argon laser trabeculoplasty Clinical Trial Acta Ophthalmol. 2020;98(1):58-64.
DOI: 10.1111/aos.14136.
Epub 2019 May 15.
PMID: 31091010
3. Schlötzer-Schrehardt U. Pseudoexfoliation syndrome and glaucoma. in Encyclopedia of the Eye; 2010.
4. Hutnik C, Crichton A, Ford B, Nicoleta M, Shuba L, Birt C, Sogbesan E, Damji K, Dorey M, Saheb H, Klar N, Guo H, Hodge W. Selective Laser Trabeculoplasty versus argon laser trabeculoplasty in glaucoma patients treated previously with 360° selective laser trabeculoplasty: A randomized, single-blind, equivalence clinical trial.
PMID: 30278197
DOI: 10.1016/j.ophtha.2018.09.037
5. Kent S, Hutnik C, Birt C, Damji K, Harasymowycz P, Francie Si, Hodge W, Pan I, Crichton A. A randomized clinical trial of selective laser trabeculoplasty versus argon laser trabeculoplasty in patients with pseudoexfoliation. 2015; 24(5):344-7. PMID: 23835670
DOI: 10.1097/IJG.0b013e31829e55e4

© 2023 Elakhdari et al.; This is an Open Access article distributed under the terms of the Creative Commons Attribution License (<http://creativecommons.org/licenses/by/4.0>), which permits unrestricted use, distribution, and reproduction in any medium, provided the original work is properly cited.

Peer-review history:
The peer review history for this paper can be accessed here:
<https://www.sdiarticle5.com/review-history/97181>